



1957

The rabbit : an illustrated anatomical guide

Edwin Chin Jr.
University of the Pacific

Follow this and additional works at: https://scholarlycommons.pacific.edu/uop_etds

Recommended Citation

Chin, Edwin Jr.. (1957). *The rabbit : an illustrated anatomical guide*. University of the Pacific, Thesis.
https://scholarlycommons.pacific.edu/uop_etds/1366

This Thesis is brought to you for free and open access by the Graduate School at Scholarly Commons. It has been accepted for inclusion in University of the Pacific Theses and Dissertations by an authorized administrator of Scholarly Commons. For more information, please contact mgebney@pacific.edu.

College of the Pacific

Stockton, California

THE RABBIT
AN ILLUSTRATED ANATOMICAL GUIDE ²

A Thesis
Presented to
the Faculty of the Department of Zoology
College of the Pacific

In Partial Fulfillment
of the Requirements for the Degree
Master of Arts

by
Edwin Chin, Jr.
June 1957

TABLE OF CONTENTS

CHAPTER	PAGE
I. INTRODUCTION	1
Preparation of Materials	3
Killing the specimen	3
Embalming the specimen	3
Injection of the circulatory system	6
Skeletal preparation	7
II. EXTERNAL FEATURES	8
III. SKELETAL SYSTEM	10
IV. MUSCULAR SYSTEM	45
Superficial Muscles	45
Subcutaneous Muscles	45
Muscles of the Neck and Back	45
Muscles of the Throat and Chest	51
Muscles of the Arm and Shoulder	52
Muscles of the Forearm	57
Muscles of the Thigh and Leg	60
Muscles of the Lower Leg	66
V. INTERNAL ORGANS	68
VI. RESPIRATORY SYSTEM	70
VII. HEART AND MAJOR VESSELS	73
The Heart	73
The Major Vessels	75

CHAPTER	PAGE
VIII. ARTERIAL CIRCULATION	80
Anterior Arteries	80
Thoracic Arteries	82
Abdominal Arteries	82
Major Lymphatic Vessels	85
IX. VENOUS CIRCULATION	87
Anterior Veins	87
Posterior Veins	88
X. HEPATIC-PORTAL CIRCULATION	91
XI. DIGESTIVE SYSTEM	93
XII. UROGENITAL SYSTEM	100
Urinary Organs	100
Male Reproductive Organs	101
Female Reproductive Organs	103
XIII. CENTRAL NERVOUS SYSTEM	105
Meninges	105
Lateral Aspect of the Brain	105
Median Sagittal Section of the Brain	107
Dorsal Aspect of the Brain	110
Ventral Aspect of the Brain	112
Spinal Cord	114
XIV. BIBLIOGRAPHY	116

LIST OF FIGURES

FIGURE	PAGE
1. Lateral View of a Mounted Skeleton	11
2. Lateral View of the Skull	13
3. Medial View of a Sagittal Section of the Skull . .	14
4. Dorsal View of the Skull	15
5. Ventral View of the Skull	16
6. Lateral View of the Mandible	19
7. Medial View of the Mandible	20
8. Anterior View of the Sternal Apparatus	22
9. Medial View of the Scapula	23
10. Lateral View of the Scapula	24
11. Anterior and Posterior Views of the Humerus . . .	26
12. Antero-lateral View of the Radius and Ulna	27
13. Dorsal View of the Bones of the Hand	29
14. Inferior View of the Atlas (1st Cervical)	31
15. Lateral View of the Axis (2nd Cervical)	31
16. Superior View of a Typical Cervical Vertebra . . .	33
17. Lateral View of a Typical Thoracic Vertebra . . .	33
18. Lateral View of a Typical Lumbar Vertebra	34
19. Superior View of a Typical Lumbar Vertebra	34
20. Ventral View of the Sacrum	36
21. Dorsal View of the Sacrum	36
22. Lateral Surface of the Innominate	38
23. Medial Surface of the Innominate	39

FIGURE	PAGE
24. Anterior and Posterior View of the Femur	41
25. Anterior View of the Tibio-Fibula	43
26. Dorsal View of the Bones of the Foot	44
27. Lateral View of the Superficial Muscles	46
28. Muscles of the Neck and Back	47
29. Muscles of the Throat and Chest	50
30. Lateral View of the Muscles of the Arm and Shoulder	54
31. Medial View of the Muscles of the Arm and Shoulder	55
32. Cross Section Through the Middle of the Humerus .	56
33. Dorsal View of the Tendons of the Forearm	59
34. Lateral View of the Superficial Muscles of the Thigh and Leg	62
35. Lateral View of the Deep Muscles of the Thigh and Leg	63
36. Medial View of the Muscles of the Thigh	64
37. Cross Section Through the Middle of the Femur . .	65
38. Cross Section Through the Middle of the Tibio-Fibula	67
39. Anterior View of the Internal Organs	69
40. Anterior View of the Thoracic Organs	72
41. Anterior View of the Heart	77
42. Dorsal View of the Heart	78
43. Vessels of the Neck and Thorax	79

FIGURE	PAGE
44. Branches of the Aorta	86
45. Tributaries of the Venae Cavae	90
46. Semi-Diagramatic View of the Hepatic-Portal System	92
47. Anterior View of the Liver	98
48. Semi-Diagramatic View of the Ileocecal Junction . .	99
49. The Male Urogenital System	102
50. The Female Urogenital System	104
51. Lateral View of the Brain	106
52. Medial View of a Sagittal Section of the Brain . .	109
53. Dorsal View of the Brain	111
54. Ventral View of the Brain	115

I. INTRODUCTION

While assisting in a laboratory course in mammalian anatomy at the College of the Pacific in the fall of 1955, it became necessary to utilize domestic rabbits, Lepus caniculus, as a replacement for cats as dissecting material. As a result of this, it was noted that anatomically the rabbit was in many ways more desirable as a dissecting mammal than the cat. Some notable advantages over the cat were (1) a more typical hyoid apparatus; (2) possession of twelve pairs of ribs; (3) persistent right azygos vein; (4) three main branches from the aortic arch; and external and internal iliac arteries arising from the common iliac artery. These advanced mammalian characteristics, as observed in the preliminary dissections, resembled so much the human anatomical condition that an investigation of the possible use of the rabbit for dissection in an introductory anatomy or mammalian anatomy course was initiated. An added advantage in the use of the rabbit for dissection would be the lack of personal attachment for laboratory animals such as the rabbit, whereas certain societies and groups of individuals often react negatively to the dissection of cats in the laboratory. The low cost and ease of embalming and injecting is an added inducement for the use of rabbits as dissecting material.

This study on the anatomy of the rabbit was based on dissected material from the biological laboratories of the College of the Pacific. Because of existing errors in many of the present references to rabbit anatomy, the guide was prepared to meet the expressed need for a concise, illustrated outline of basic anatomy of the rabbit which might be used by students in an introductory course in mammalian or human anatomy. Since it is assumed that the guide would be supplemented by a dissection manual, syllabus, or textbook, textural material of such an outline is here presented in outline form.

I wish to express my deep gratitude to Dr. Alden E. Noble, chairman of the Department of Zoology, College of the Pacific, whose inspiration and guidance has made this study possible. I would also like to thank Dr. Donald L. Lehmann of the College of the Pacific and Miss Edith Grider, reference librarian of the College of the Pacific, for their generous donation of time and advice in helping to make this study possible.

PREPARATION OF MATERIALS

Most of the larger biological supply houses supply embalmed rabbits; singly, doubly, or triply injected. The cost of these preserved rabbits is about the same as for the cat. The following procedures were used in the preparation of materials for this study, and they are recommended for those who wish to use the more readily obtainable live rabbits.

KILLING THE SPECIMEN

The animal should be starved a day or two prior to embalming. This allows for evacuation of the digestive tract. Also, the dissection will progress more easily, with a minimum of visceral and subcutaneous fat deposits. A large crock or garbage pail with a tightly fitting cover is ideal as a killing chamber. A cotton wad soaked with ether or chloroform is dropped into the chamber and allowed to remain for at least 20 minutes. The animal should be dead and ready for embalming.

EMBALMING THE SPECIMEN

While smaller mammals can be preserved by simply opening the body cavity and immersing them in a solution of formalin or alcohol, larger animals should be embalmed intravenously to insure adequate brain and visceral

preservation. The embalming solution should be prepared ahead of time and stored in a large 8-10 liter bottle with a two-hole rubber stopper. The following solution, which is a modification of Keiler's embalming fluid for the preparation of human cadavers in anatomical study, was found to be satisfactory for the rabbit.

Commercial Formalin	5 Parts
Melted Carbolie Acid Crystals . .	5 Parts
Glycerin	5 Parts
Distilled Water	85 Parts

The formalin acts as preservative and also gives firmness to the muscles. The glycerin prevents desiccation and hardening of the organs. The carbolie acid helps to retain color of the tissue and to improve the odor of the specimen.

The animal should be placed on an embalming board and tied into the desired position prior to hardening. The sites of injection for the embalming fluid are the common carotid and femoral arteries. The common carotid artery is located by a small incision in the neck region lateral to the trachea and anterior to the anterior border of the sternomastoid muscle. This artery lies in close relationship with the vagus nerve and internal jugular vein. The femoral artery is exposed by an incision on the medial surface of the thigh in the region of the femoral triangle. Palpation of this area will reveal the course of the femoral artery. Expose the arteries from the surrounding connective

tissue and slip a length of thread around them with a loose knot at the end. Cover the incisions with a cotton wad dampened with distilled water to prevent the area from drying out. The gravity bottle should be placed about three feet above the specimen containing the embalming fluid. The opening from the bottle should be equipped with a rubber tube and a glass T. The terminal ends of the rubber tubing from the glass T should be equipped with a glass cannula approximately the same diameter or slightly larger than the diameter of the arteries to be cannulated. The arteries are incised half-way through with a V-shaped cut pointing towards the heart. The glass cannula is carefully inserted into the artery and the cannula tied securely into place with Number 8 nylon thread. Tying the loose ends of the thread a few times around the leg or neck region will prevent accidental removal of the cannula during the embalming process. The flow of the fluid into the cannula can be controlled by two screw-type clamps on the rubber tubing. The embalming process should be completed in about two hours. An average-sized rabbit requires about $1\frac{1}{2}$ to 2 liters of fluid. The embalming process is complete when the animal appears completely bloated. The limbs and head should be immovable with the eyes bulging. If fluid is visible flowing from the nasal or oral passages, a cotton plug should be forced into the aperture to prevent loss of fluid.

A wetting solution should be prepared and kept on hand for use as the dissection progresses. The following formula is recommended.

Melted Carbolio Acid Crystals	30 grams
Glycerin	250 cc.
Distilled Water	1000 cc.

INJECTION OF THE CIRCULATORY SYSTEM

The identification and dissection of blood vessels can be made easier with the aid of colored injection mass. The following starch mass formula is an adequate preparation which is inexpensive. Latex injection materials, however, are preferable because they impart elasticity to the vessels.

Corn Starch	1 lb.
Formalin	100 cc.
Glycerin	100 cc.
Distilled Water	500 cc.
Colored Dye	
Carmine	Red
Berlin Blue	Blue
Lead Chromate	Yellow

The injection of the circulatory system should not be started immediately after embalming. Two days should be allowed for saturation by the embalming fluid in the body. The injection should be carried out with a large-sized injection syringe. The arterial injection (red) is made through the carotid and femoral arteries. Injection should be directed toward the heart with considerable pressure. Venous injection (blue) is made through the

external jugular vein in the neck and the femoral vein in the thigh. The hepatic-portal system (yellow) is injected through an intestinal branch of the hepatic-portal vein. An incision into the abdominal cavity will locate the intestinal veins within the abdominal mesentery.

SKELETAL PREPARATION

Freshly killed specimen are better suited for the preparation of skeletal structures than are embalmed ones. After removing as much of the soft flesh as possible, the skeletal elements can be boiled in the following solution.

Hard Soap	25 grams
Potassium Nitrate	12 grams
Strong Ammonia	150 cc.
Distilled Water	2000 cc.

One part of the above stock soap solution should be diluted with 3-4 parts water. Boiling should proceed, with frequent examination, until the remaining flesh falls off or becomes soft enough to scrape off easily. For a disarticulated skull, a young specimen is preferable because of the incomplete ossification of the sutures. Continual boiling in the solution will loosen the sutures sufficiently so that the bones may be easily separated.

II. EXTERNAL FEATURES

(No Figures)

GENERAL BODY SHAPE

Head, neck, thorax, abdomen, recurved tail,
anterior limbs, posterior limbs.

SKIN

Hair - Making up the furry coat.

Vibrissae - Enlarged tactile hair in the head region.

Mammary Nipples - 8-10 in number on the ventral surface
of the animal in two rows.

APPENDAGES

Anterior Extremity -

Arm, forearm, hand (with 5 digits), claws.

Posterior Extremity -

Thigh, lower leg, foot (with 4 digits), claws.

SENSORY ORGANS

External Nares - Paired openings anteriorly located
and close together on the nose.

Eyes - Prominent and antero-laterally located. Movable
upper and lower eyelids and third nictitating
membrane at medial corner of the eye.

Ears - Large external ears (pinna) at the base of which
is the external auditory meatus which leads to
the tympanic membrane.

OTHER APERTURES

Mouth - Anterior, bounded by fleshy lips. Upper lip divided and undivided lower lip.

Anus - External opening of digestive tract.

Urogenital openings -

Male - Urogenital opening at the tip of the penis.

Female - Urogenital opening into the vulva.

EXTERNAL GENITALIA

Male -

Penis - With urogenital opening at the tip of the glans penis.

Scrotum - Ventral and anterior to the anus.

Prepuce - Skin fold surrounding the glans penis.

Female -

Vulva - External urogenital sinus.

Clitoris - Female homologue of the male penis.

SKELETAL STRUCTURES

Head Region -

Angle of mandible, zygomatic arch, external occipital protuberance, hyoid bone.

Trunk Region -

Sternum with manubrium and xiphoid process.

Iliac crest.

Appendages -

Anterior extremity - Olecranon process.

Posterior extremity - Patella and calcaneus.

III. SKELETAL SYSTEM

ENTIRE SKELETON - (Fig. 1) The labels on figure one are repeated on the appropriate portions of figures of the disarticulated skeleton.

SKULL - (Figs. 2, 3, 4, 5)

Occipital Bone - Surrounding foramen magnum, opening through which the spinal cord passes.

Basioccipital - Basiventral portion of this bone.

Exoccipital - Paired lateral regions bearing the occipital condyles, elevations for the articulation with the first cervical vertebra (atlas).

Supraoccipital - Extends dorsally from foramen magnum. Note external occipital protuberance (posterior prominence).

Interparietal Bone - Unpaired. Median triangular-shaped bone anterior to supraoccipital.

Parietal - Large paired bones forming posterior portion of the cranial vault.

Frontal - Paired larger than parietals and anterior to them. Each extending ventrally into the orbit.

Nasal - Paired, broad and flattened bones. Anterior to the frontals.

Vomer - Single bone forming a portion of the nasal cavity and contributing to the nasal septum formation.

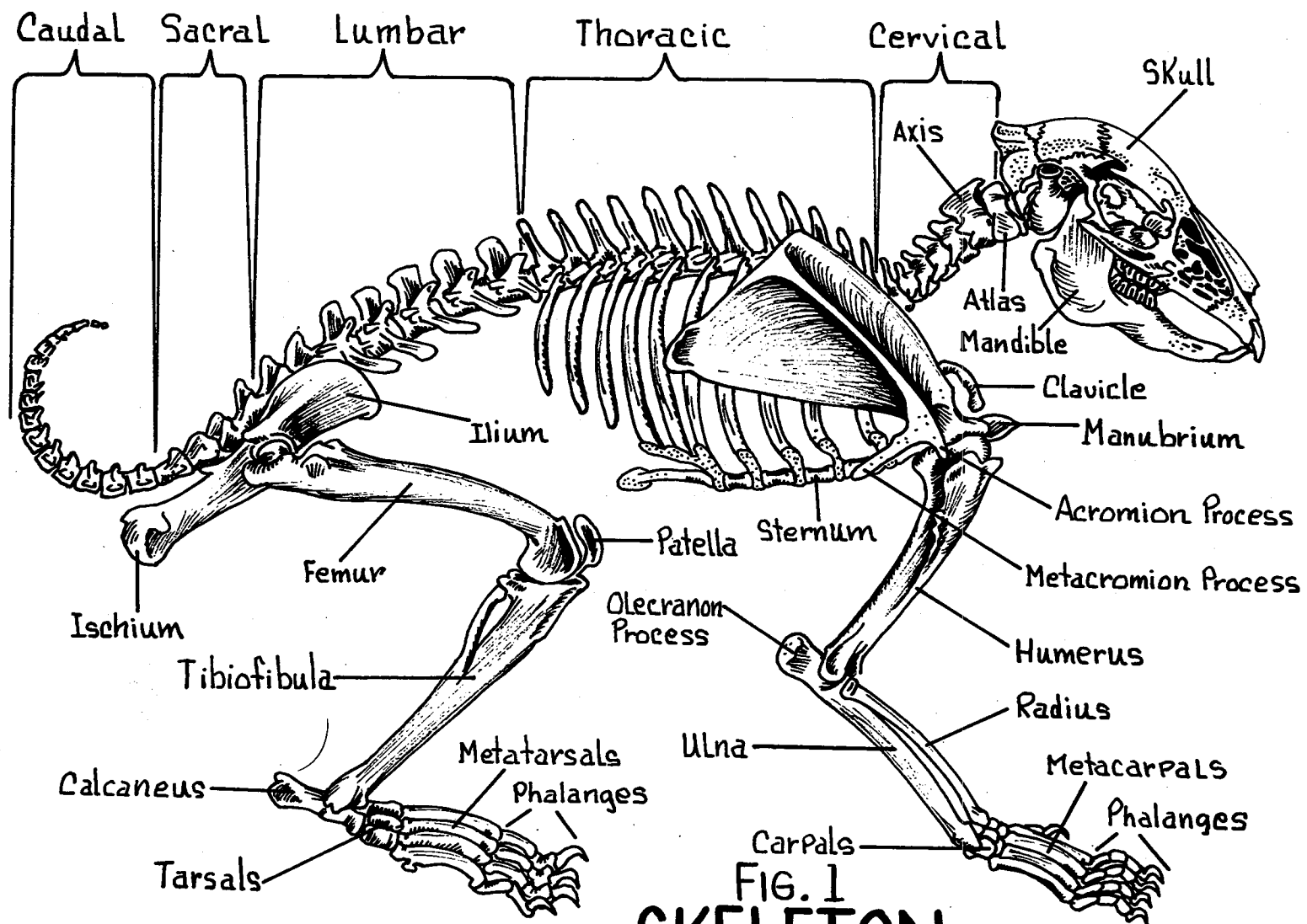


FIG. 1
SKELETON

Sphenoid Bone - Ventrally located.

Basisphenoid - Anterior and mediad to basioccipital.

Containing sella turcica on dorsal surface.

Presphenoid - Slender and anterior to basisphenoid.

Orbitosphenoid - Ventral portion of orbit, posterior to optic foramen.

Alisphenoid - Extends dorsally from basisphenoid.

Temporal Bone - Lateral large flattened bones.

Squamosal - Rectangular plate-like paired bones forming the lateral wall of the cranium. Bearing the posterior root of the zygomatic arch.

Petromastoid - Oblong, paired bones with ventrolateral swellings (tympanic bulla). Also containing the external auditory meatus and mastoid process.

Auditory Ossicles -

Malleus - Hammer.

Incus - Anvil.

Stapes - Stirrup.

Malar Bone - Forming the mid portion of the zygomatic arch.

Major Foramina of the Skull -

Optic Foramen - Oval-shaped within the orbit.

Transmits the optic nerve (II).

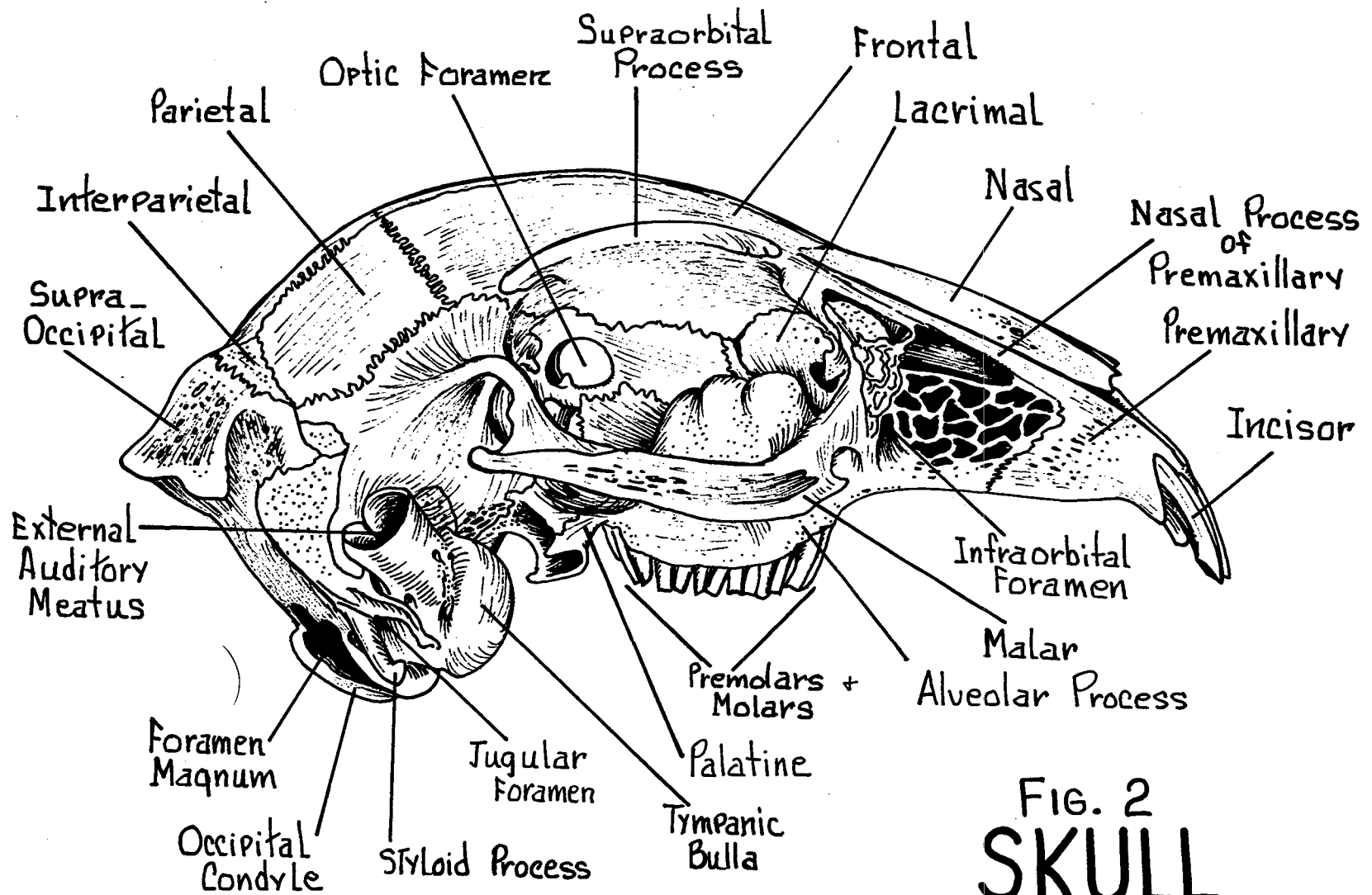


FIG. 2
SKULL
 Lateral View

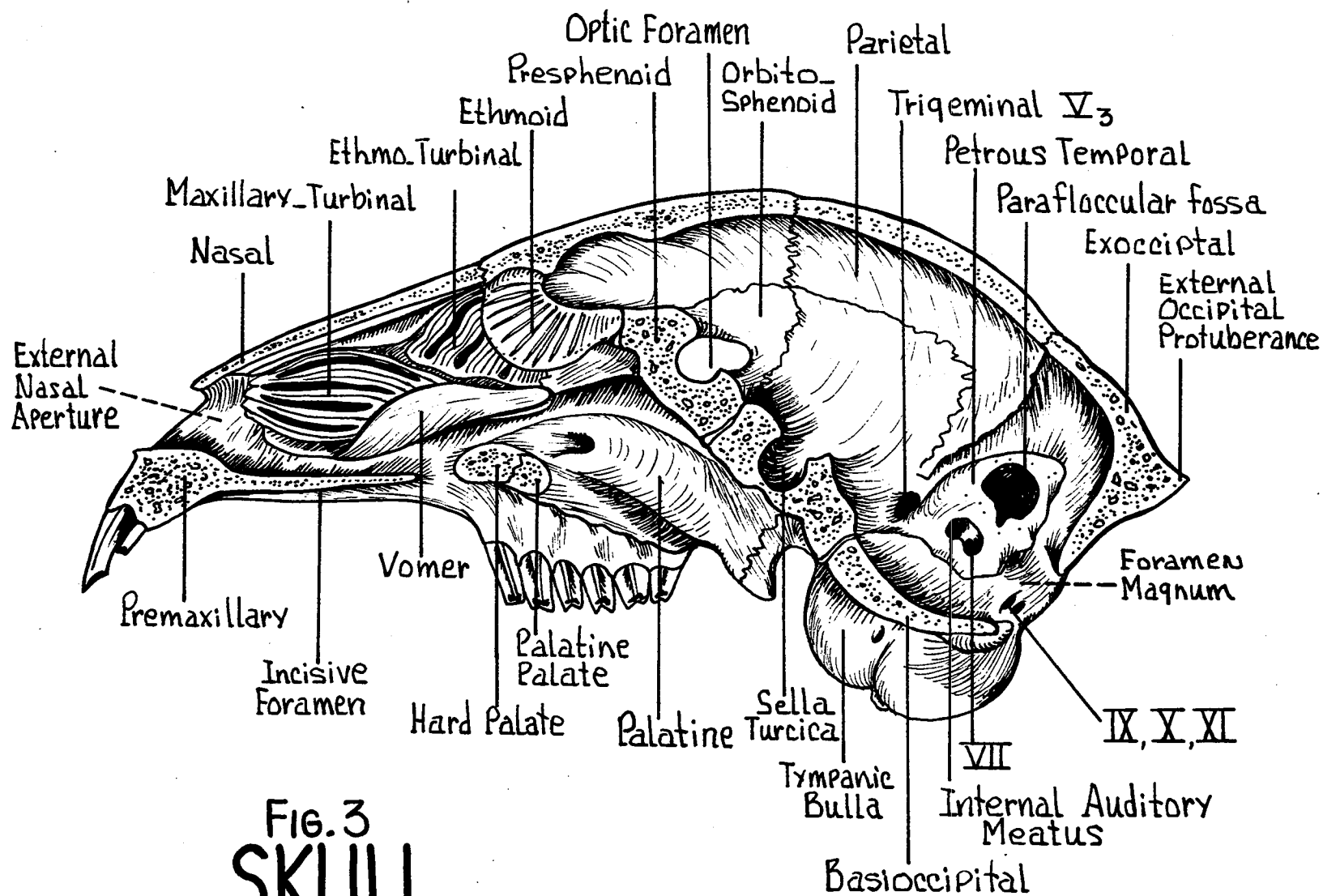


FIG. 3
SKULL
 Sagittal Section

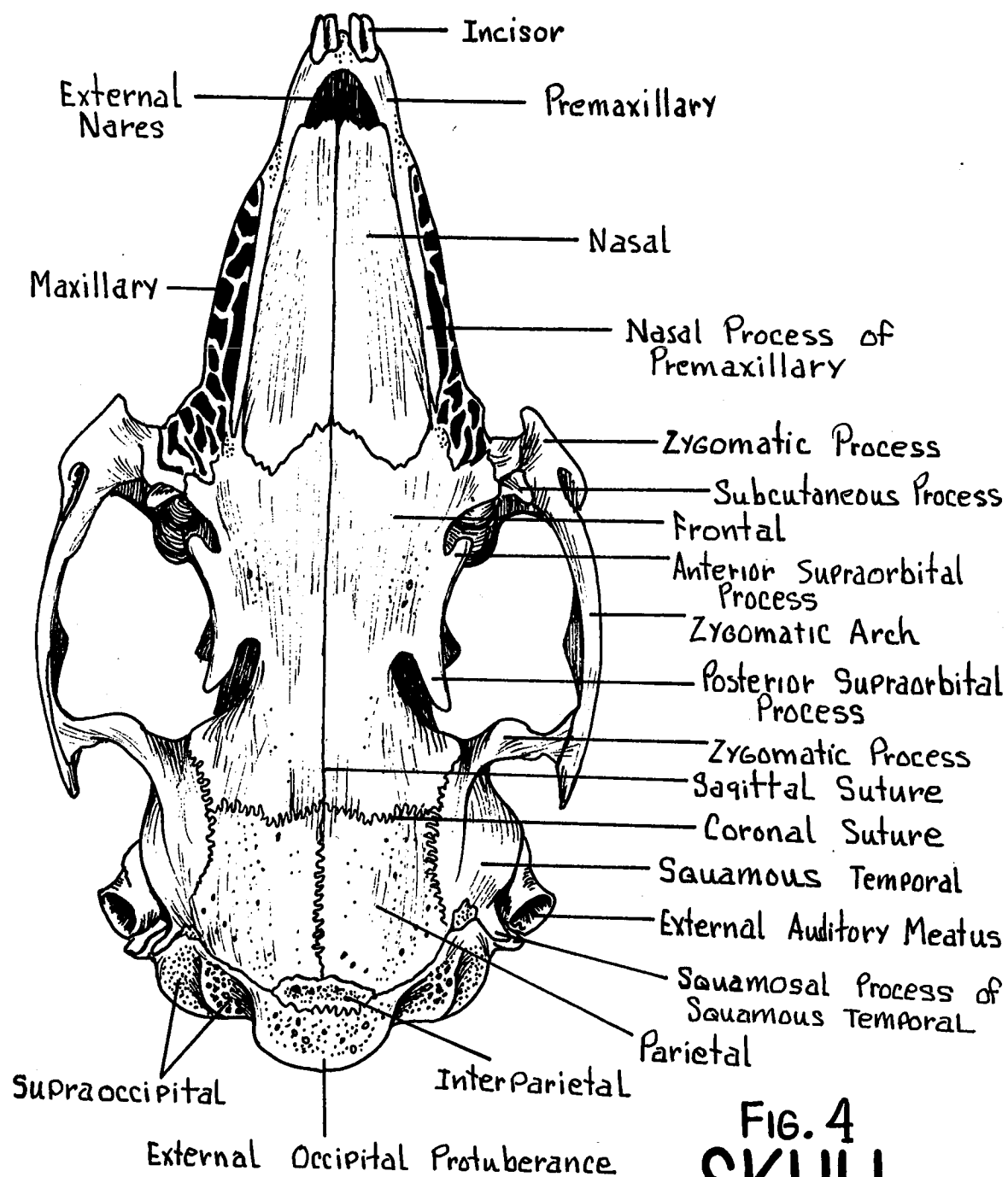


FIG. 4
SKULL
 Dorsal View

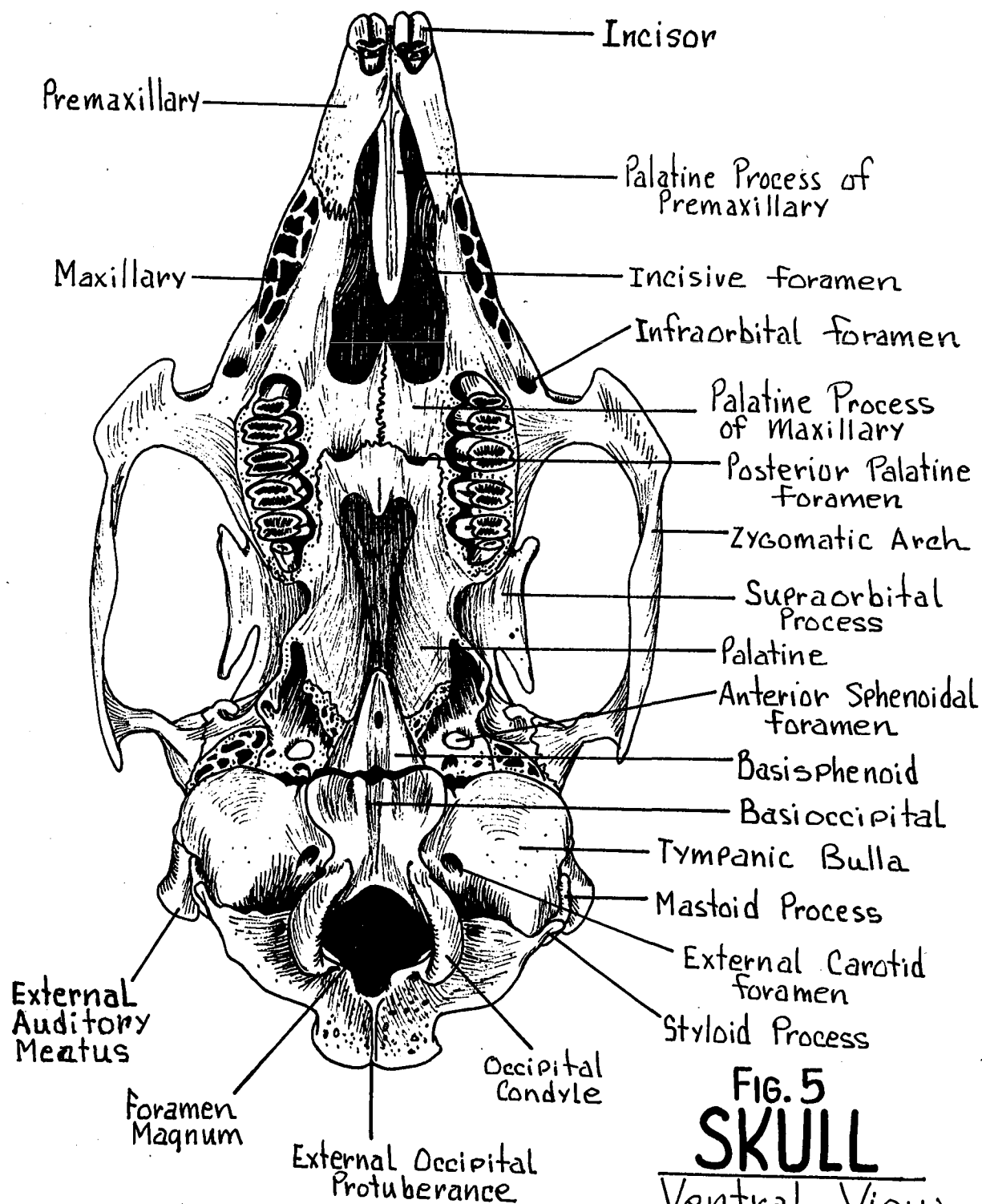


FIG. 5
SKULL
 Ventral View

Infraorbital Foramen - Within maxillary bone at zygomatic process.

Orbital Fissure - Vertical slit-like aperture within the orbit.

Foramen Rotundum - Posterior portion of orbital fissure. Permits passage of nerves III, IV, VI, and the 1st and 2nd divisions of V.

Foramen Ovale - Posterior to foramen rotundum. For the passage of the mandibular branch of trigeminal nerve (V).

Internal Carotid Foramen - For internal carotid artery.

Posterior Palatine Foramen - Anterior opening piercing hard palate.

Anterior Sphenoidal Foramen - For passage of internal maxillary artery.

Stylomastoid Foramen - For passage of facial nerve (VII).

Jugular Foramen - At the median posterior end of bulla. For the internal jugular vein.

MANDIBLE - (Figs. 6, 7) Consisting of two rami. Bears the lower teeth.

Mental Symphysis - Anterior union of right and left rami.

Condyle - Articular portion which articulates with the mandibular fossa of the temporal bone.

Coronoid Process - Anterior projection of the ascending ramus.

Angle of the Mandible - Posterior margin of ramus. Ventral to the supra-angular notch.

Mandibular Foramen - On medial surface of ramus immediately posterior to last molar tooth. Transmits nerves and vessels to the mandible.

Mental Foramina - One or more on lateral surface of each ramus at anterior end.

Alveolar Process - Bearing the two premolar and three molar teeth.

Diastema - Space between 1st premolar and the two large incisor teeth.

HYOID BONE - Stout wedge-shaped bone.

Body of Hyoid - Central broad portion from which the greater and lesser cornu project.

Greater Cornu - Large element extending dorsally from the body of the hyoid.

Lesser Cornu - Small element partly cartilaginous. Connected antero-dorsally to the body of the hyoid.

STERNUM - (Fig. 8) Linear arrangement of six segments (sternebrae).

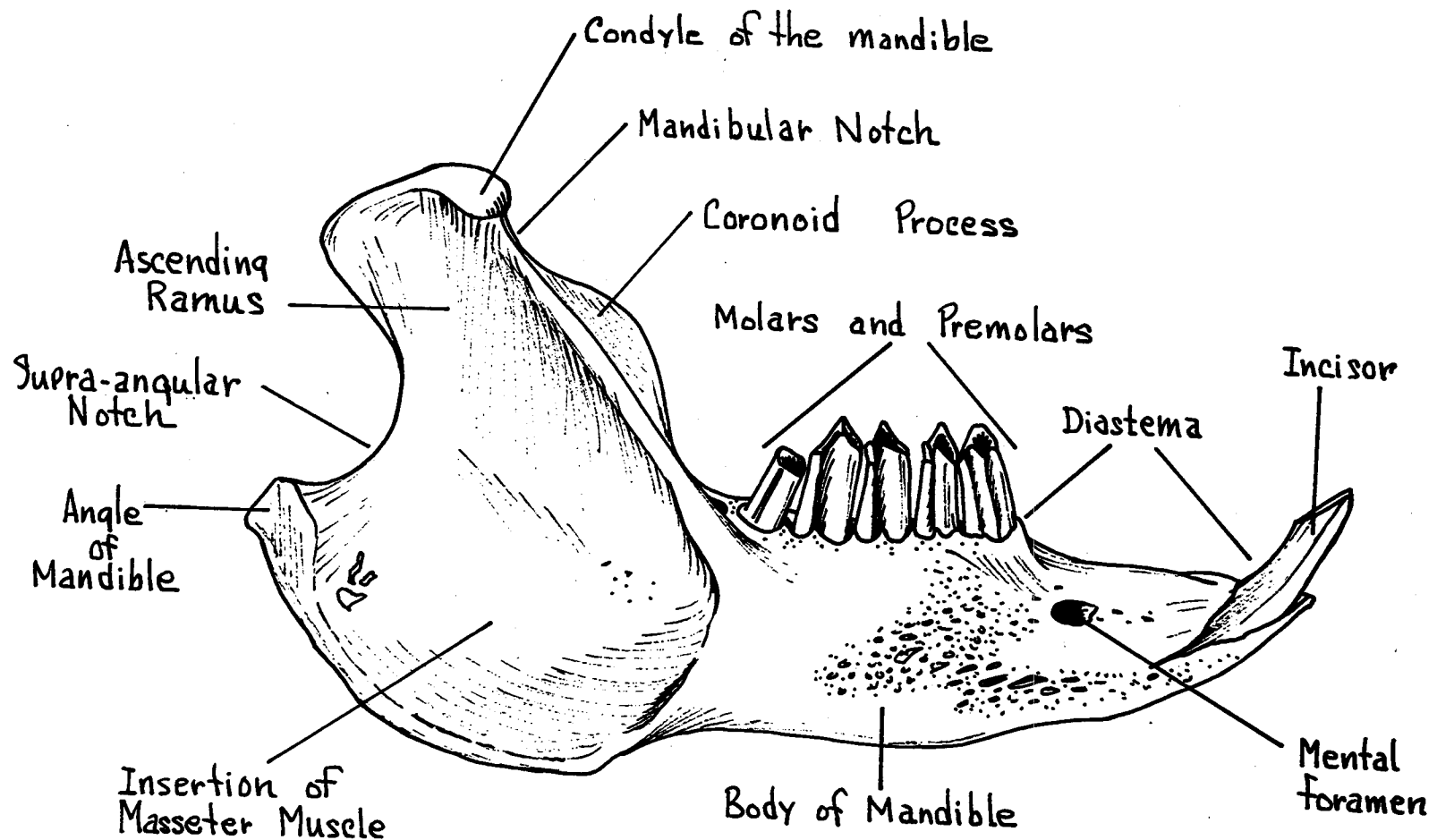


FIG. 6
MANDIBLE
Lateral View

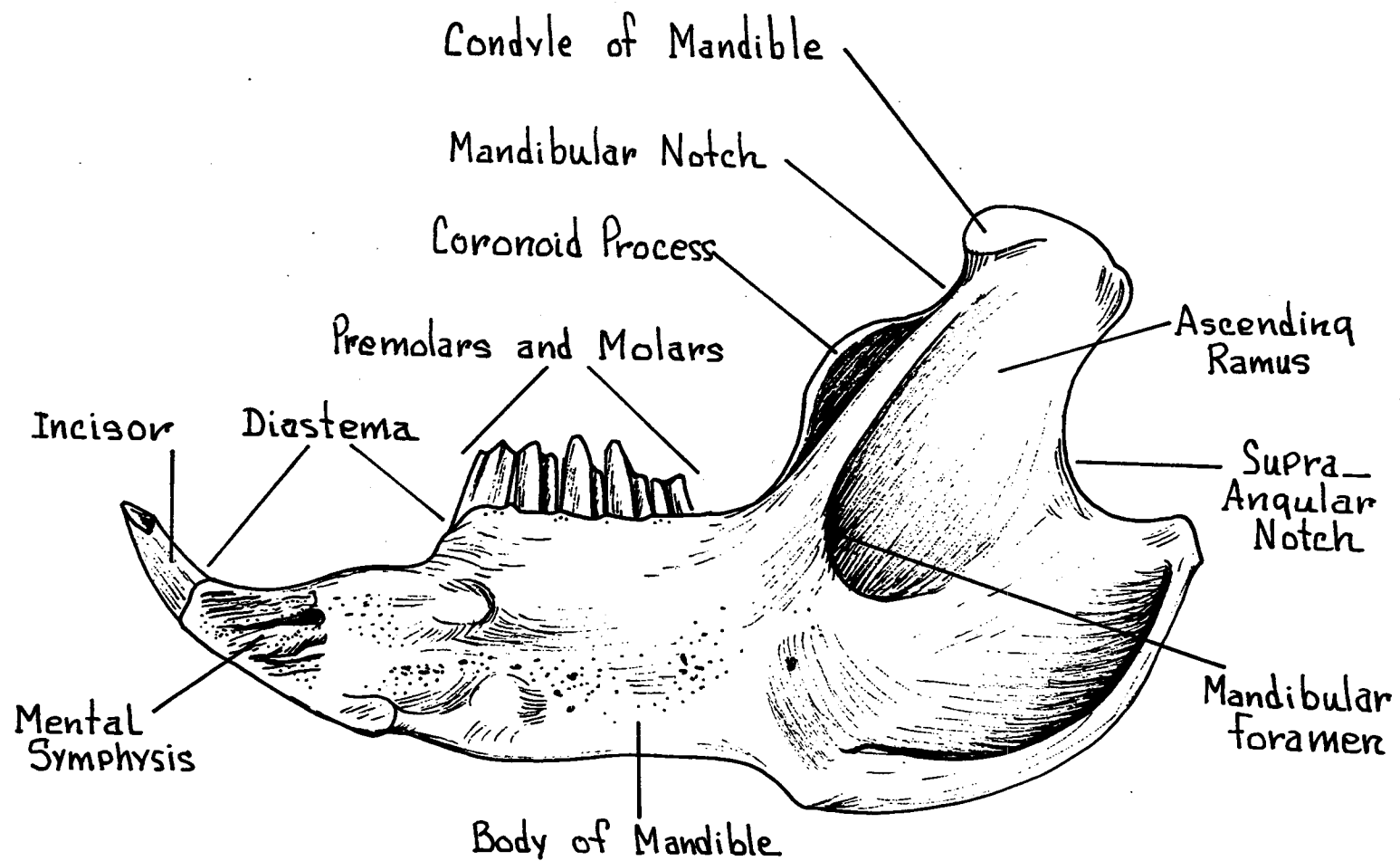


FIG. 7
MANDIBLE
Medial View

Manubrium - 1st sternebra. Most anterior of segments.

Body of Sternum - The middle four sternebrae.

Xiphoid Process - The elongated sixth sternebra.

Xiphoid Cartilage - Broad flat cartilage attached to the
sixth sternebra or xiphoid process.

Costal Cartilages - Laterally placed to sternum. For
the attachment of the ribs.

CLAVICLE - Imperfectly developed. Slender rod-like partially
of cartilage. Medially attached by sternoclavicular
ligament and laterally by cleidodumeral ligament.

SCAPULA - (Figs. 9, 10) Dorsally located. Triangular-shaped
bone. Articulating with the humerus and forming a
portion of the pectoral girdle.

Spine of Scapula - Prominent ridge on lateral surface.

Acromion Process - Antero-ventral projection of spine.

Metacromion Process - Second projection postero-ventrally
from the spine near the acromion
process.

Glenoid Fossa - Cavity for articulation with the humerus.

Coracoid Process - Anterior projection medial to glenoid
fossa.

Supraspinous Fossa - Lateral surface of scapula. Antero-
dorsal to spine.

Infraspinous Fossa - Lateral surface of scapula. Postero-
ventral to spine.

Subscapular Fossa - Cavity on medial surface of scapula.

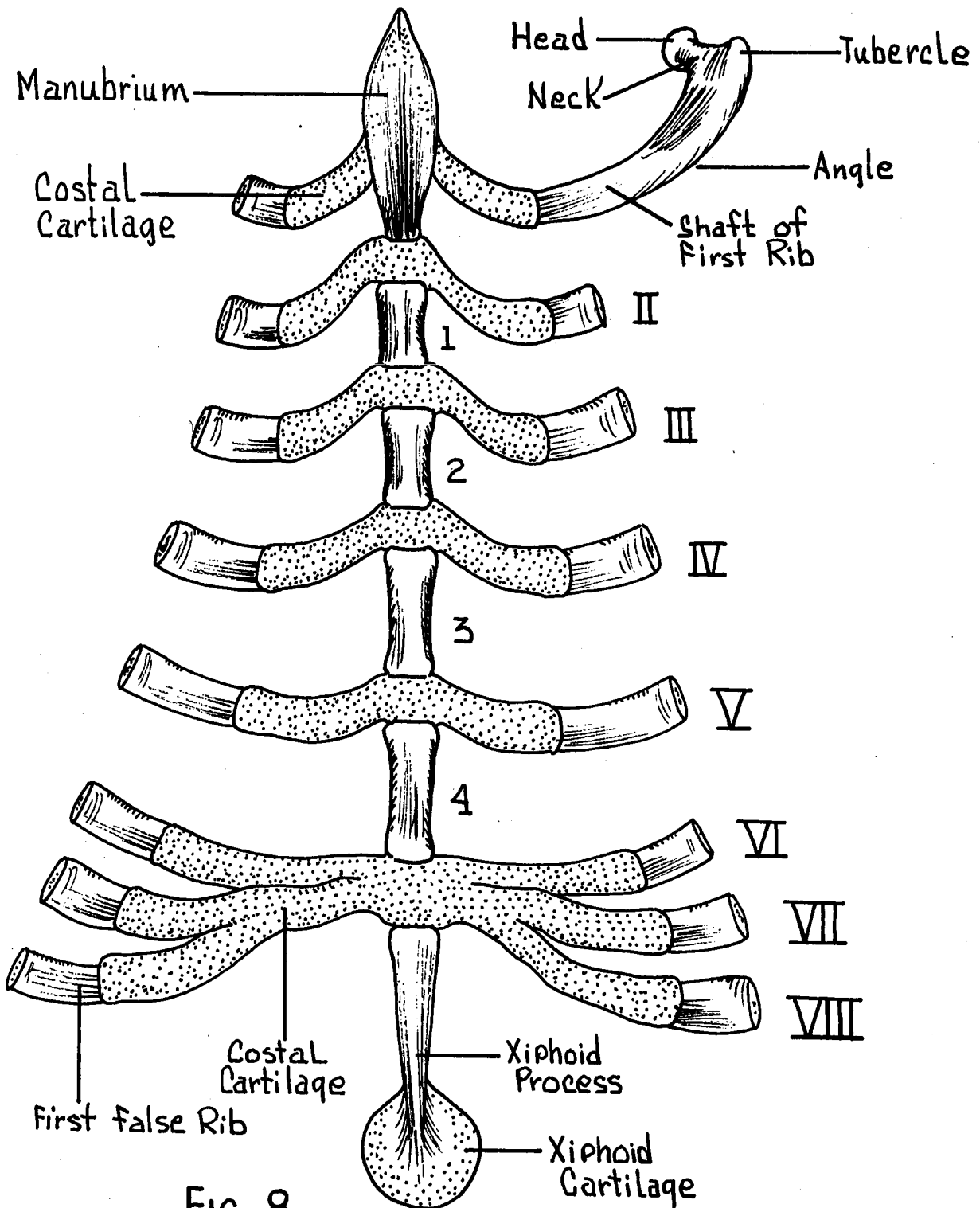


FIG. 8
STERNAL APPARATUS

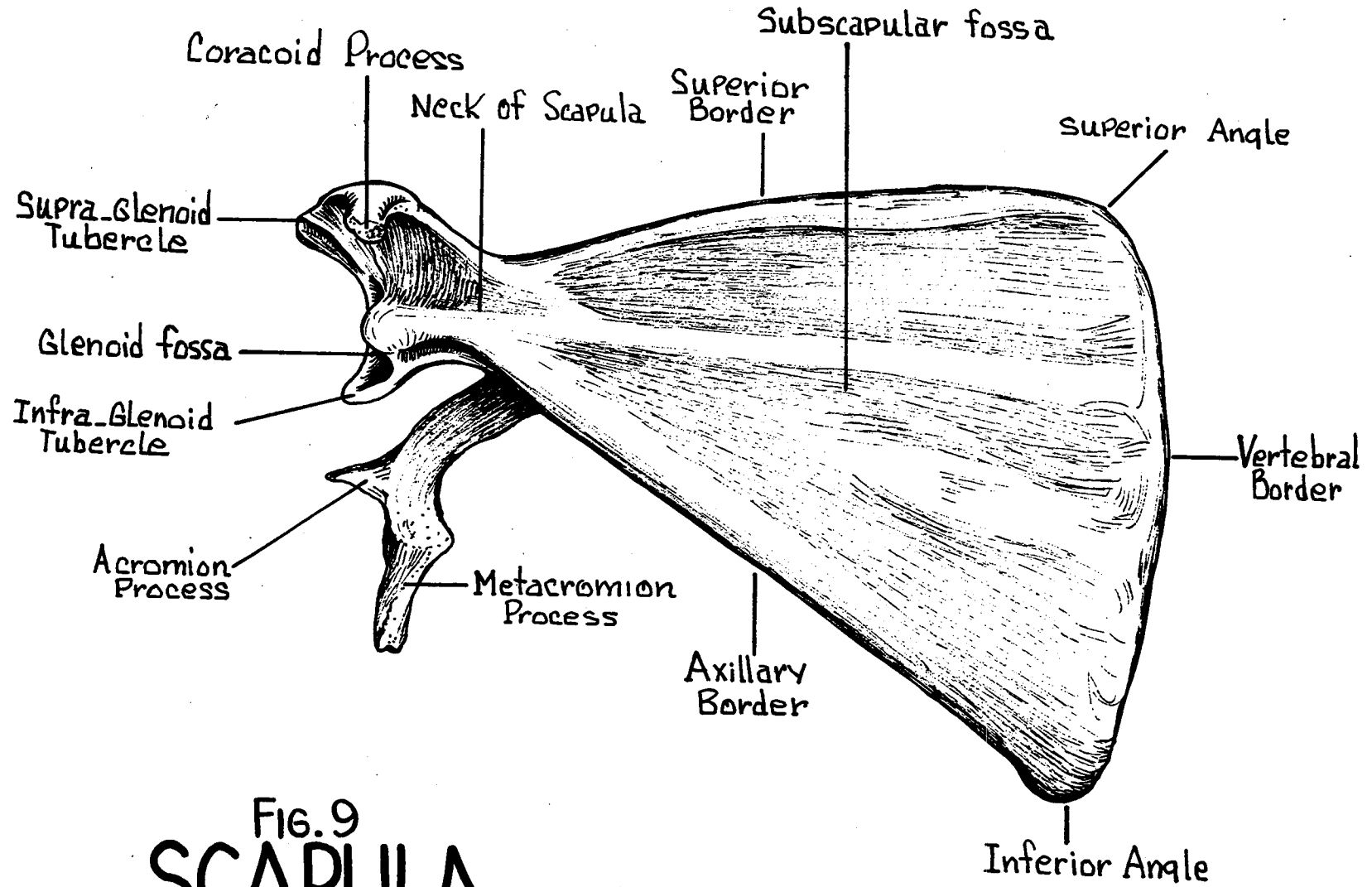


FIG. 9
SCAPULA
Medial View

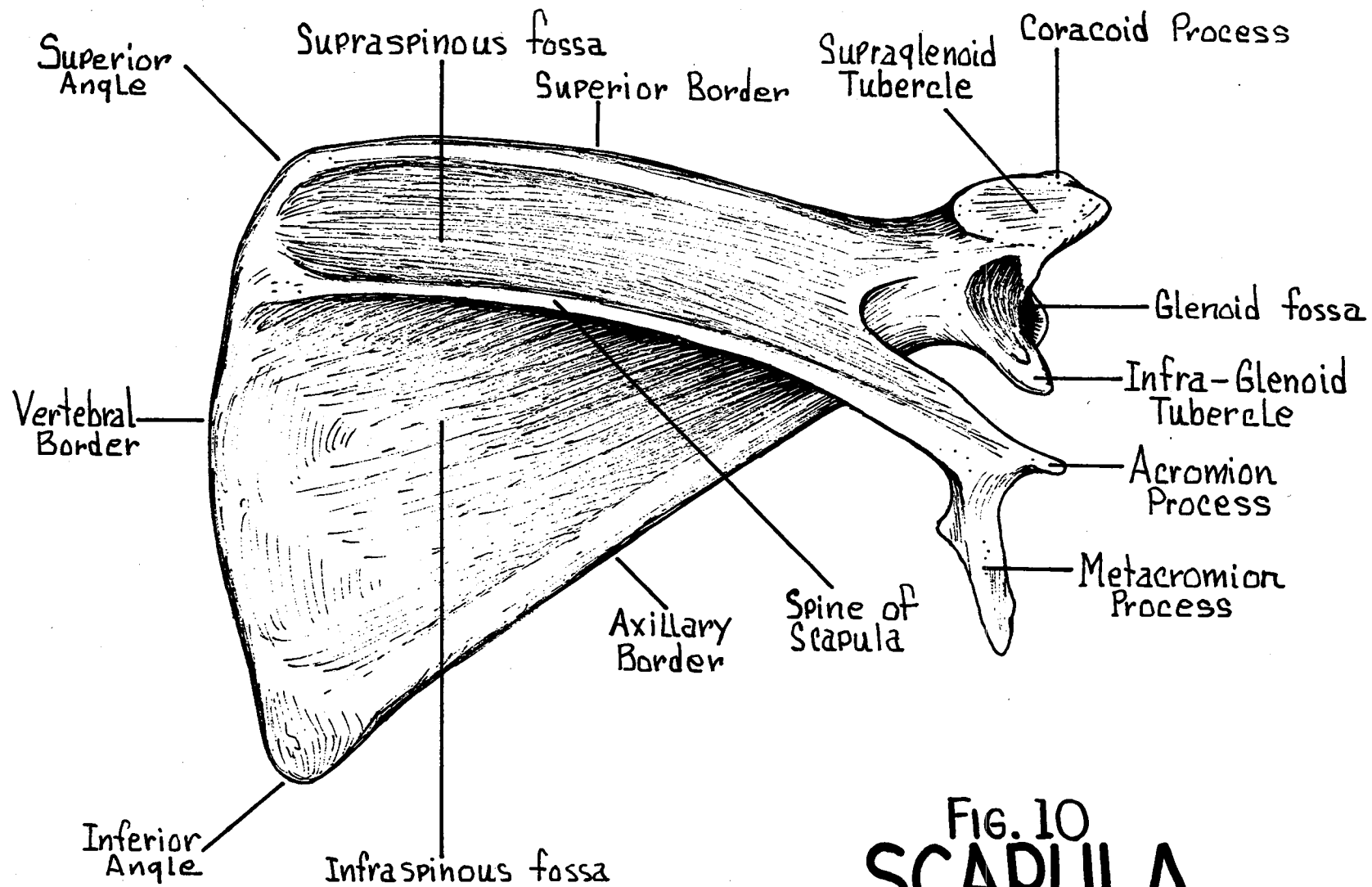


FIG. 10
SCAPULA
Lateral View

Borders of the Scapula -

Vertebral (Suprascapular) - Curved dorsal margin.

Coracoid (Superior) - Anterior margin.

Axillary (Glenoid) - Posterior margin.

Angles of the Scapula -

Superior (Medial) - dorsally located.

Inferior (Posterior) - Postero-ventrally located.

Glenoid (Lateral) - Anteriorly located.

HUMERUS - (Fig. 11) The single bone of the upper arm. Articulates with the scapula of the pectoral girdle.

Head - Postero-medially directed. Articulates with the glenoid fossa of the scapula.

Greater Tuberosity - Antero-lateral prominence near the head of the humerus.

Lesser Tuberosity - Medial prominence near the head.

Intertubercular Groove - Deep furrow separating the greater and lesser tuberosities.

Diaphysis - Central, elongated shaft of humerus.

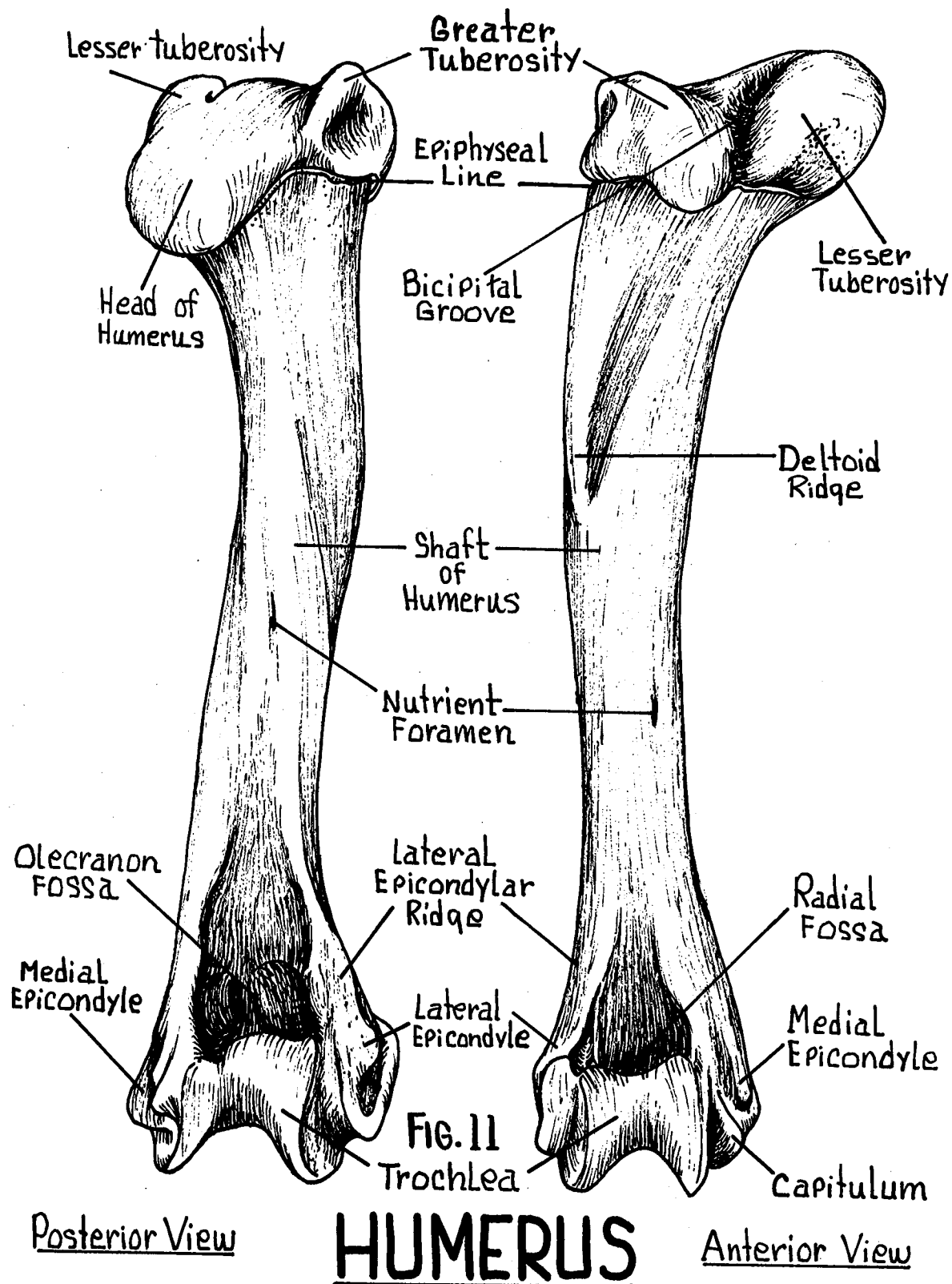
Epiphysis - The extremities (proximal and distal) of the humerus.

Trochlea - Medial part of distal articulating surface.

Capitulum - Lateral part of distal articulating surface for the articulation of the radius.

Medial Epicondyle - Small projection proximal to trochlea.

Lateral Epicondyle - Lateral projection proximal to capitulum.



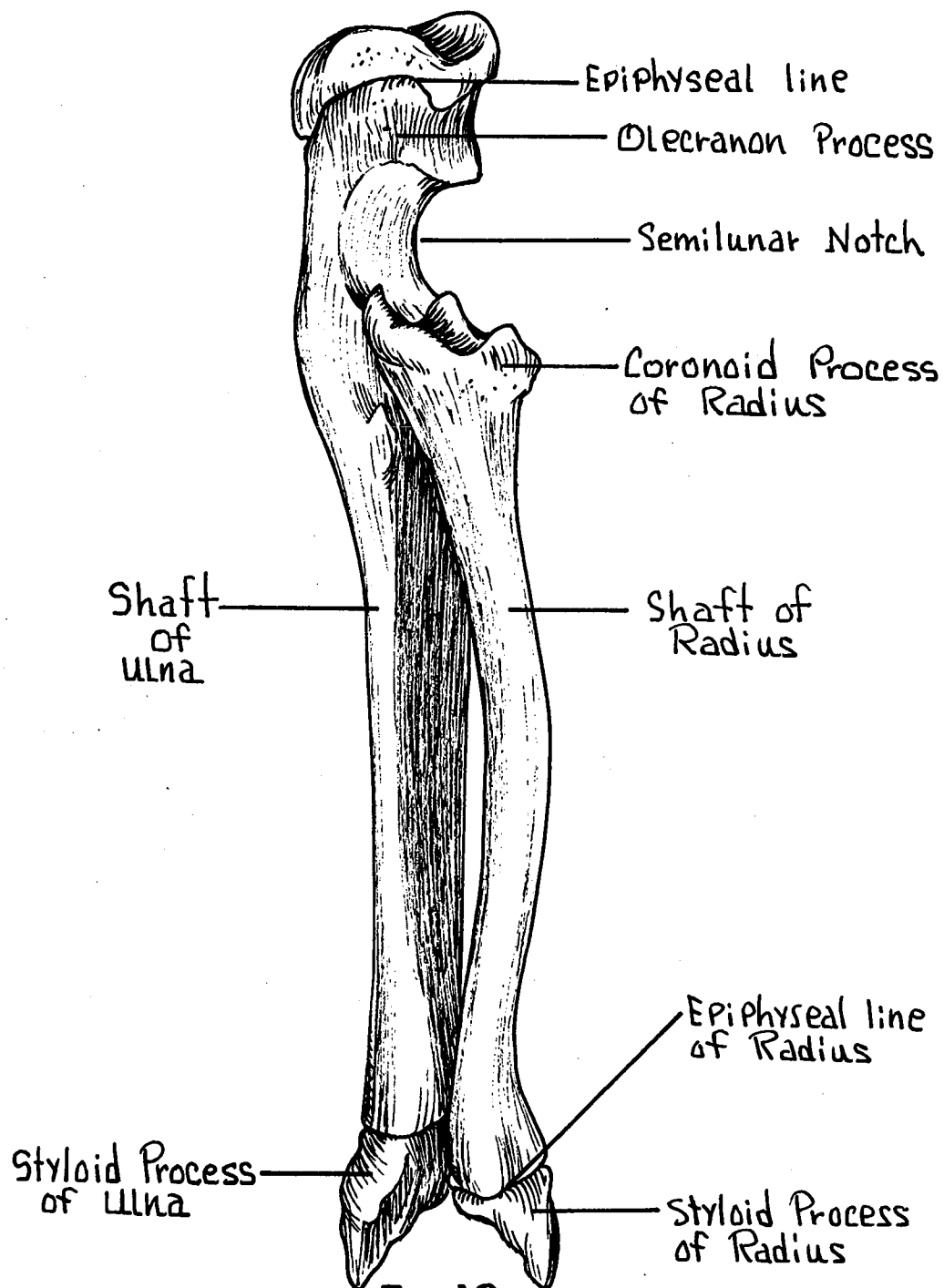


FIG.12
RADIUS AND ULNA
Antero-lateral View

Radial Fossa - Anterior surface. For the articulation of the radius.

Olecranon Fossa - Posterior surface. For the articulation of the olecranon process of the ulna.

ULNA - (Fig. 12) Larger of the two forearm bones. Vertically flattened.

Olecranon Process - Dorsally projecting elbow process.

Semilunar Notch - Distal to olecranon process. Articulates with the trochlea of the humerus.

Radial Notch - For the articulation of the radius.

Styloid Process - Projection at distal end of ulna.

RADIUS - (Fig. 12) Shorter and smaller of the two forearm bones.

Coronoid Process - Proximal projection near head.

Head of Radius - Proximal extremity for articulation with ulna and capitulum of humerus.

Styloid Process - Projection at distal end of radius.

CARPALS - (Fig. 13) Nine "wrist bones" arranged in two rows.

Proximal Row - Navicular, lunate, triquetrum, and pisiform.

Distal Row - Greater multangular, lesser multangular, central, capitate, and hamate.

METACARPALS - Five elements each with base, body and head.

PHALANGES - Three elements on each of the digits except the first which has only two. Terminating in claws.

VERTEBRAL COLUMN - (Fig. 1) Dorsal segments divided into: Cervical, Thoracic, Lumbar, Sacral, and Caudal elements.

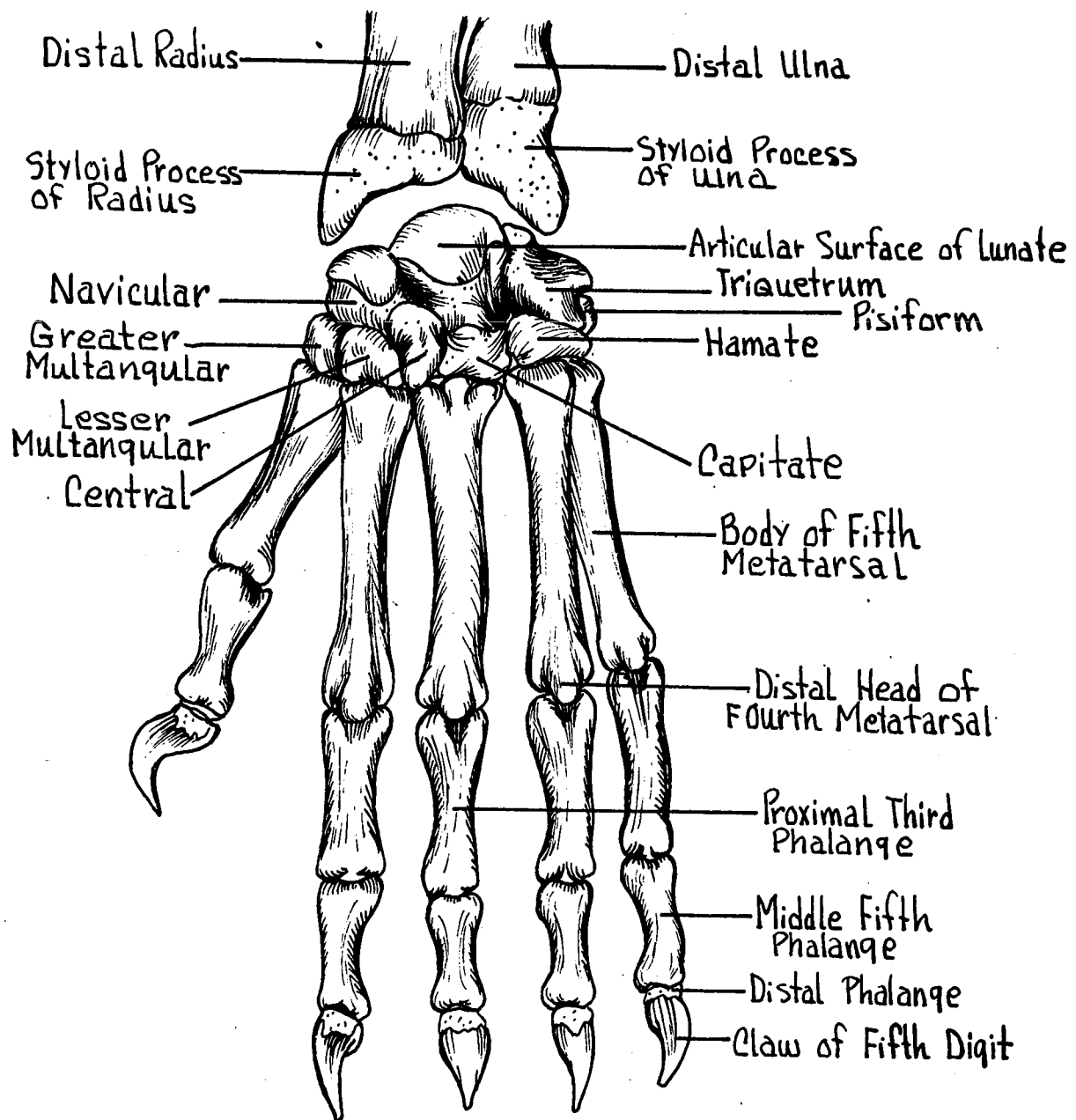


FIG. 13
HAND BONES
 Dorsal View

Cervical Vertebrae - 7 in number. Supports head.

Atlas - (Fig. 14) The first cervical vertebra articulating with the occipital condyles of the occipital bone. No centrum present.

Foramen Transversarium - One pair on each cervical vertebra.

Lateral to centrum,

Atlantal Foramen - One on each side. Dorsal to anterior articular surface. For passage of vertebral artery and vein.

Axis - (Fig. 15) The second cervical vertebra.

Odontoid Process - Anterior projection which represents the centrum of the atlas.

Other Cervical Vertebra - (Fig. 16)

Centrum - Heavy body of the vertebrae.

Neural Arch - Arch dorsal to centrum.

Neural Canal - (vertebral foramen) opening formed by arch for passage of spinal cord caudad.

Neural Spine - (spinous process) Single dorsal median projection.

Transverse Process - Usually paired lateral projections for attachment of muscles.

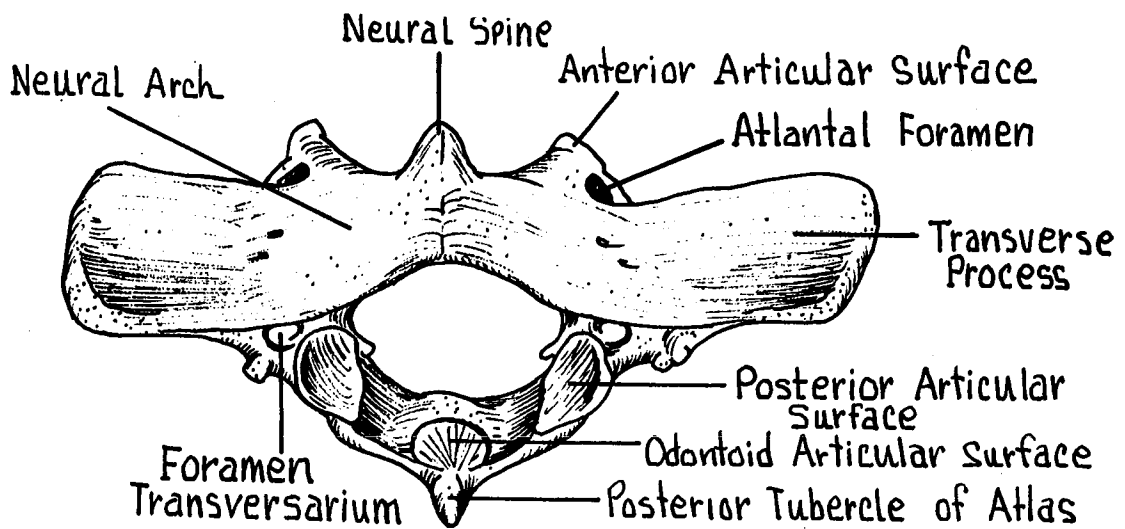


FIG. 14
ATLAS
Inferior View

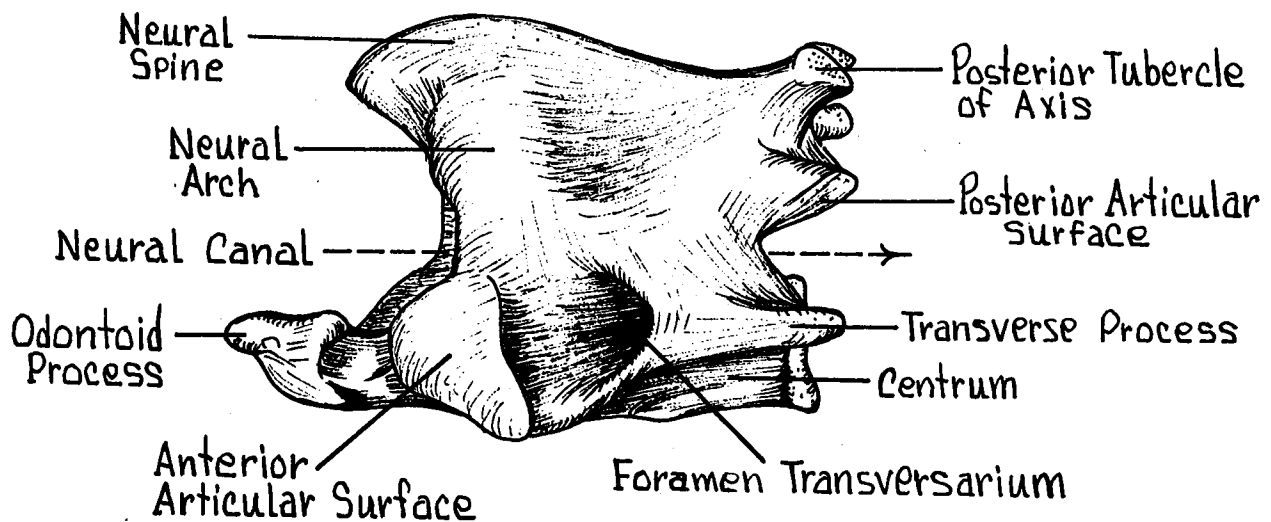


FIG. 15
AXIS
Lateral View

Articular Surfaces - Anterior and posterior pairs.

Thoracic Vertebrae - (Fig. 17) Typically twelve in number. Characterized by lateral attachment of the ribs.

Costal Facets - Articular surface for ribs. One pair on ends of transverse process. Other pair on Centrum, with part of each facet on centra and part on an adjoining one. Each "half facet" is called a demifacet.

Mamillary Process - Small lateral projections on the most caudal of the thoracic vertebrae.

Lumbar Vertebrae - (Figs. 18, 19) Seven in number and are typically more massive and prominent. Absence of costal and tubercular facets for ribs.

Transverse Process - Long and extending cranio-laterally.

Centrum - Heavy in size relative to that of other vertebrae.

Mamillary Process - Small lateral projections near anterior articular facets. For attachment of the longitudinal muscles of the back.

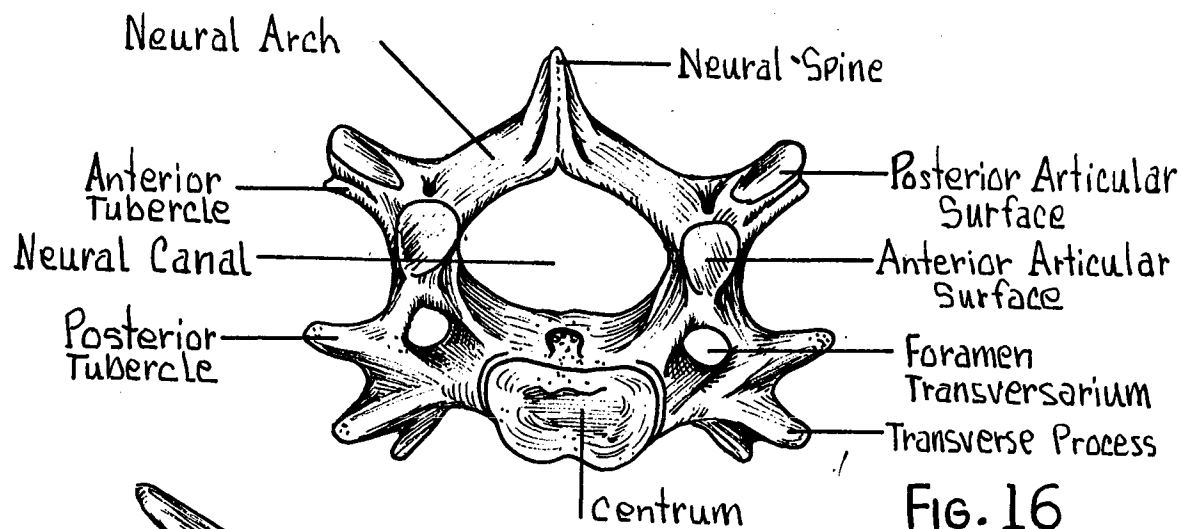


FIG. 16
CERVICAL
Superior View

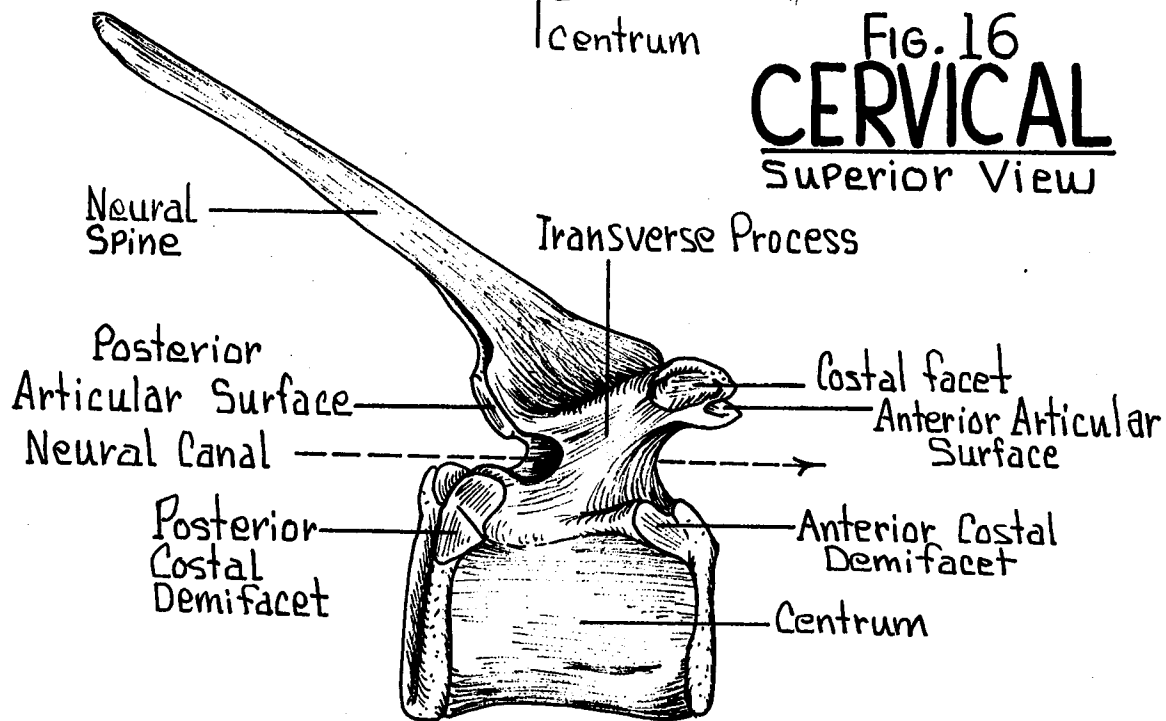


FIG. 17
THORACIC
Lateral View

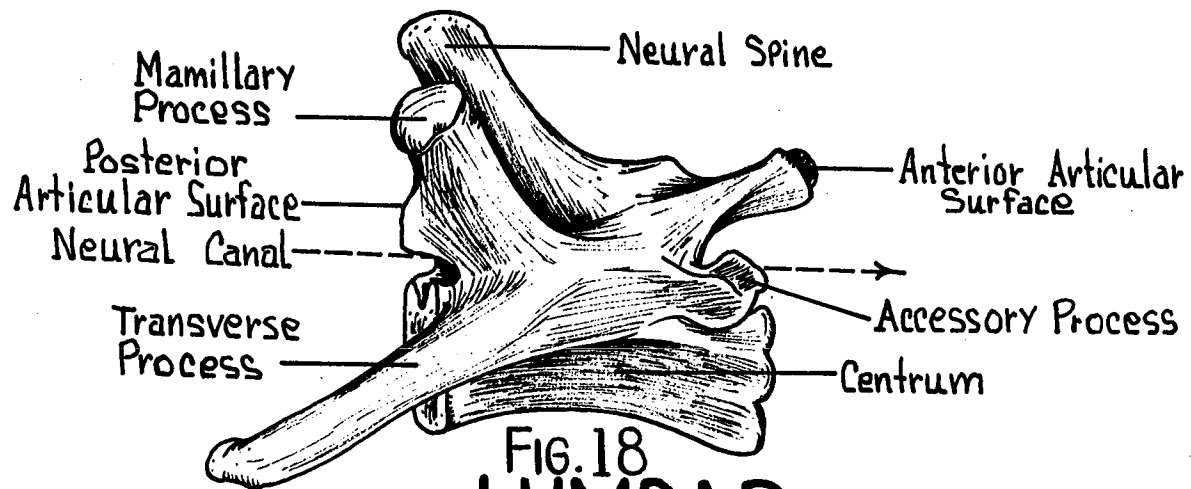


FIG. 18
LUMBAR
Lateral View

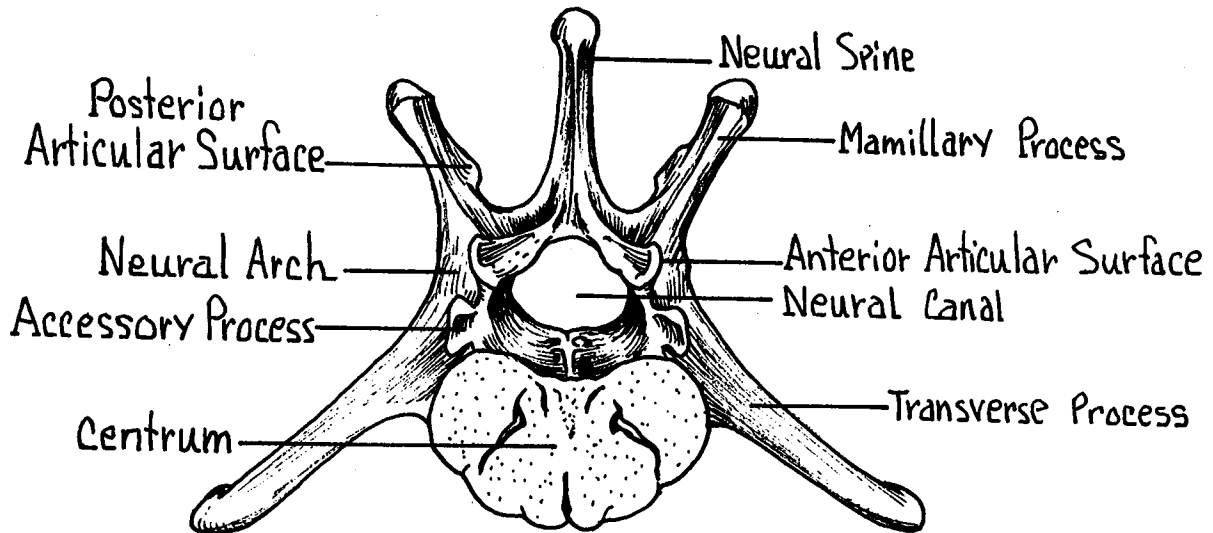


FIG. 19
LUMBAR
Superior View

Accessory Process - Posteriorly directed. One below each of the posterior articular facets.

Sacral Vertebrae - (Figs. 20, 21) Four in number. With partial or complete fusion into a single element, the sacrum. This provides a firm structure for the articulation of the pelvic girdle.

Intervertebral Foramen - Divided into anterior sacral and posterior sacral foramina through which the dorsal and ventral nerve roots pass.

Auricular Process - For the articulation of the innominate bones. Formed by the lateral elements of the first two sacral vertebrae.

Neural Spines - Highly reduced on the dorsal surface.

Caudal Vertebrae - (Fig. 1) Usually 16 in number. All are small and lacking prominent processes for muscle attachment.

RIBS - (Figs. 1, 8) Normally 12 pairs in number. Curved, flattened bones which articulate with the thoracic vertebrae dorsally and the first seven with the sternbrae ventrally by means of the costal cartilages.

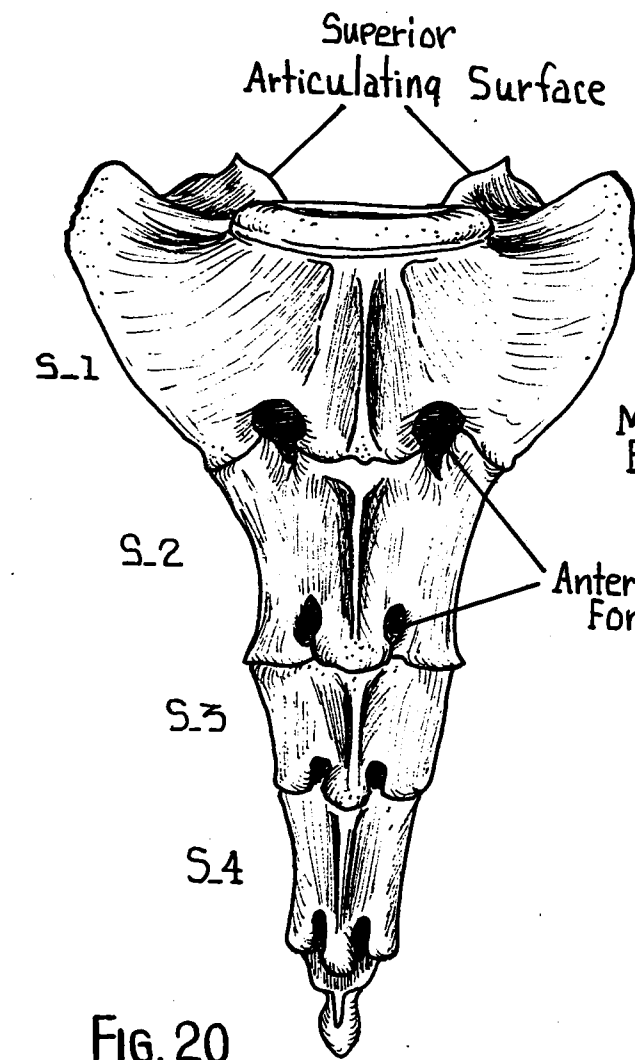


FIG. 20
Ventral View

SACRUM

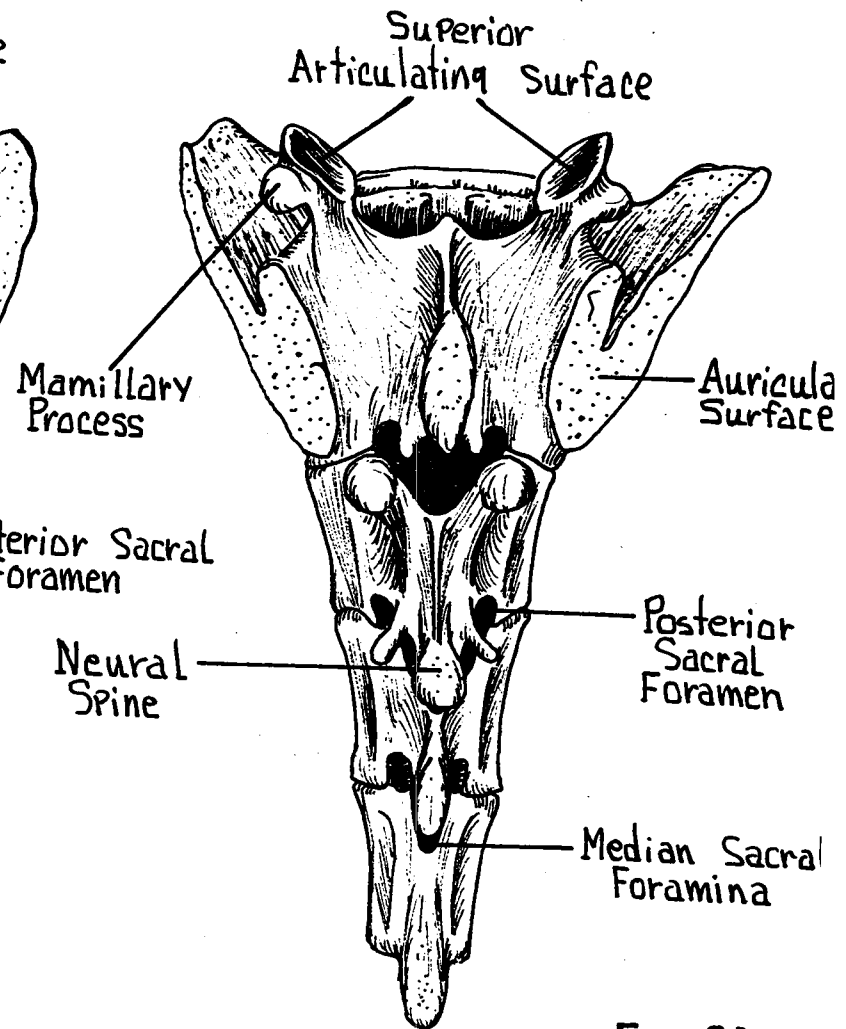


FIG. 21
Dorsal View

Capitulum (Head) - With which the rib articulates with the costal demifacets of two contiguous thoracic vertebrae.

Tubercle - With which the rib articulates with the transverse process of a thoracic vertebrae.

Neck of the Rib - Constricted area between head and tubercle.

Angle of the Rib - Sharpest bend in the shaft of the rib.

Body of the Rib - Shaft or flattened surface.

True Ribs - First seven ribs whose costo-sternal ends articulate with the sternebrae directly.

False Ribs - The remaining five ribs (8-12) not articulating with the sternum. Becoming progressively a typical caudad.

Floating Ribs - Those of the false ribs whose costo-sternal attachments are incomplete.

INNOMINATE BONE - (Figs. 22, 23) Formed by the fusion of three major bones on each side of the body. The right and left elements making up the pelvic girdle. The innominate is formed by the fusion of the ilium, ischium, and pubis.

Ilium - Antero-dorsal projection. Articulates with the auricular process of the sacrum.

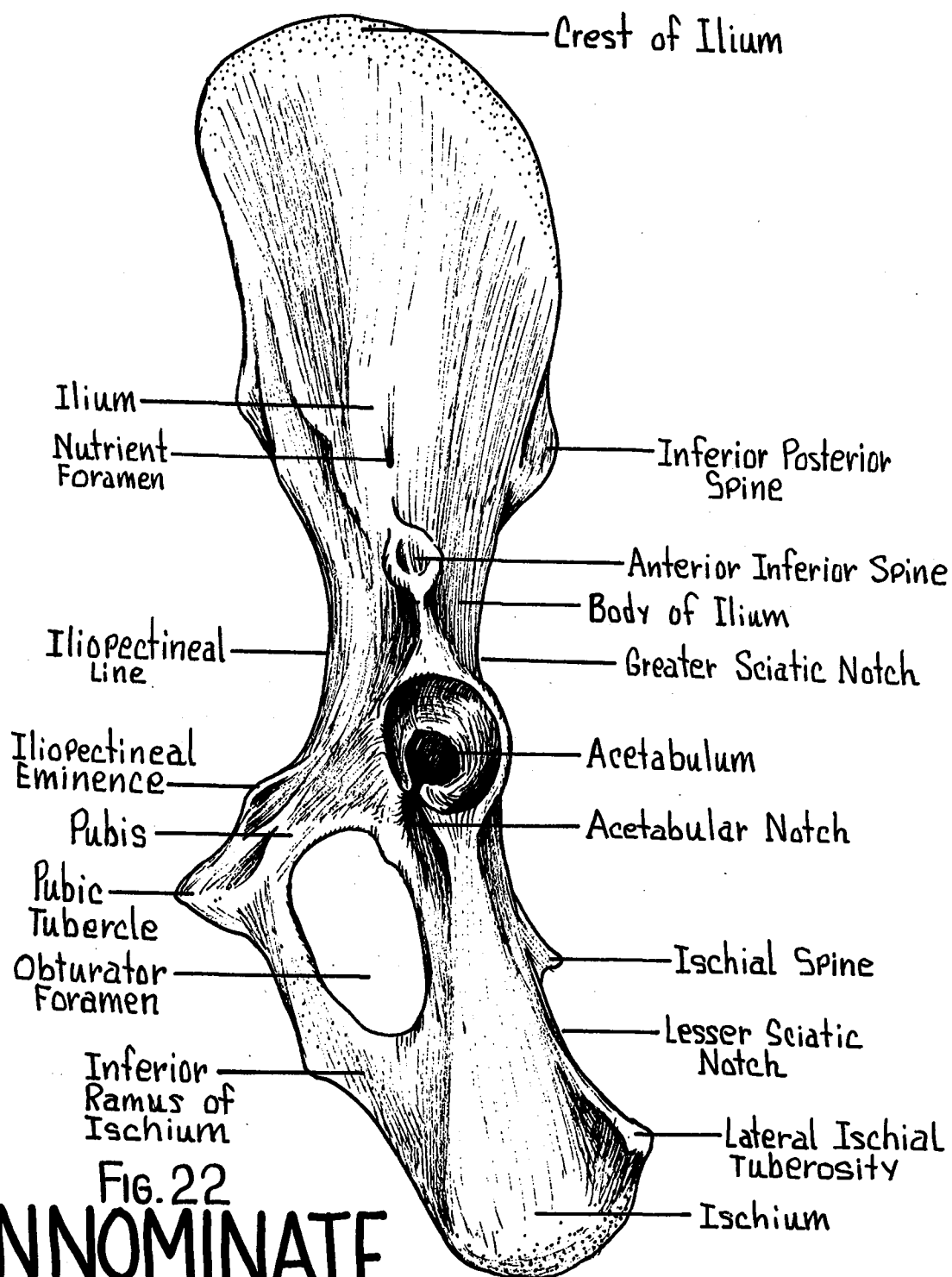


FIG. 22
INNOMINATE
 Lateral Surface

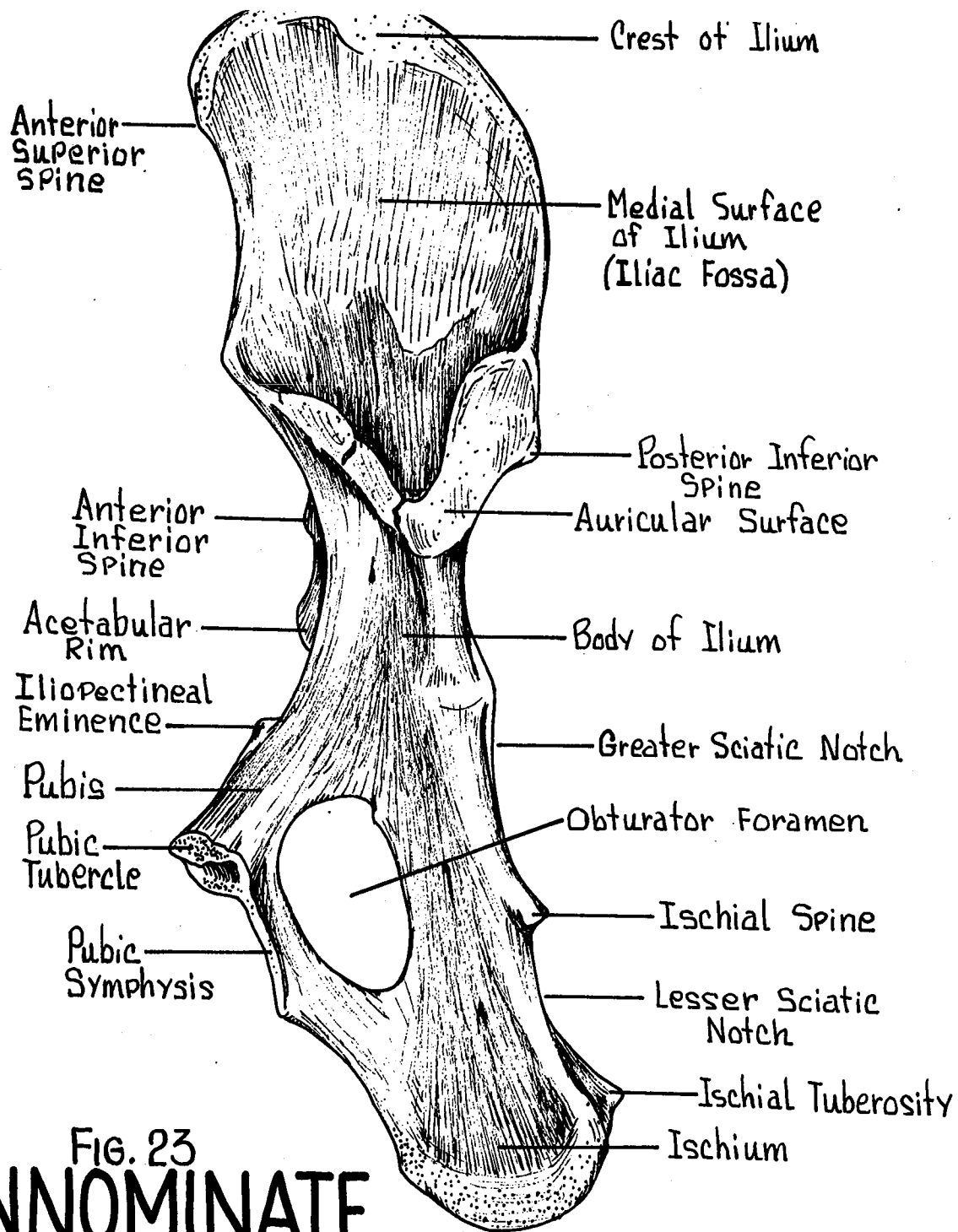


FIG. 23
INNOMINATE
 Medial Surface

Ischium - Ventro-posterior portion. Note the ischial tuberosity and ischial spine. This bone forms part of the ischio-pubic symphysis by which the right and left innominates are joined ventrally.

Pubis - Ventro-anterior portion. Right and left halves meet in the midline to form the pubic symphysis.

Acetabulum - A socket into which the head of the femur articulates.

Acetabular Bone - Small. Forming a portion of the rim of the acetabulum.

Obturator Foramen - Large oval opening between the ischium and pubis.

FEMUR - (Fig. 24) The single bone of the thigh region.

Articulates with the innominate bone.

Head - Ball-shaped articulating directly with the acetabulum of the innominate.

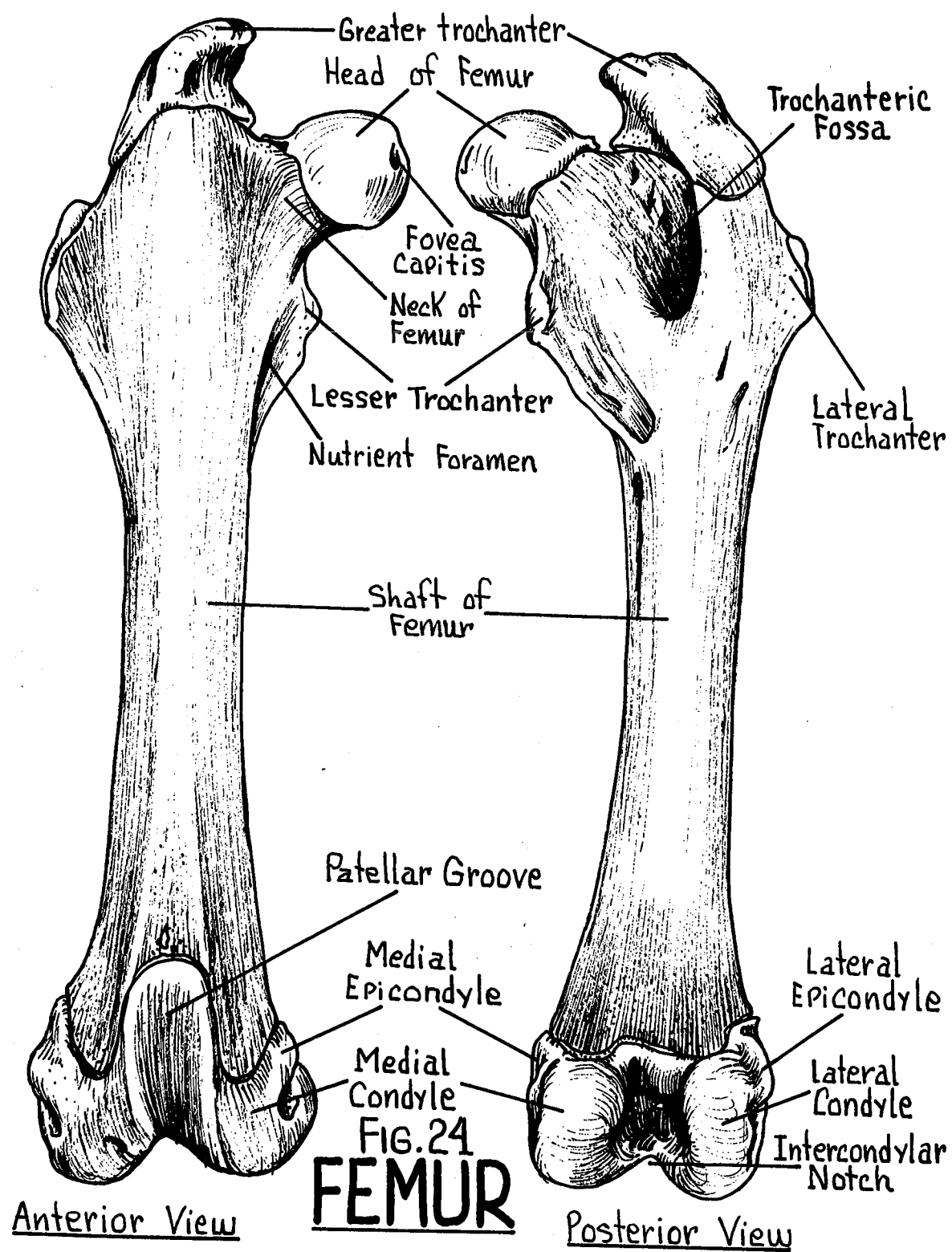
Neck - Constriction distal to the head of the femur.

Greater Trochanter - Heavy beak-like projection anterior to the head. Forms the lateral and proximal end of the bone.

Lesser Trochanter - Postero-medial projection distal to the head.

Lateral Trochanter - On the lateral surface of the femur opposite the lesser trochanter.

Trochanteric Fossa - A deep depression medial to the greater trochanter.



Lateral Condyle - Lateral distal articulating surface.

Medial Condyle - Medial distal articulating surface.

Intercondyloid Fossa - Depression between the two condyles.

Patellar Groove - On anterior surface. Distal end of femur.

PATELLA - (Fig. 1) A sesamoid-type bone, formed by an ossification within the quadriceps tendon.

TIBIO-FIBULA - (Fig. 25) Separate tibia and fibia bones at the proximal halves and fused throughout the distal half of the bone.

Lateral Condyle - Proximal lateral articulating surface.

Medial Condyle - Proximal medial articulating surface.

Crest of Tibia - Anterior ridge on tibia bone.

Medial Malleolus - Medial projection at distal end.

Lateral Malleolus - Lateral projection at distal end. The distal end of the tibio-fibula bone articulates with the calcaneus and astragalus tarsal bones.

TARSAL BONES - (Fig. 26) "Ankle bones" arranged in two rows.

Proximal Row - Astragalus and calcaneus.

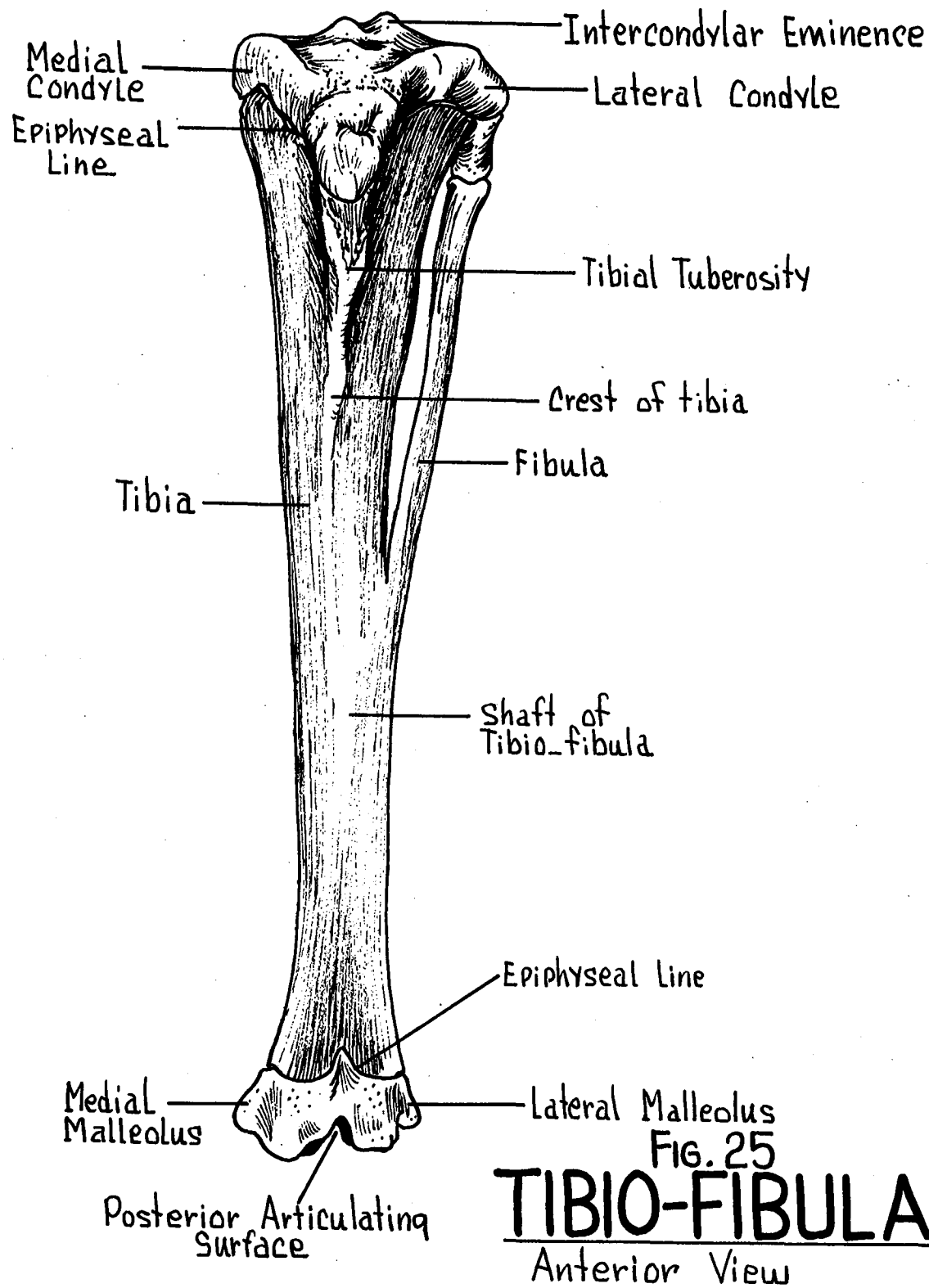
Intermediate Bone - Navicular.

Distal Row - 2nd and 3rd cuneiform and the cuboid bone.

The 1st cuneiform is partially fused with the proximal portion of the 2nd metatarsal.

METATARSALS - (Fig. 26) Four in number, the 1st being absent, each with a base, body, and head.

PHALANGES - (Fig. 26) 3 elements on each of the digits.



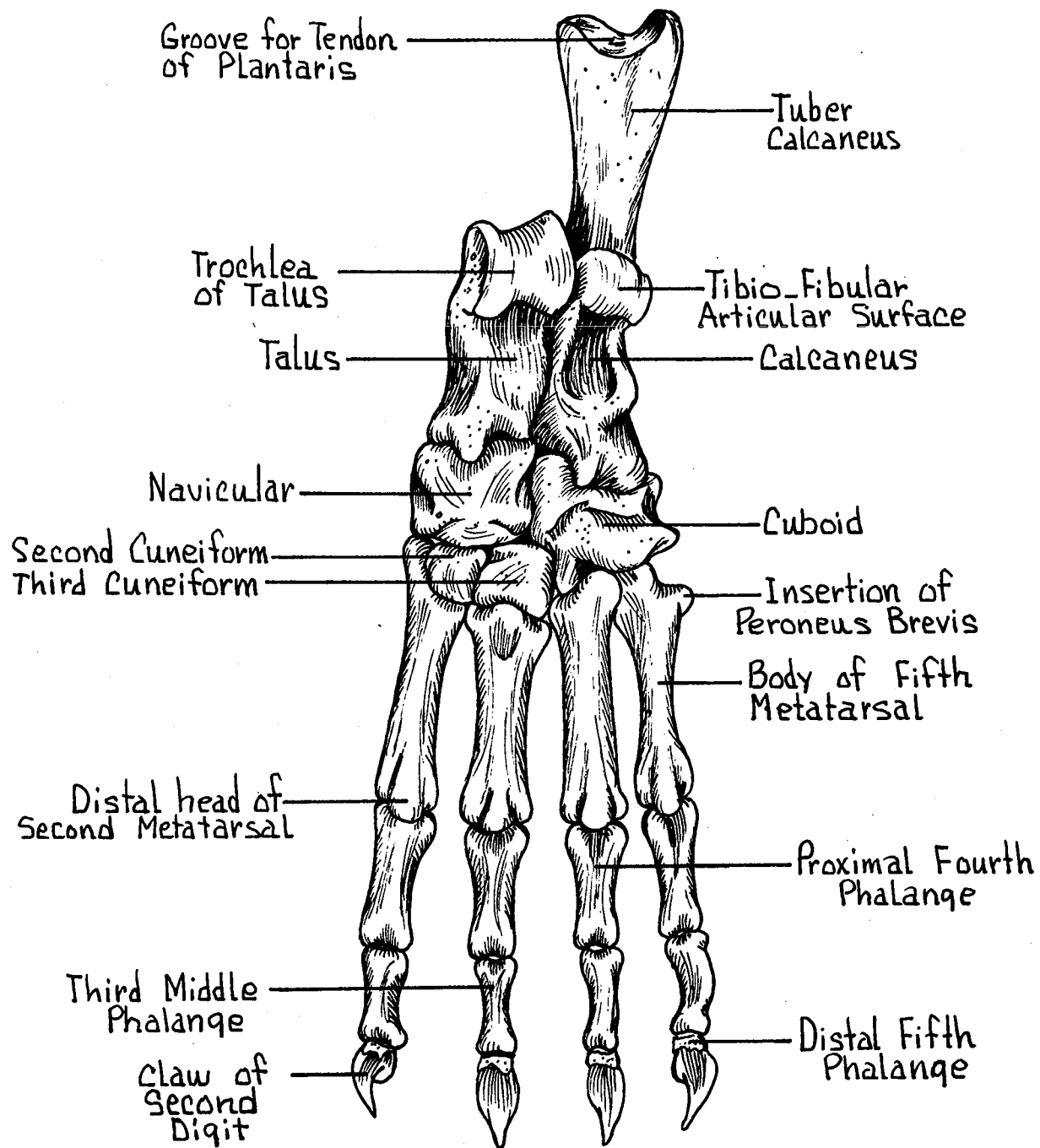


FIG. 26
FOOT BONES
 Dorsal View

IV. MUSCULAR SYSTEM

SUPERFICIAL MUSCLES - (Fig. 27)

SUBCUTANEOUS MUSCLES

Cutaneous Maximus - A broad thin muscle connecting the skin to the body wall. From the proximal humerus to the skin. Moves the skin.

Platysma - A thin muscle arising from the manubrium to insert at the base of the ear. Covers most of the head and neck. Moves the facial skin.

MUSCLES OF THE NECK AND BACK - (Fig. 28)

Splenius - Mid-dorsal fascia to the crest of the supraoccipital bone. Aids in turning and raising head.

Occipitoscapularis - From the crest of the supraoccipital bone to the inferior angle of the scapula. Draws scapula dorso-cranial.

Anterior Trapezius - (Superior) Crest of occipital bone to the spine and metacromion process of scapula. Draws scapula dorso-cranial.

Posterior Trapezius - (Inferior) Spines of thoracic vertebrae and lumbodorsal fascia to the spine of the scapula. Draws the scapula dorso-caudal.

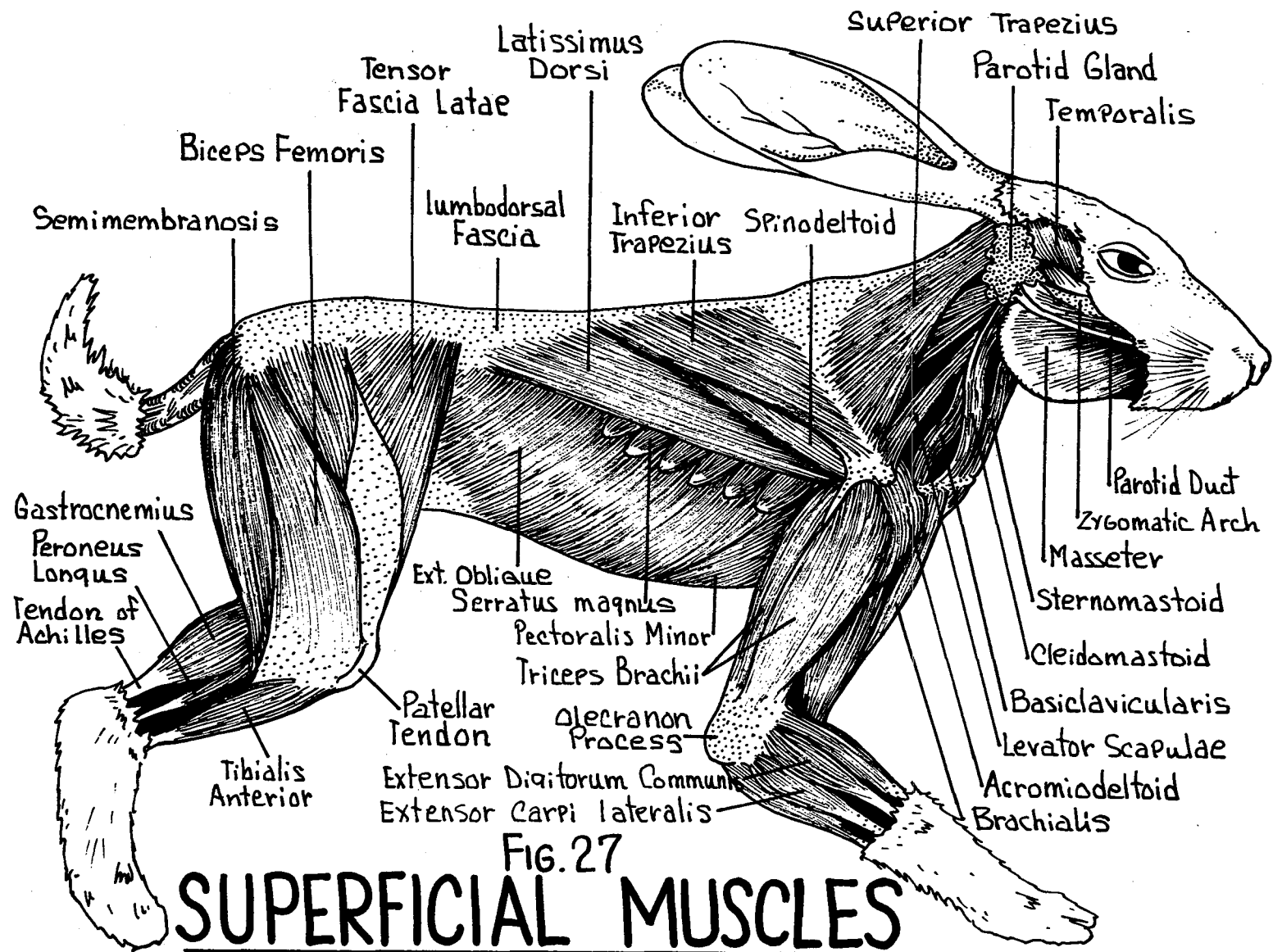
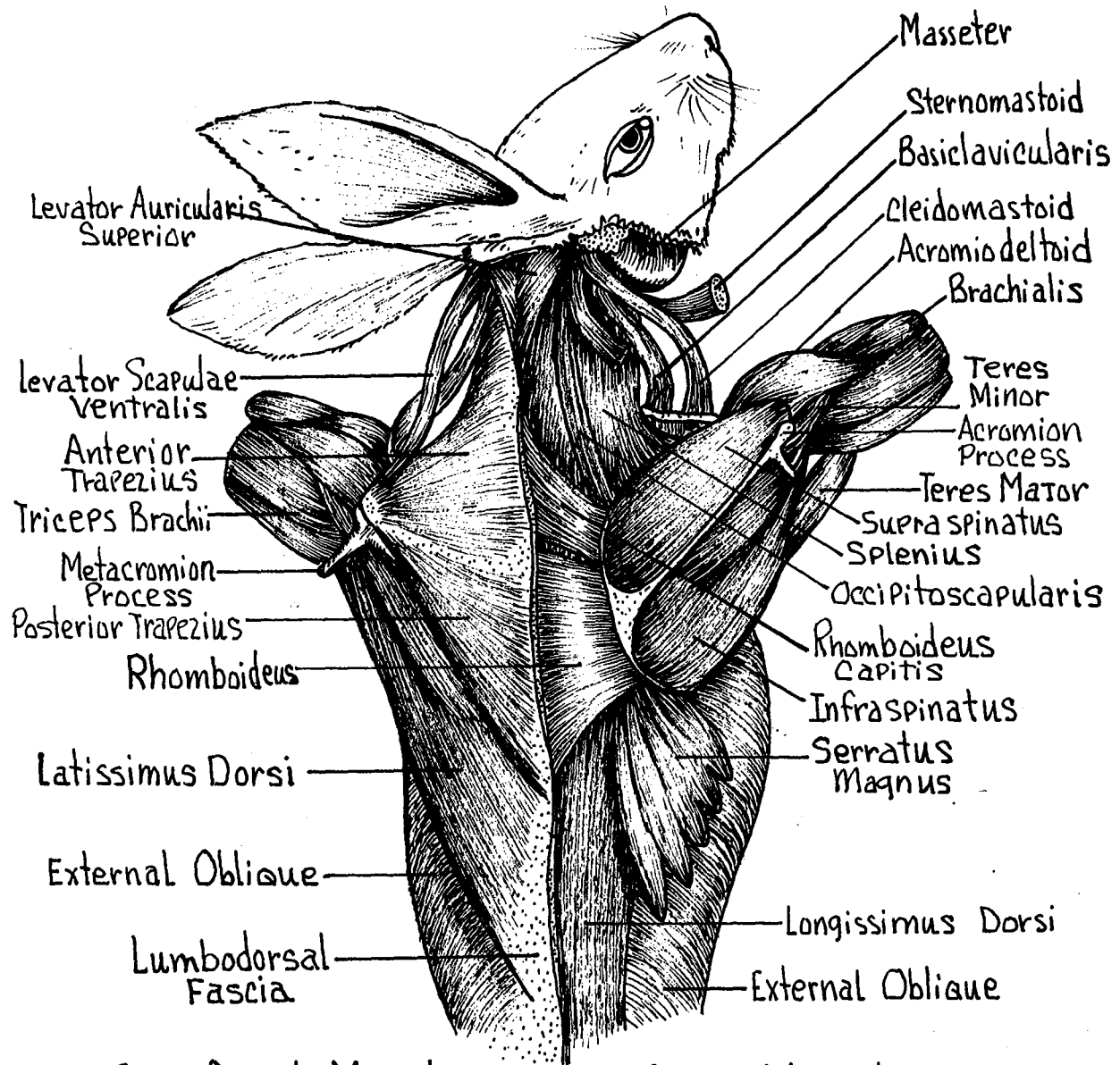


Fig. 27

SUPERFICIAL MUSCLES

Lateral View



Superficial Muscles Deep Muscles

FIG. 28

NECK AND BACK MUSCLES

Latissimus Dorsi - Lumbo-dorsal fascia to the proximal medial surface of the humerus. Draws the humerus dorso-caudad.

Levator Scapulae Ventralis - Basioccipital bone to the metacromion process of the scapula. Draws the shoulder and arm dorso-cranial.

Rhomboideus - Spines of cervical and thoracic vertebrae to the vertebral border of the scapula. Draws the scapula cranio-medial.

Serratus Ventralis - (Magnus) Sternal ends of the 2nd-8th ribs to the inferior angle of the scapula. Draws the scapula ventrally.

External Oblique - Lumbodorsal fascia and posterior ribs to the linea alba and pubis. Constricts abdomen and viscera.

Longissimus Dorsi - Epaxial muscle in the area of the vertebral column. Follows the vertebral column throughout its entire length. Aids in moving the vertebral column.

LUMBODORSAL FASCIA - (Fig. 28) A wide sheet of tough, white fascia covering the lumbar region. For origin and insertion of several important muscles of the back region.

MUSCLES OF THE THROAT AND CHEST - (Fig. 29)

Sternomastoid - From the manubrium to the mastoid process.

Rotates and draws the head ventrad.

Cleidomastoid - Mastoid process to the clavicle. Draws the clavicle craniad.

Basioclavicularis - Basiooccipital bone to the clavicle.

Draws clavicle and shoulder craniad.

Masseter - Zygomatic arch to the lateral surface and ramus of the mandible. Elevates the mandible.

Digastric - Mastoid and jugular process to the mandible near the mental symphysis. Depresses mandible.

Mylohyoid - Mylohyoid line of mandible to the median raphe. Raises the floor of the mouth.

Sternohyoid - Manubrium and 1st costal cartilage to the greater cornu of the hyoid bone. Draws the hyoid apparatus caudad.

Sternothyroid - Sternum and 1st costal cartilage to the greater cornu of the hyoid bone. Draws the hyoid apparatus caudad.

Sternothyroid - Sternum and 1st costal cartilage to the lateral surface of thyroid cartilage of the larynx. Draws larynx caudad.

Cricothyroid - From the cricoid cartilage to the thyroid cartilage of the larynx. Supports larynx.

Pectoralis Major - A large sheet of muscle covering most of the chest region. From the manubrium and sternabrae II and III to the proximal medial surface of the humerus. Draws the humerus mediad.

Pectoralis Primus - Manubrium to the medial surface of the humerus. Draws humerus mediad.

Pectoralis Minor - Manubrium to the clavicle and spine of the scapula. Draws arm and shoulder towards the chest.

Scalenus - Lateral rib surface to the cervical vertebrae. Moves the ribs craniad as in respiration.

Transverse Costarum - From the second sternabrae to the 1st rib. Draws the sternum anterior.

External Intercostal - Fibers between the true ribs. Draws the ribs forward as in respiration.

Internal Intercostal - Fibers at right angle to the external intercostal. Draws the ribs backwards. Aids in respiration.

External Oblique - Last ribs and lumbodorsal fascia to the linea alba and pubis. Constricts abdomen.

Internal Oblique - Beneath external oblique. Lumbodorsal fascia to linea alba. Fibers run at an angle to the external oblique. Constricts abdomen.

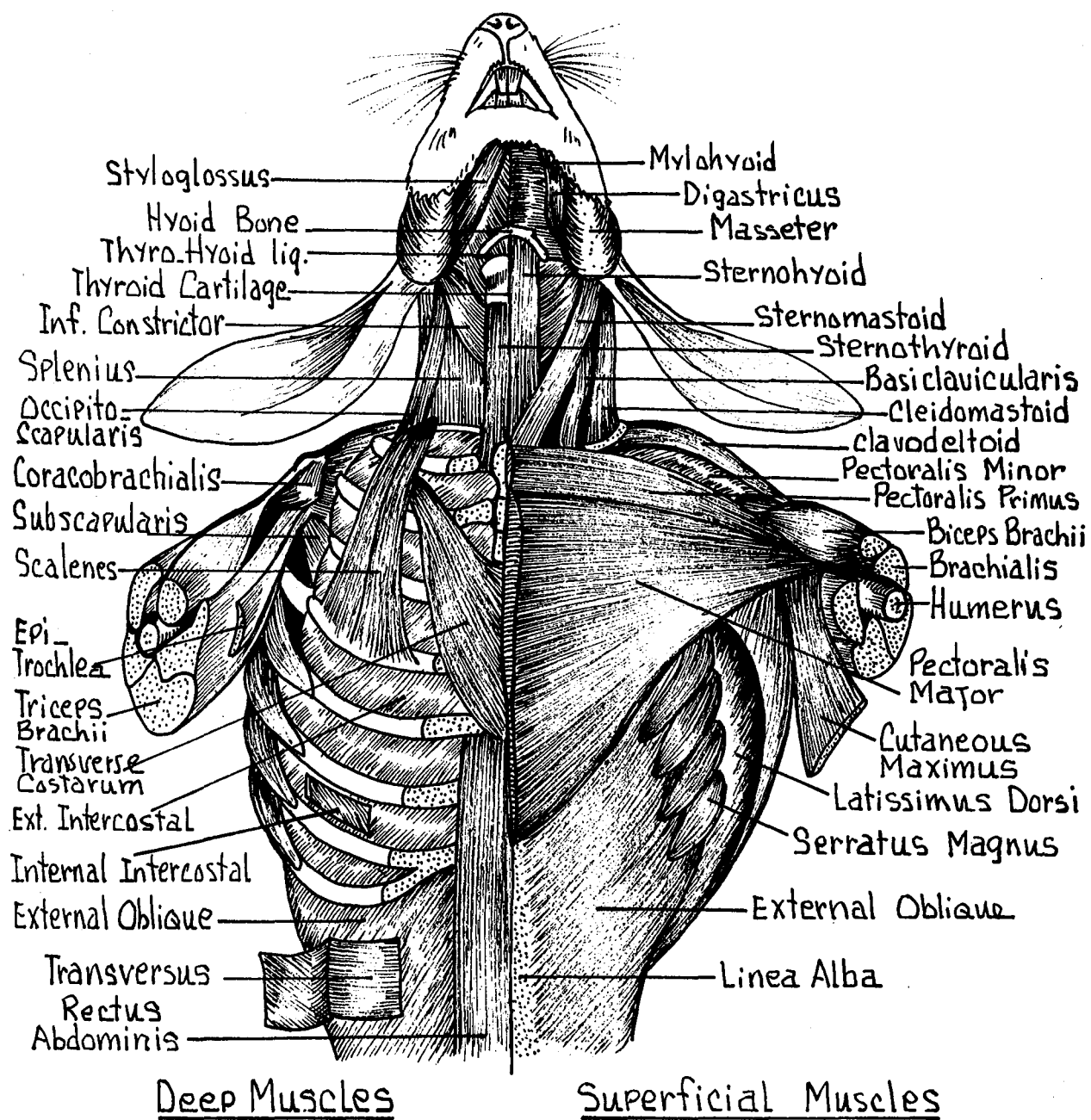


FIG. 29
THROAT AND CHEST MUSCLES

Transversus Abdominis - Beneath internal oblique. Lumbo-fascia and posterior ribs to linea alba. Constricts abdomen.

Rectus Abdominis - Ventral surface of sternum and costal cartilages to the pubic symphysis.
Runs lateral to linea alba. Constricts abdomen and retracts ribs.

MUSCLES OF THE ARM AND SHOULDER - (Figs. 30, 31)

Clavodeltoid - (Clavobrachialis) Clavicle to the middle of the humerus. Extends the arm.

Acromiodeltoid - Acromion and metacromion process to the deltoid ridge of the humerus. Flexes and abducts the arm.

Spinodeltoid - Spine of the scapula to the deltoid ridge. Rotates and flexes arm.

Supraspinatus - Supraspinous fossa of the scapula to the greater tuberosity of the humerus.
Rotates, abducts and extends the arm.

Infraspinatus - Infraspinous fossa to the greater tuberosity. Rotates arm laterad.

Teres Major - Axillary border of the scapula to the greater tuberosity of the humerus. Flexes and rotates the arm mediad.

Teres Minor - Axillary border of the scapula and subscapularis muscle to the insertion of the teres major. Flexes and rotates arm mediad.

Subscapularis - Medial surface of the scapula to the lesser tuberosity of the humerus.

Adducts and rotates arm mediad.

Coracobrachialis - Coracoid process of scapula to the proximal surface of the humerus.

Extends and rotates arm mediad.

Triceps Brachii - Consists of three heads.

Lateral Head - (Caput Laterale) From the proximal shaft of the humerus to the olecranon process of the ulna. Extends forearm.

Medial Head - (Caput Mediale) From the middle of the shaft of the humerus to the olecranon process of the ulna. Extends the forearm.

Long Head - (Caput Longum) From the axillary border of the scapula to the olecranon process. Extends the forearm and flexes the arm.

Epitrochlear - Ventral border of the latissimus dorsi near its insertion into the humerus to the olecranon process of the ulna.

Extends the forearm and rotates the ulna.

Brachialis - From the middle of the humerus to the radius. Flexes the forearm.

Biceps Brachii - From the supraglenoid tuberosity of the scapula to the proximal surface of the radius. Flexes forearm.

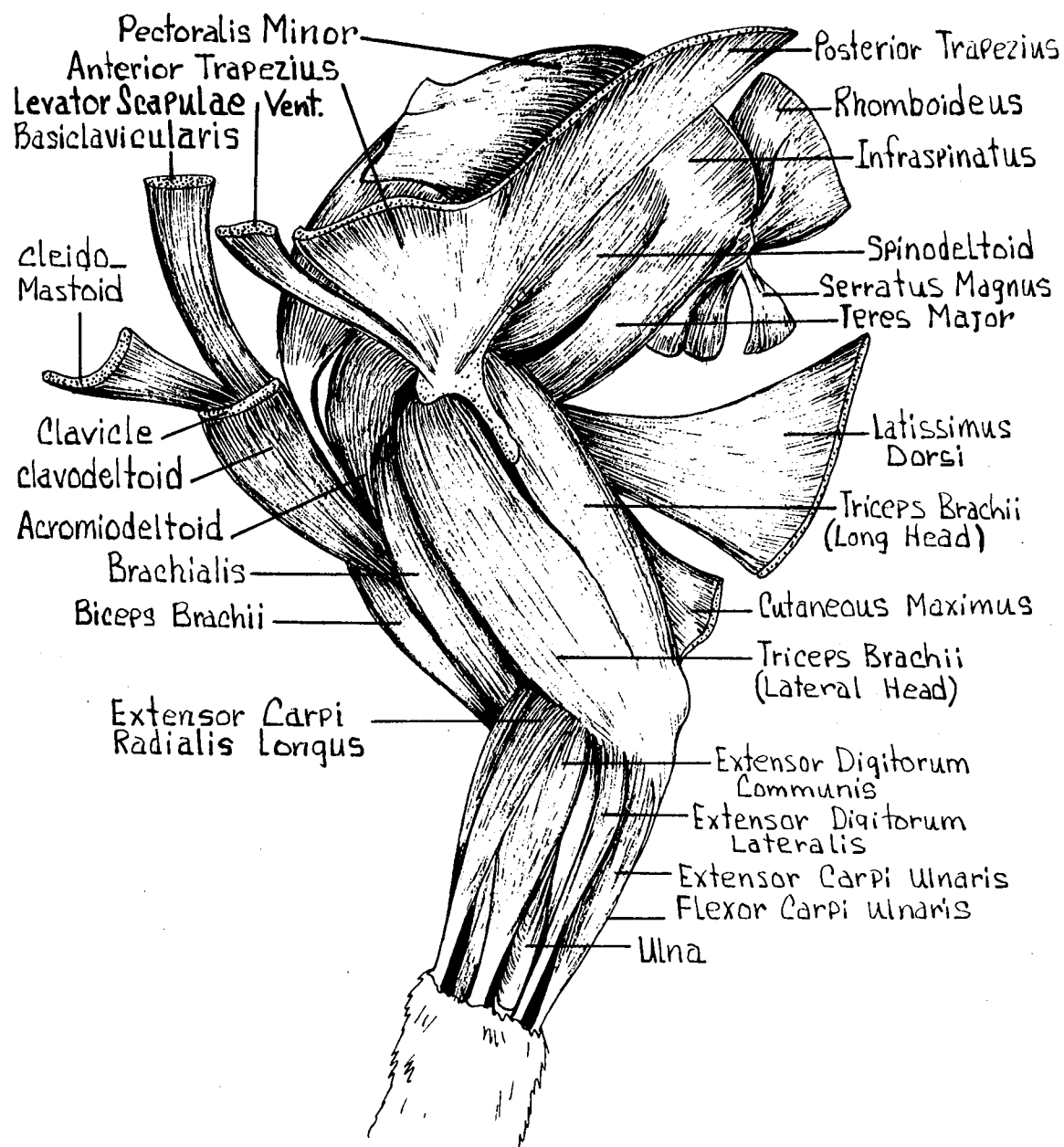


FIG. 30
ARM AND SHOULDER MUSCLES
 Lateral View

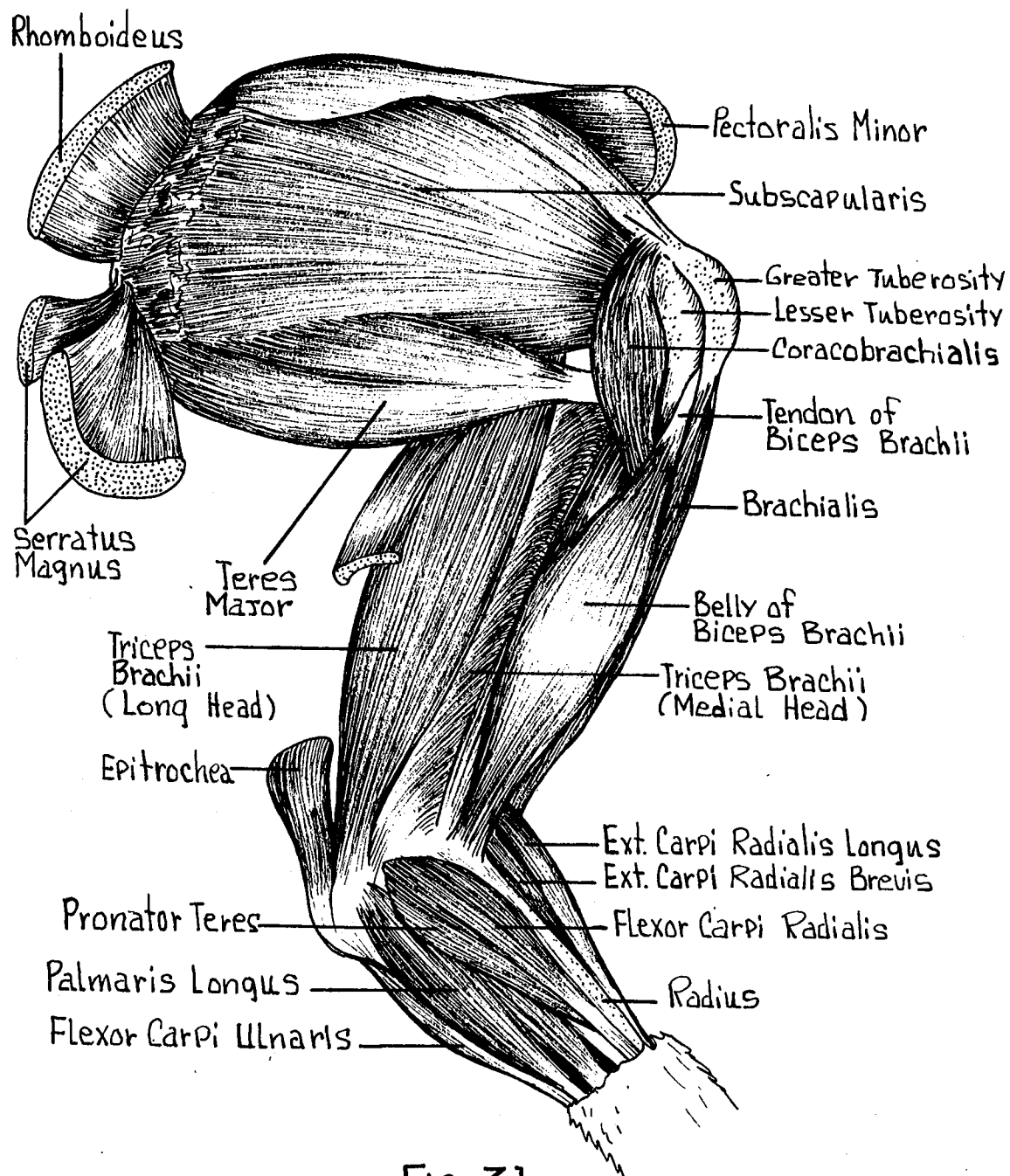


FIG. 31
ARM AND SHOULDER MUSCLES
 Medial View

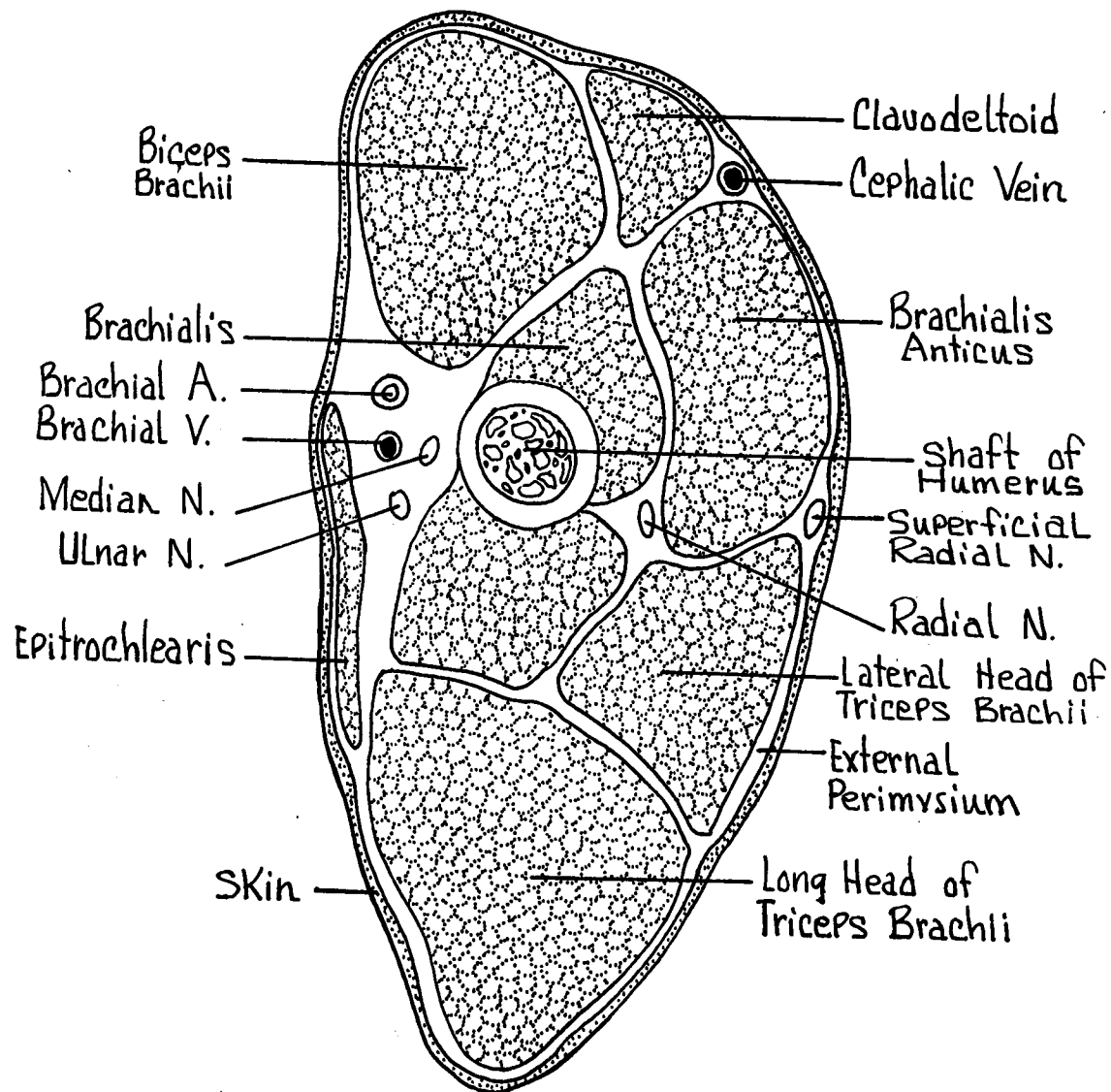


FIG. 32
 CROSS SECTION THROUGH
 MIDDLE OF HUMERUS

MUSCLES OF THE FOREARM - (Figs. 30, 31, 33)

Extensor Digitorum Communis - Lateral epicondyle of the humerus to the proximal end of the distal phalanges. Extends digits II-V.

Extensor Digitorum Lateralis - Lateral epicondyle of the humerus to the proximal end of the middle phalanges. Extends digits IV and V.

Extensor Carpi Ulnaris - Olecranon process of the ulna to the fifth metacarpal. Abducts and extends the carpals.

Extensor Carpi Radialis Longus - Supra-condylar ridge of the humerus to the proximal metacarpals II and III. Extends the carpals and metacarpals II-III.

Extensor Pollicis Brevis - Lateral shaft of radius to the first metacarpal. Extends and abducts the first digit.

Flexor Carpi Ulnaris - Olecranon process of the ulna to the pisiform bone. Flexes carpals.

Palmaris Longus - Medial epicondyle of the humerus to the palmar fascia. Tensor of palmar fascia.

Flexor Digitorum Sublimis - Medial epicondyle of the humerus to the proximal end of the middle phalanges. Flexes the carpals and phalanges II-V.

Flexor Digitorum Profundus - Medial epicondyle of the humerus to the proximal end of the distal phalanges. Flexes the carpals and phalanges I-V.

Flexor Carpi Radialis - Medial epicondyle of the humerus to the proximal third of the metacarpals. Flexes the carpals and pulls the third metacarpal towards the thumb.

Pronator Teres - Medial epicondyle of the humerus to the middle third of the medial surface of the radius. Pronator of the hand.

MUSCLES OF THE THIGH AND LEG - (Figs. 34, 35, 36)

Biceps Femoris - Arises by two heads.

Long Head - (Caput Longum) Ischial tuberosity of the innominate to the crural fascia. Extends the thigh and flexes the leg. Also may abduct the limb.

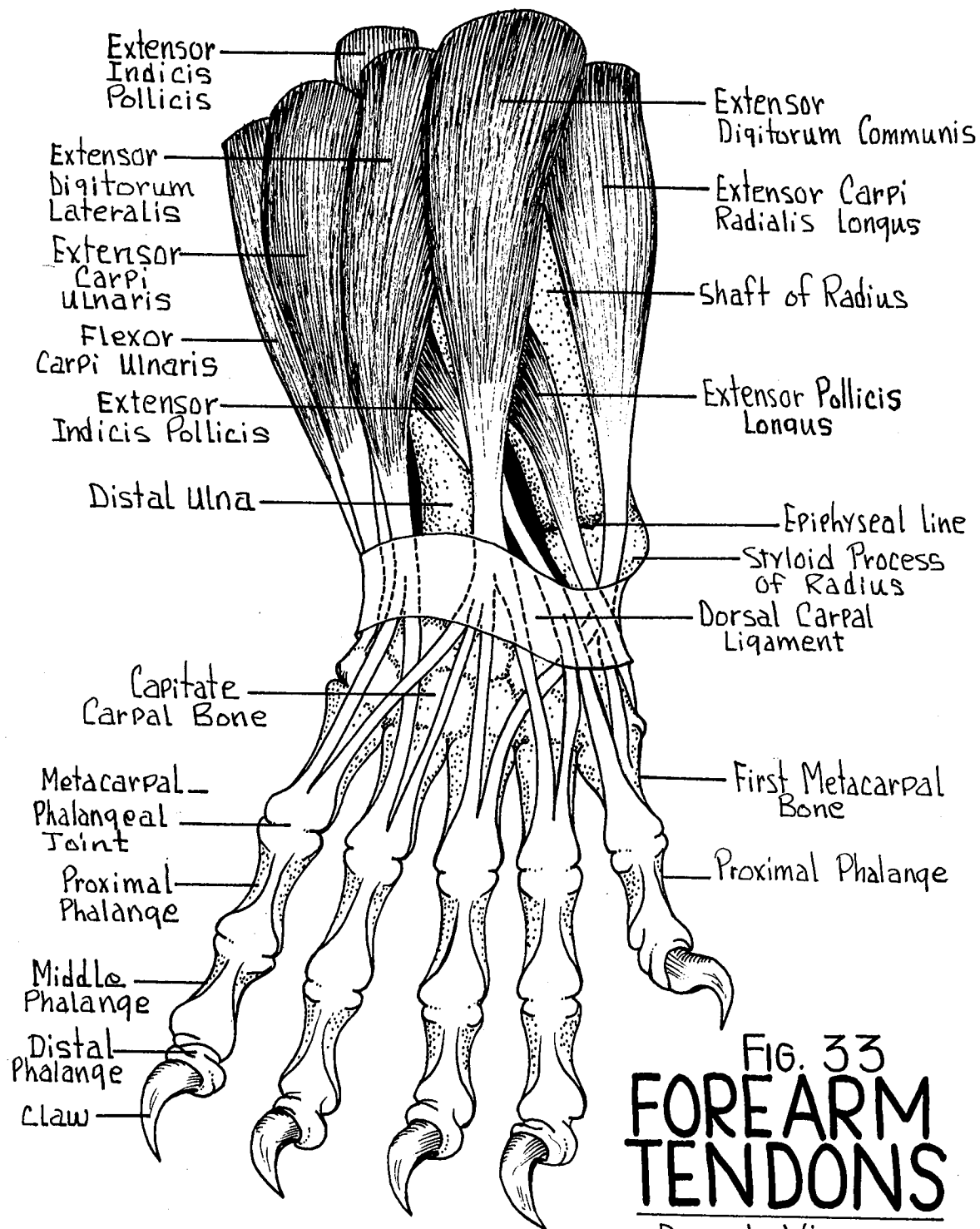


FIG. 33
**FOREARM
 TENDONS**

Dorsal View

Short Head - (Caput Brevis) Last sacral and first three caudal vertebral spines to the crural fascia. Extends the thigh and flexes the leg.

Tensor Fascia Latae - Ventral border of the ilium to the fascia lata. Makes tense the fascia lata.

Gluteus Maximus - Spines of the sacrum to the lateral trochanter of the femur. Abducts the thigh.

Gluteus Medius - Crest of the ilium and 1st sacral vertebrae to the greater trochanter of the femur. Abducts the thigh.

Sartorius - Inguinal ligament to the medial condyle of the tibia. Adducts and rotates the thigh.

Gracilis - Ventral Ischio-pubic symphysis to the crural fascia. Flexes the leg and adducts the thigh.

Tenuissimus - Slender. From the transverse processes of the second caudal vertebra to the crural fascia. Tenses the lateral crural fascia.

Semimembranosus - Ischial tuberosity to the crural fascia. Extends the thigh and abducts the leg.

Semitendinosus - Ischial tuberosity to the medial condyle of the femur. Extends thigh and flexes the leg.

Adductor Magnus - Lateral ventral pubis and ischium to the medial epicondyle of the femur and proximal end of tibia. Extends the leg and aids in propulsion.

Adductor Longus - Pubic symphysis and ischium to the distal half of the shaft of the femur. Adducts the leg and aids in propulsion.

Rectus Femoris - Inferior spine of the ilium to the shaft of the femur. Abducts the thigh and extends the leg.

Vastus Lateralis - Greater trochanter of the femur to the insertion of the rectus femoris muscle. Abducts thigh and extends the leg.

Vastus Intermedius - Greater trochanter of the femur to the patellar tendon and crural fascia. Abducts the thigh and flexes crural fascia.

Vastus Medialis - Proximal shaft of the femur to the patellar tendon and crural fascia. Abducts thigh and flexes crural fascia.

MUSCLES OF THE LOWER LEG - (Figs. 34, 35, 36)

Gastrocnemius - Lateral epicondyle of the femur to the tendon of Achilles. Extends the foot and aids in propulsion.

Soleus - Lateral epicondyle of the femur to the tendon of Achilles. Extends foot and aids in propulsion.

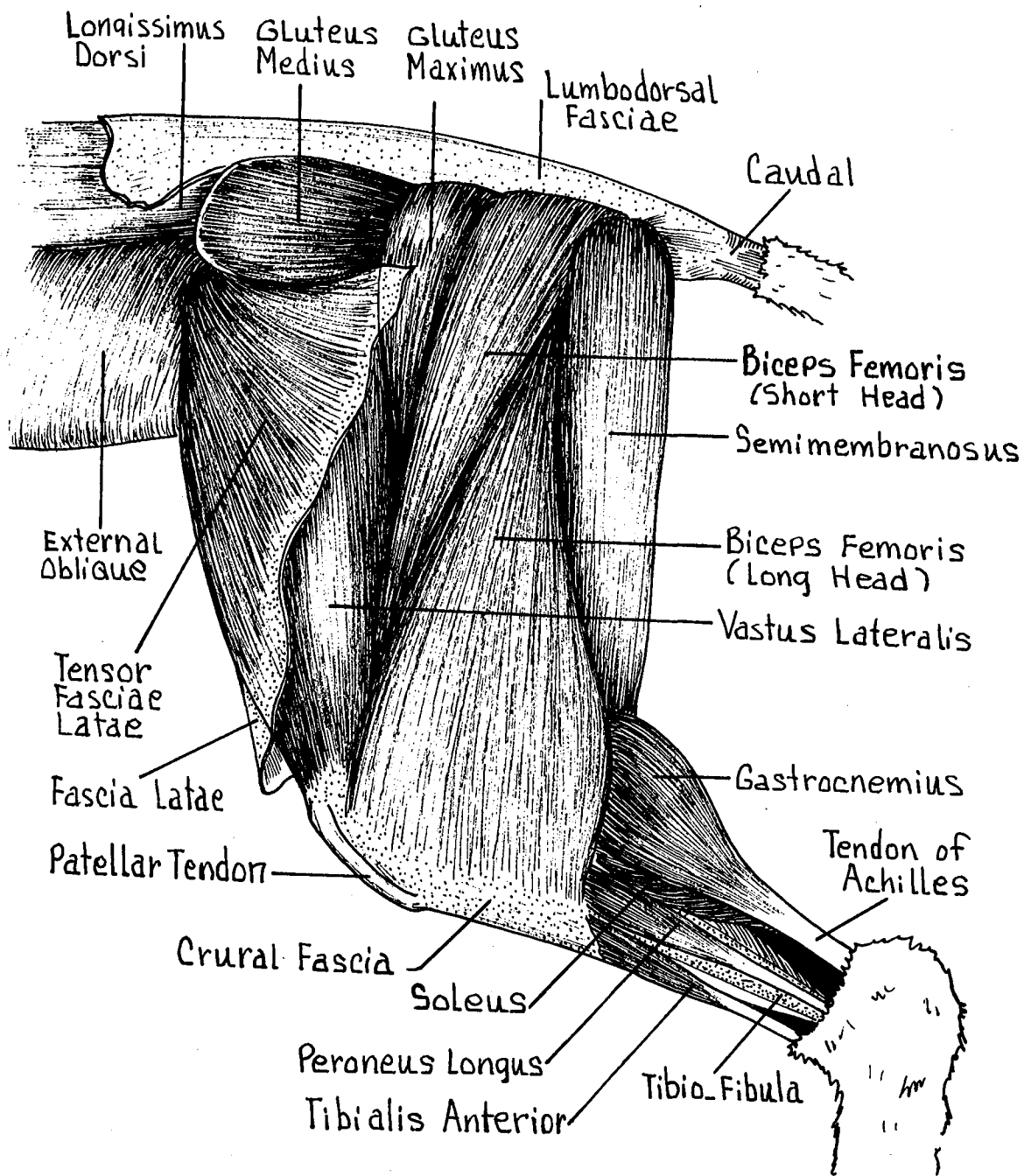


FIG. 34
THIGH AND LEG MUSCLES
 Lateral View - superficial Muscles

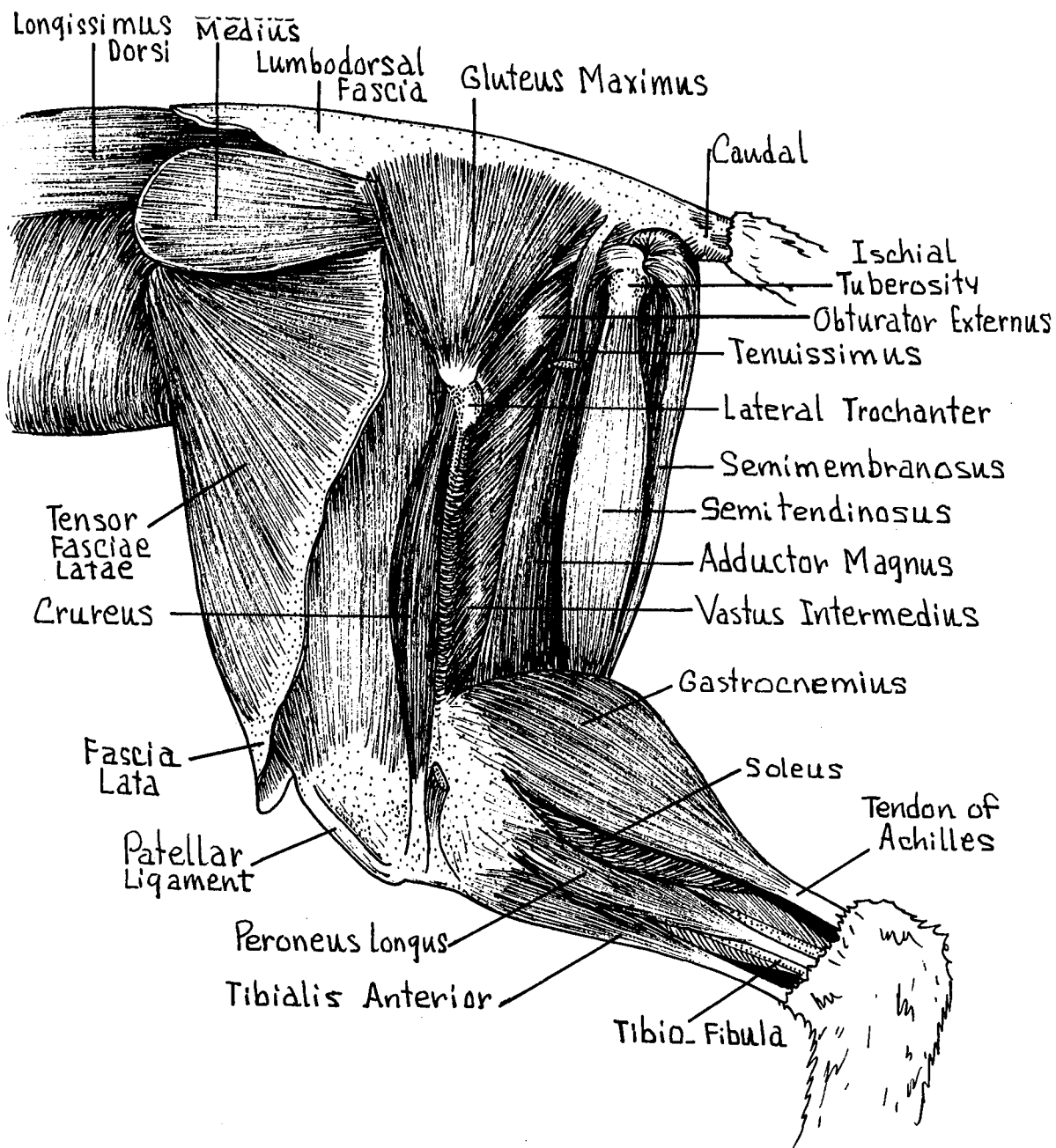


FIG. 35
THIGH AND LEG MUSCLES
 Lateral View - Deep Muscles

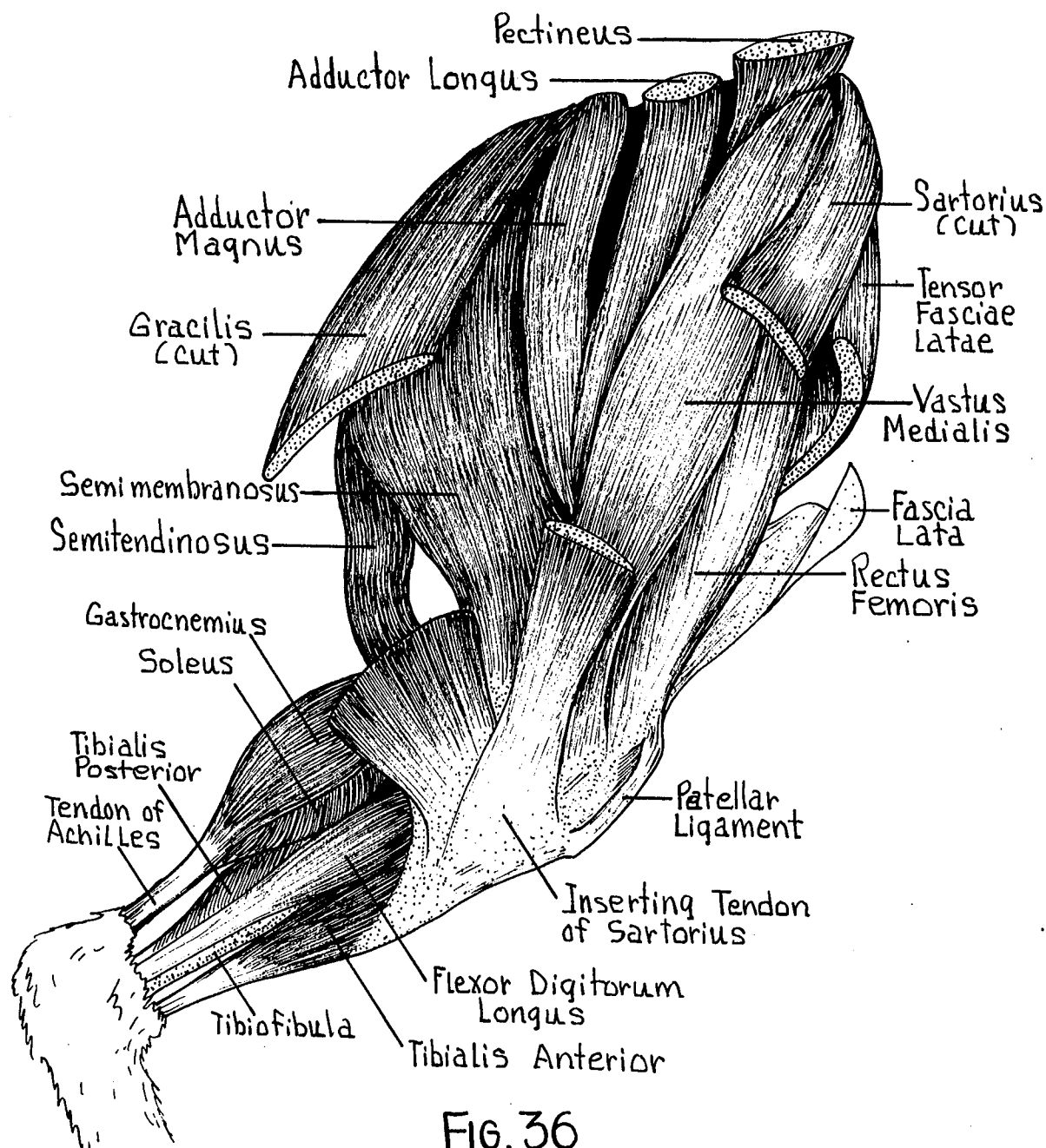


FIG. 36
THIGH AND LEG MUSCLES
 Medial View

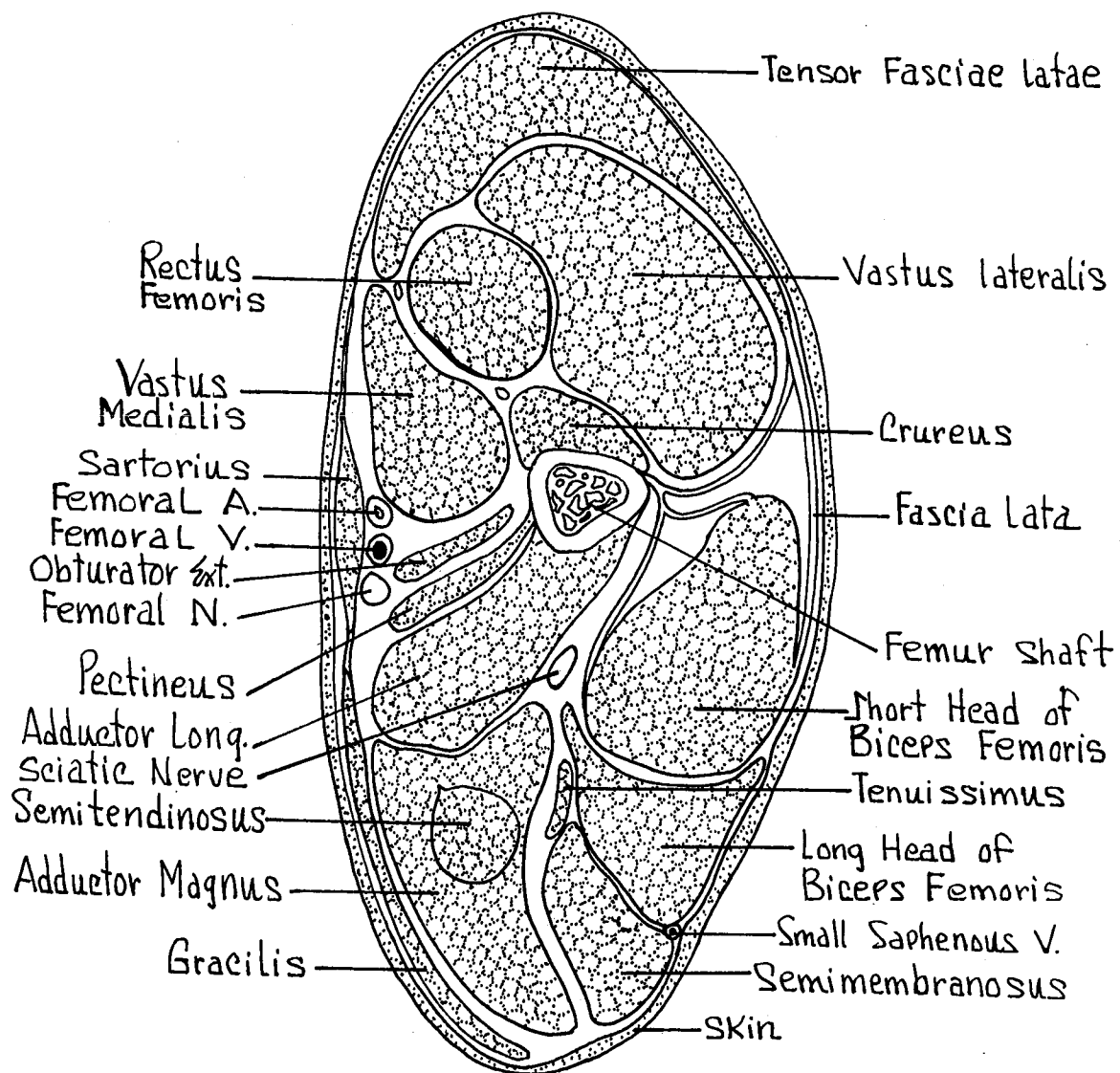


FIG. 37
**CROSS SECTION THROUGH
 MIDDLE OF FEMUR**

Tibialis Anterior - Lateral condyle and tuberosity of the tibia to the second metatarsal.

Flexes the foot mediad.

Flexor Digitorum Longus - Proximal end of the tibio-fibula to the proximal end of the distal phalanges. Flexes distal phalanges and extends foot.

Tibialis Posterior - Medial surface of the tibia to the proximal and middle phalanges of the second digit. Extends the foot and the second digit.

Extensor Digitorum Longus - Lateral epicondyle of the femur to the proximal end of the distal phalanges II-V. Flexes foot and extends the toes.

Plantaris - Lateral epicondyle of the femur to the tendon of Achilles. Extends the foot and aids in propulsion.

Peroneus Longus - Lateral condyle of the tibia to the proximal end of the second metatarsal. Everts and extends the foot.

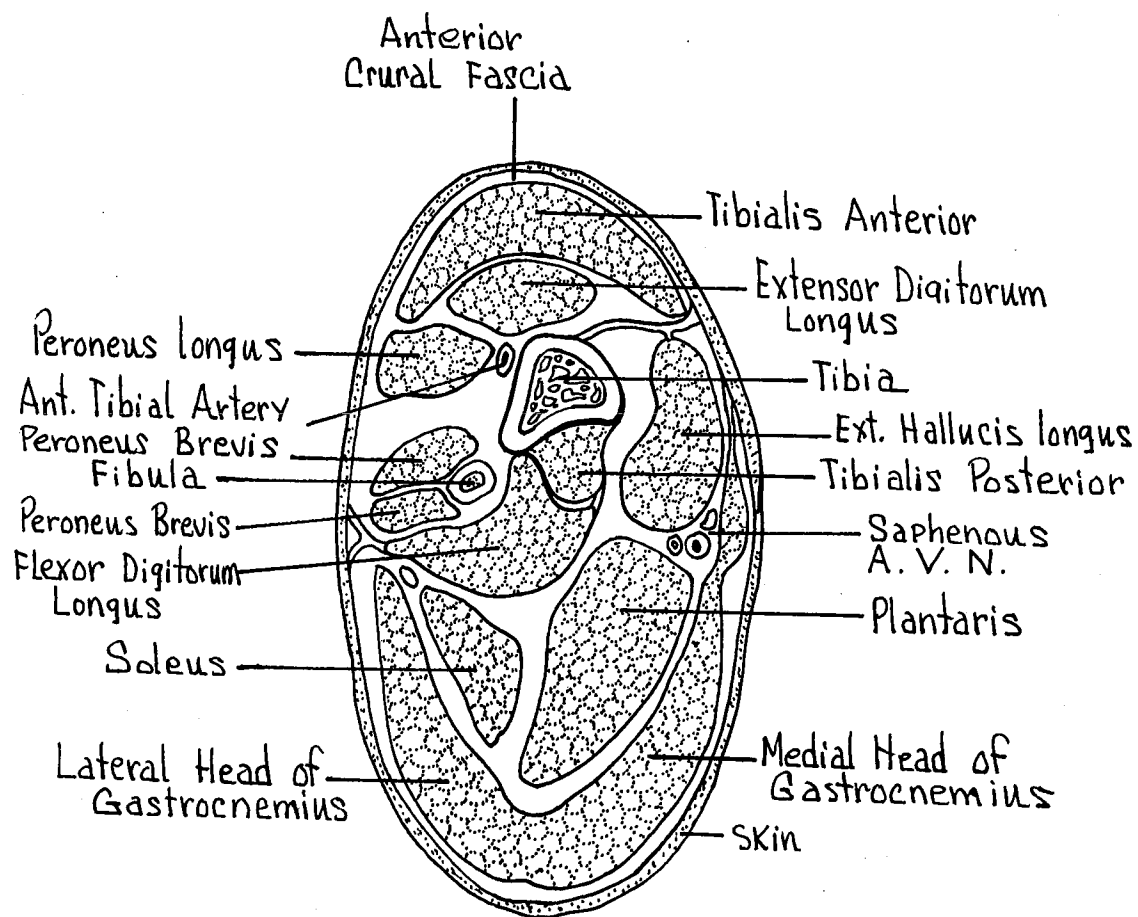


FIG. 38
CROSS SECTION THROUGH
 MIDDLE OF TIBIO-FIBULA

V. INTERNAL ORGANS

Figure 39

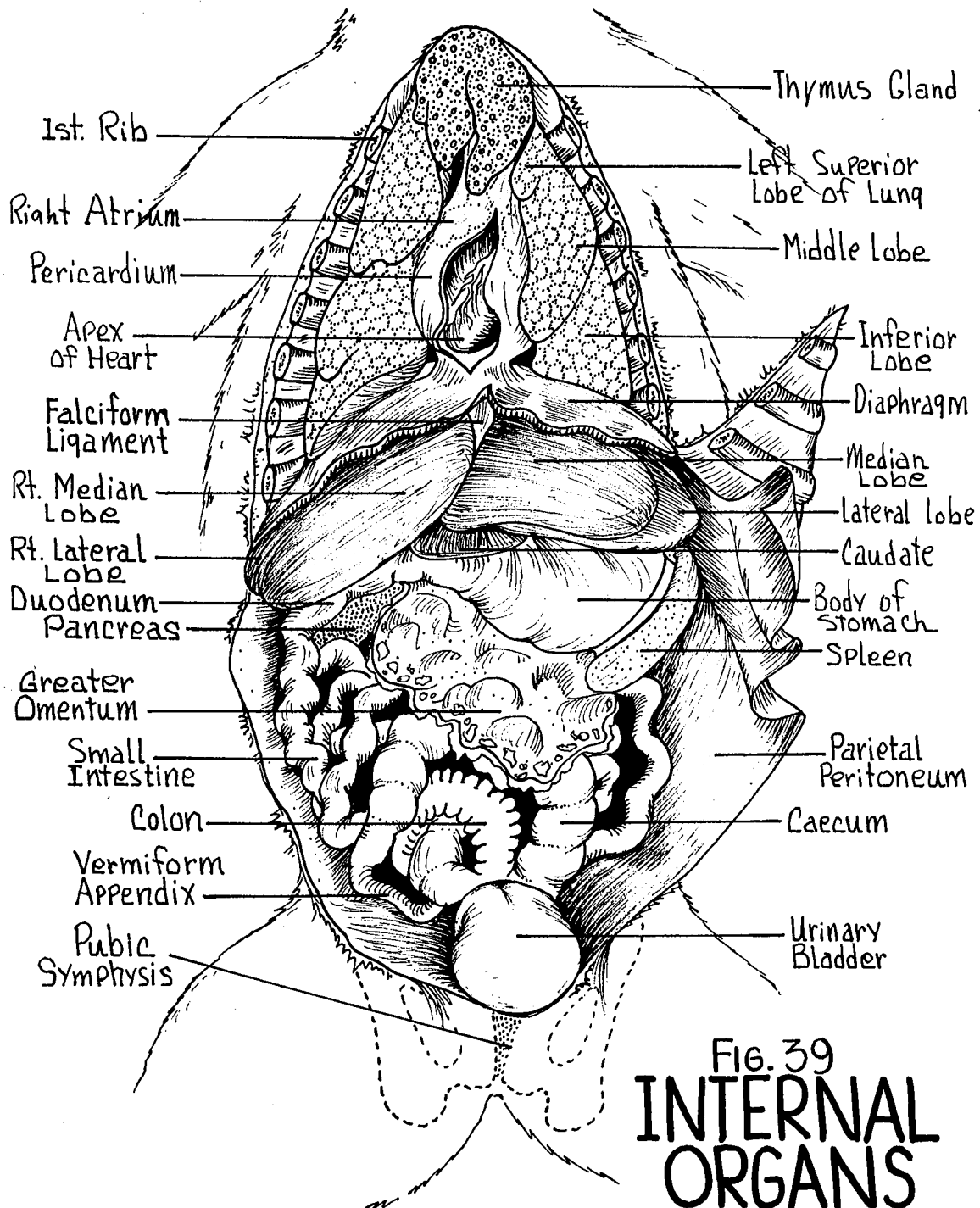


FIG. 39
**INTERNAL
 ORGANS**
 Anterior View

VI. RESPIRATORY SYSTEM

PHARYNX - Upper end of the digestive and respiratory tube.

Oropharynx - Posterior portion of oral cavity.

Nasopharynx - Region above the soft palate. Internal nasal aperture.

Laryngopharynx - Ventral posterior portion. Area leading to the larynx (voice box).

Openings into the pharynx are:

Oral Opening - From the mouth and oral cavity.

Nasal Opening - From the nasal cavity dorsal to the soft palate.

Glottis Opening - From the larynx and trachea. Guarded by the cartilaginous epiglottis.

Esophageal Opening - From the esophagus and digestive tract proper.

Eustachian Tube Opening - Paired. On the lateral walls. From the middle ear cavity.

LARYNX - "Voice box", formed by several cartilaginous segments.

Thyroid Cartilage - Large. Forming most of the ventral wall of the larynx.

Cricoid Cartilage - Smaller than the thyroid cartilage. Forms a complete ring extending around larynx posterior to thyroid cartilage.

Arytenoid Cartilages - Small, obliquely situated cartilages on the dorsal surface of the larynx, in the space anterior to the cricoid and dorsal to the thyroid cartilage.

Vocal Cords - Rudimentary vertical folds on the internal surface of the larynx.

THYROID GLAND - Bilobed endocrine gland located on the ventral junction of the larynx and trachea. Connected ventrally by a narrow isthmus.

TRACHEA - (Fig. 40) "Windpipe". Held open by a series of incomplete cartilaginous rings. Within the thoracic cavity, the distal portion of the trachea divides into right and left bronchi which penetrate the right and left lung lobes.

LUNGS - (Figs. 39, 40) Paired expansible structures, the surfaces of which are coated with a visceral peritoneal membrane. The lungs lie within the right and left pleural cavities.

Superior Lobe - Paired. Imperfectly developed on the left.

Middle Lobe - Paired. Intermediate lobes on both sides.

Inferior Lobes - Paired. On the right side, the inferior lobe is further subdivided into the medial and lateral lobules.

MEDIASTINUM - Potential space between the medial surfaces of the two pleural cavities. Contains primarily the pericardial cavity and heart.

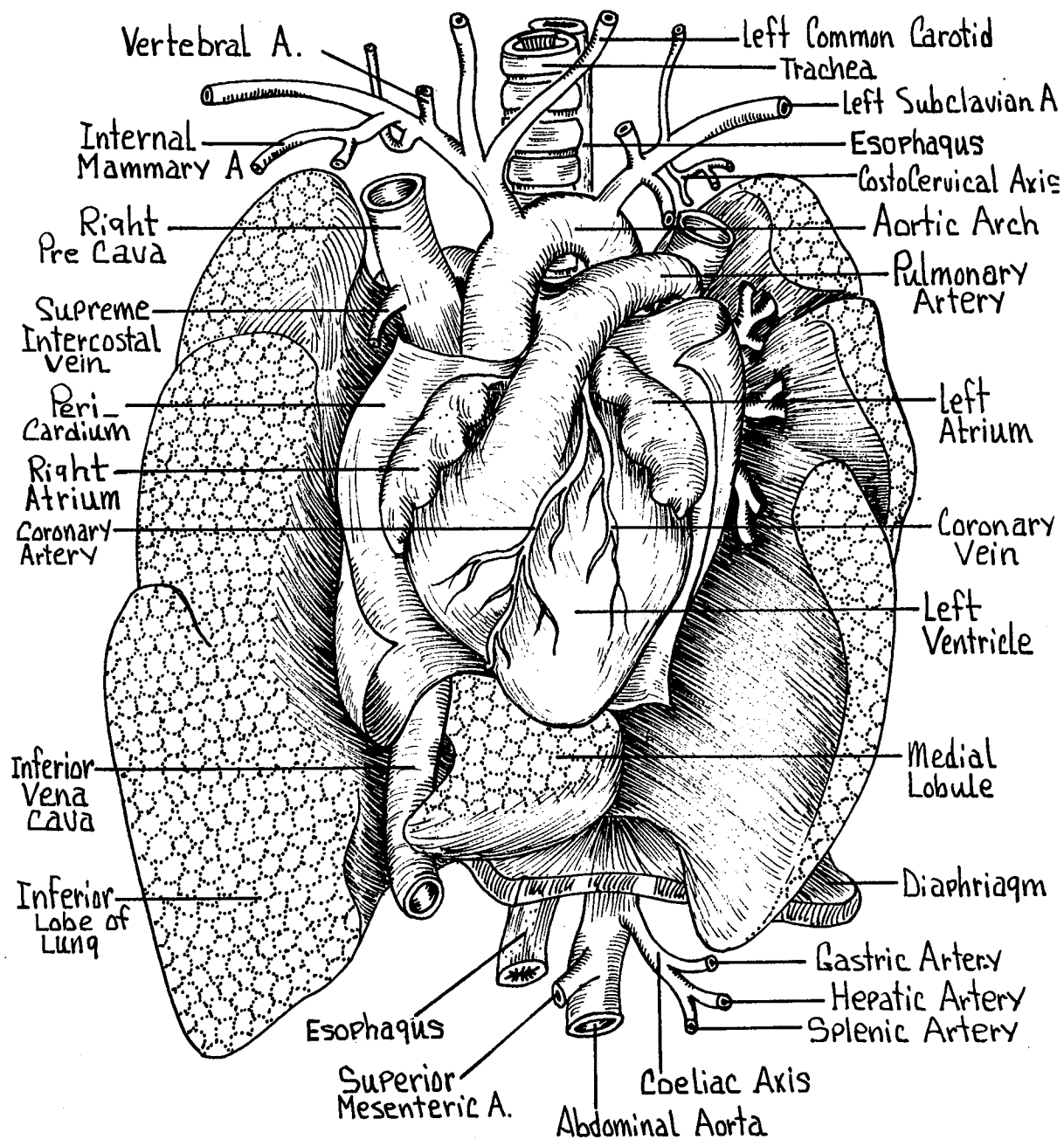


FIG. 40
THORACIC ORGANS
 Anterior View

VIII. HEART AND MAJOR VESSELS

THYMUS GLAND - (Fig. 39) Antero-ventral portion of the thoracic cavity. Irregular shaped gland. Larger in young specimen. Endocrine in function.

HEART - (Figs. 39, 40, 41, 42, 43) Lies within the mediastinal cavity. Four chambered tapering posteriorly to the apex.

Pericardium - Loose membranous sac surrounding the heart. Filled with pericardial fluid. Note its attachments to the great vessels and to the diaphragm.

External Features -

Atria - Right and left thin walled structures. Note the lateral extensions, auricles.

Ventricles - Right and left thicker walled structures. Posterior to the atria. The left ventricle being more massive and thicker walled than the right. Right and left sides divided by a superficially indistinct interventricular groove.

Coronary Arteries - Small arteries supplying the musculature of the heart. Arises from the base of the aorta.

Coronary Veins - Drains the musculature of the heart. Empties into the coronary sinus.

Thebesian Veins - Draining the same area, but empties directly into the heart chambers.

Internal Features -

Interatrial Septum - Dividing the anterior atrial chambers into right and left atria.

Interventricular Septum - Dividing the heavier walled ventricles into a right ventricle and a much heavier walled left ventricle.

Atrioventricular valves - 2 sets of double cusped valves closing the atrio-ventricular openings.

Chordae Tendineae - Slender cord-like structures attaching to the cusps of the atrio-ventricular valves.

Papillary Muscles - Thick muscular projections from the ventricular walls for the attachment of the chordae tendineae.

Trabeculae Carneae - Muscular ridges within the walls of the ventricles.

Semilunar Valves - 2 sets of three-cusped valves guarding the ventricular openings into the pulmonary trunk and ascending aorta.

Fossa Ovalis - Denoting the position of the closure of the embryonic foramen ovale, an opening between the atria.

MAJOR VESSELS - (Figs. 40, 41, 42, 43)

Aortic Arch - Formed by a looping of the aorta as it leaves the left ventricle.

Brachiocephalic Artery - (Innominate artery) First major branch from the arch. Gives rise to the right subclavian and right common carotid arteries. The left common carotid occasionally arises from this vessel.

Left Common Carotid Artery - Second branch arising very near the innominate.

Left Subclavian Artery - Third branch from the arch of the aorta. The aorta loops posteriorly and becomes the descending aorta.

Ligamentum Arteriosum - (Arterial ligament) Reminent of the foetal connection between the dorsal aorta and the pulmonary trunk, the ductus arteriosus.

Superior Venae Cavae - Paired. Right and left vessels formed by a juncture of the external jugular, internal jugular, and subclavian veins. They empty into the right atrium anteriorly. Drains the head, neck and upper extremities.

Inferior Vena Cava - Unpaired. Lying to the right of the dorsal aorta to pass into the right atrium. Drains the abdominal cavity and lower extremities.

Pulmonary Trunk - (Pulmonary Aorta) Single vessel running from the right ventricle anteriorly to branch into the right and left pulmonary arteries.

Pulmonary Artery - Paired. Formed by the bifurcation of the pulmonary trunk at the region of the ligamentum arteriosum. To the right and left lungs.

Pulmonary Veins - Two veins from each lung entering the left atrium caudo-dorsally.

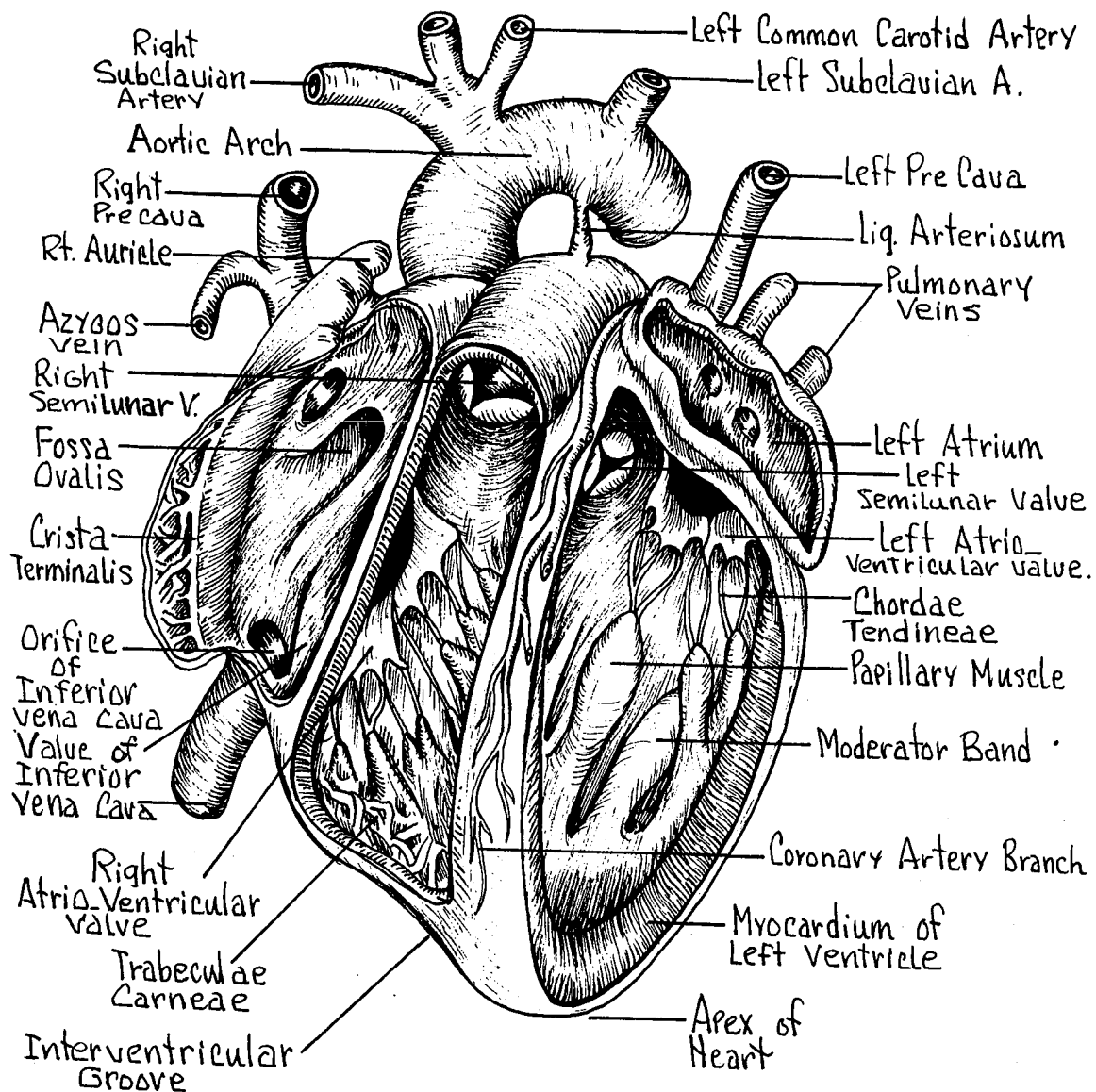


FIG. 41
HEART
 Anterior View

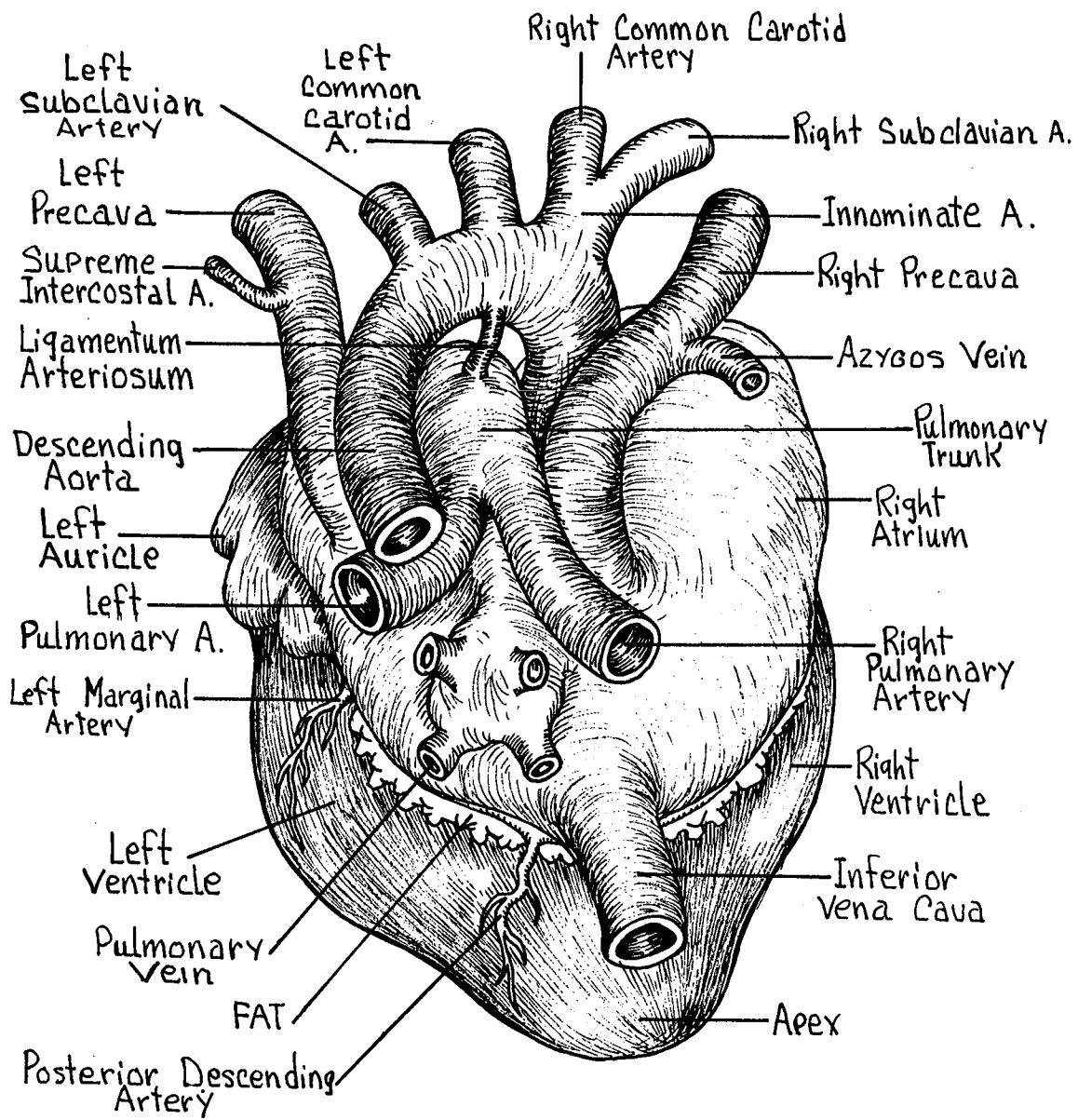


FIG. 42
HEART
 Dorsal View

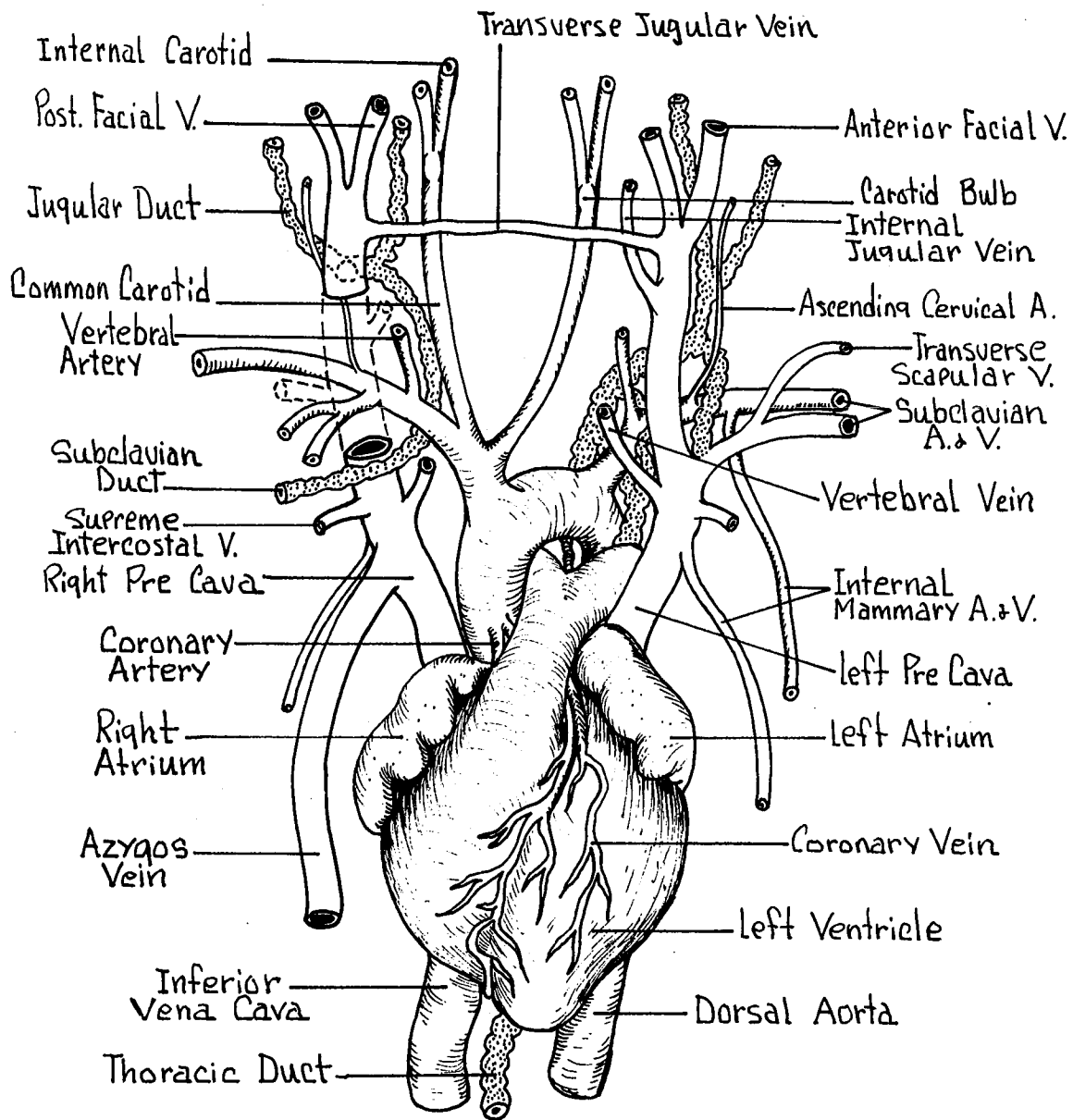


FIG. 43
**VESSELS OF THE
 NECK AND THORAX**

VIII. ARTERIAL CIRCULATION

ANTERIOR ARTERIES - (Figs. 43, 44)

Brachiocephalic - From the first part of the aortic arch.

Gives off the right subclavian and right common carotid arteries.

Subclavian - Arising independently from the aortic arch on the left side. From the Innominate on the right.

Internal Mammary - To the ventral chest wall.

Terminates as the superior epigastric artery.

Vertebral - Enters the foramen transversarium of the cervical vertebrae to supply the brain.

Supreme Intercostals - To the anterior intercostal spaces of the ribs.

Transverse Artery of Neck - To serratus ventralis muscle.

Ascending Cervical - Ascending the side of the neck.

Axillary - Passing in front of the first rib becomes the axillary artery.

Ventral Thoracic - To the median pectoral muscles.

Long Thoracic - Supplies the latissimus dorsi muscle and the deep pectoral muscles.

Subscapular - To teres muscle and other shoulder muscles.

Brachial - Continuation of the axillary into the arm region. Terminates as the radial and ulnar arteries.

Common Carotid - Passes along the lateral margins of the trachea in close association with the internal jugular vein and vagus nerve.

Superior Thyroid - To the anterior portion of the thyroid gland.

Muscular - Supplying the muscles of the neck.

Occipital - Passes deeply to the dorsal neck muscles.

Internal Carotid - Slender passes deep to the tympanic bulla and enters the cranial cavity to supply the brain.

External Carotid - Continuation of common carotid anteriorly to the head.

Lingual - Supplying the region of the tongue.

External Maxillary - Along the masseter to supply the lips and jaws.

Auricular - To the external ears or pinna.

Temporal - To the temporal region.

Internal Maxillary - Disappears internal to the masseter.

THORACIC ARTERIES - (Fig. 44)

Descending Aorta - (Thoracic Aorta) Dorsally located in the midline of the thoracic cavity.

Visceral Branches - Pericardial, bronchial, esophageal, and mediastinal arteries.

Parietal Branches - Intercostal arteries arising from the aorta segmentally to the intercostal spaces.

ABDOMINAL ARTERIES - (Fig. 44) Continuation of the dorsal aorta into the abdominal cavity passing dorsally to the diaphragm anterior to the vertebral column.

Visceral Branches - Major branches from the aorta supplying the abdominal viscera.

Coeliac Axis - First major branch off of the aorta after entering the abdominal cavity.

Hepatic - To the liver, pancreas, stomach, and duodenum.

Left Gastric - To the lesser curvature of the stomach. Small branches to the esophagus.

Splenic - By large branches to the spleen, pancreas, and greater curvature of the stomach.

Superior Mesenteric - Second major branch off of the abdominal dorsal aorta.

Middle Colic - To the transverse and descending colon.

- Posterior Pancreatico-Duodenal - To the posterior pancreas and the 1st segment of the duodenum.
- Ileocolic - To the ileum, caecum, and ascending colon.
- Intestinal - Numerous small branches to the small intestine.
- Inferior Mesenteric - Near the posterior part of the abdominal cavity.
- Left Colic - To the ascending colon.
- Superior Hemorrhoidal - To the descending colon and rectum.
- Adrenal - From the aorta or renal arteries to the right and left suprarenal glands.
- Genital - To the ovaries in the female (ovarian), or to the testes in the male (spermatic).
- Renal - To the kidneys. Entering near the hilus of the kidneys. The right renal commonly arises cranial to the left on the aorta.
- Parietal Branches - These branches from the abdominal aorta to the dorsal body wall.
- Phrenic - To the diaphragm. May arise from the coeliac axis near its origin.

Lumbar - Segmental branches from the aorta to the muscles of the anterior lumbar region.

Median Sacral - (Caudal) Posterior continuation of the dorsal aorta into the tail region. Arises from the dorsal posterior surface of the aorta.

Terminal Branches - At the posterior boundaries of the abdominal cavity the aorta bifurcates to send branches into the lower extremities, passing under the inguinal ligament.

Common Iliac - Two arteries branching from the terminal portion of the abdominal aorta to the extremities.

Iliolumbar - From the common iliac to the abdominal wall and cutaneous maximus muscle.

External Iliac - Continuation of the common iliac into the femoral region passing under the inguinal ligament.

Femoral - To the posterior limbs.

Superficial Epigastric - Along the body wall to anastomose with a branch of the long thoracic.

Inferior Epigastric - Passes cranial from the external iliac to anastomose with branches of the internal mammary artery.

Internal Iliac - (Hypogastric) Arises from the common iliac lying against the dorsal wall. To pelvis and thigh.

Umbilical - To the urinary bladder.

Middle Hemorrhoidal - To the rectum.

MAJOR LYMPHATIC VESSELS - (Fig. 43)

Thoracic Duct - Lies just dorsal to the dorsal aorta.

Drains all the lymph from the abdominal region, abdominal viscera, and posterior extremities. The thoracic duct empties into the left subclavian vein at its junction with the left external jugular.

Right Lymphatic Duct - Collects lymph from the right anterior quarter of the body.

Empties into the right external jugular vein.

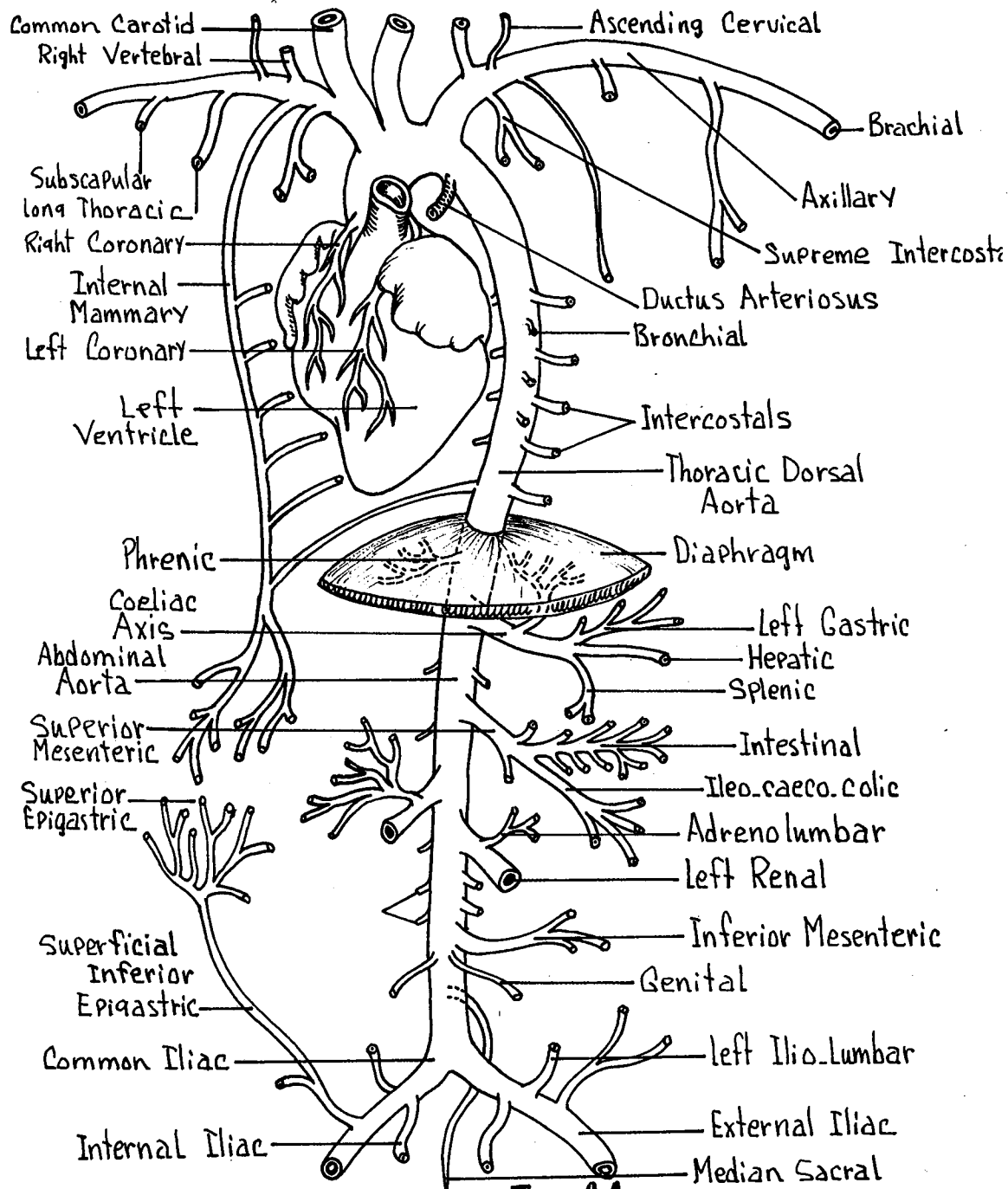


FIG. 44
AORTIC BRANCHES

IX. VENOUS CIRCULATION

ANTERIOR VEINS - (Figs. 40, 43, 45)

Superior Venae Cavae - (Pre Cavae) Paired. Enters right atrium. Drains the anterior limbs and head and neck region.

Azygos - Empties into the right precava only.
Unpaired. Formed in the mid-dorsal line by the intercostal veins. Drains the parietal region of the thoracic cavity.

Internal Mammary - From the thoracic and abdominal wall. Lateral to the mid-ventral line. Terminates as the superior epigastric vein.

Supreme Intercostal - Empties into the precava near the heart. The right branch emptying cranial to, or with, the azygos vein.

Vertebral - Empties into the precava anteriorly from the foramen transversarium of the cervical vertebrae. Drains the cranial cavity.

Subclavian - Unites with the external jugular to enter the precava. Drains the shoulder and upper extremities. Formed by the brachial and axillary veins.

External Jugular - From the anterior head region.

Internal Jugular - Drains the brain and cranial cavity. Runs along side of the trachea in close relationship to the common carotid artery and vagus nerve.

Transverse Jugular - Transverse vein connecting the right and left external jugular veins.

Anterior Facial - From the jaws and face.

Posterior Facial - From the external ear, pinna.

POSTERIOR VEINS - (Fig. 45)

Inferior Vena Cava - (Post Cava) Unpaired. Enters the right atrium posteriorly after penetrating the diaphragm into the thoracic cavity. Lies to the right of the dorsal aorta.

Phrenic - Drains the diaphragm. Enters the post cava as it passes into the thorax.

Hepatic - Single vein from the liver to the post cava.

Adrenolumbar - Paired. Drains the suprarenal glands.

Renal - Paired. The right renal entering the post cava more cranial to the left.

Genital - Ovarian or spermatic from the gonads.

Lumbar - From the muscles anterior to the ilio-lumbar veins.

External Iliac - Paired. Two large tributaries from the lower extremities which empty into the post cava.

Vesical - From the urinary bladder.

Inferior Epigastric - From the ventral body wall.

Anteriorly it terminates as an anastomoses with the internal mammary vein.

Femoral - Main vein of the thigh. Drains the external genitalia and muscles of the thigh.

Deep Femoral - Drains the deeper muscles of the thigh.

Internal Iliac - (Hypogastric) From the pelvic region.

Median Sacral - (Caudal) Drains the sacrum and tail.

Middle Hemorrhoidal - From the region of the anus.

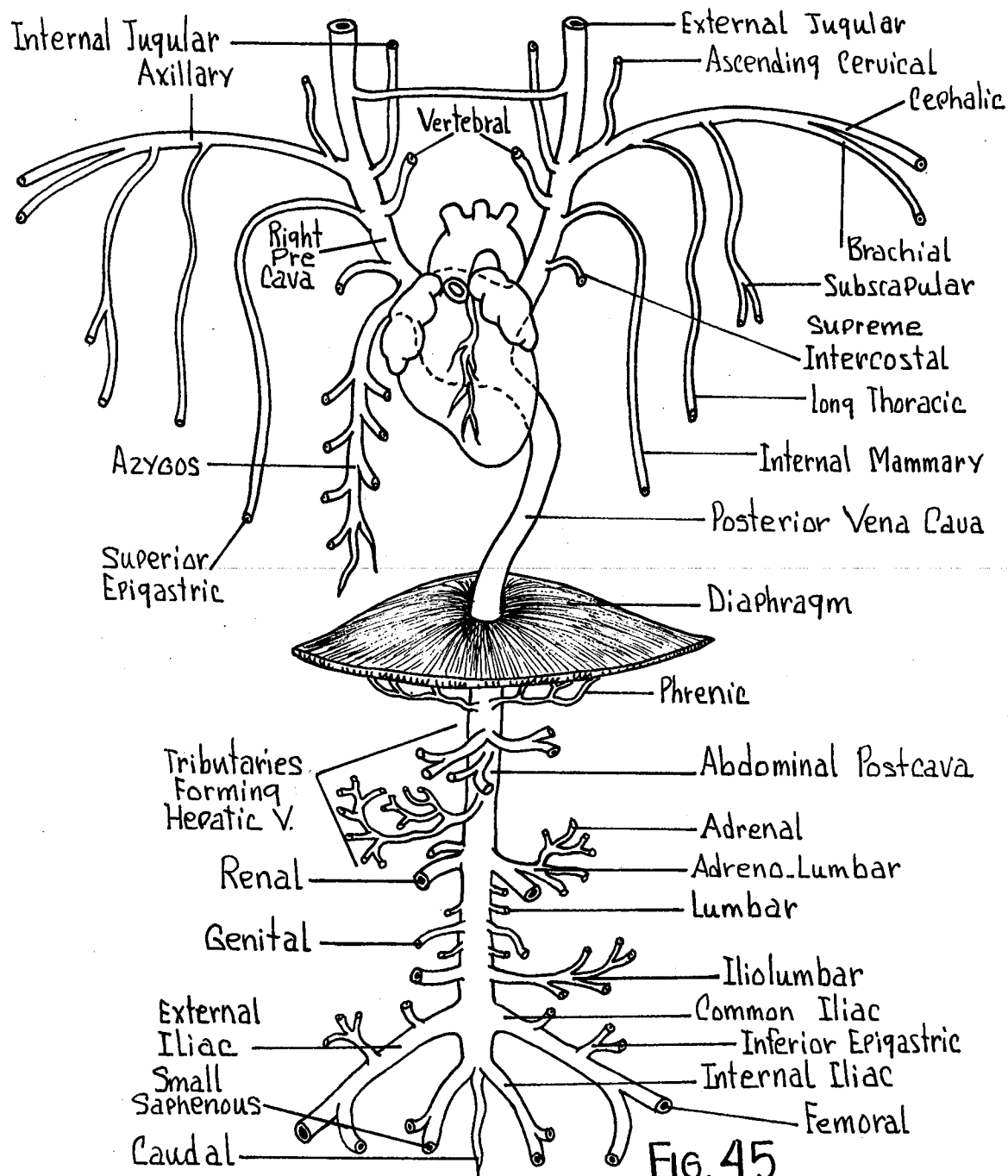


FIG. 45

VENAE CAVAE TRIBUTARIES

X. HEPATIC-PORTAL CIRCULATION

HEPATIC-PORTAL VEIN - (Fig. 46) Empties into the liver.

Gastrooduodenal - Formed by the right gastroepiploic and the anterior pancreaticoduodenal veins.

Drains the pancreas, duodenum, and portions of the pyloric stomach.

Gastrosplenic - Formed by the following veins.

Splenic - From the spleen and left gastroepiploic veins of the stomach and omentum.

Coronary - From the lesser curvature of the stomach.

Posterior Pancreaticoduodenal - Collects from the pancreas and duodenum.

Inferior Mesenteric - From the transverse, descending colon and rectum.

Superior Mesenteric - From all other intestinal regions.

Intestinal - Collects all areas of small intestine.

Ileoceocolic - From the ileum, appendix, caecum, and ascending colon.

Appendicular - From the vermiform appendix.

Anterior Ileocecal - From the sacculus rotundus.

Posterior Ileocecal - From the distal caecum, ileum, and ascending colon.

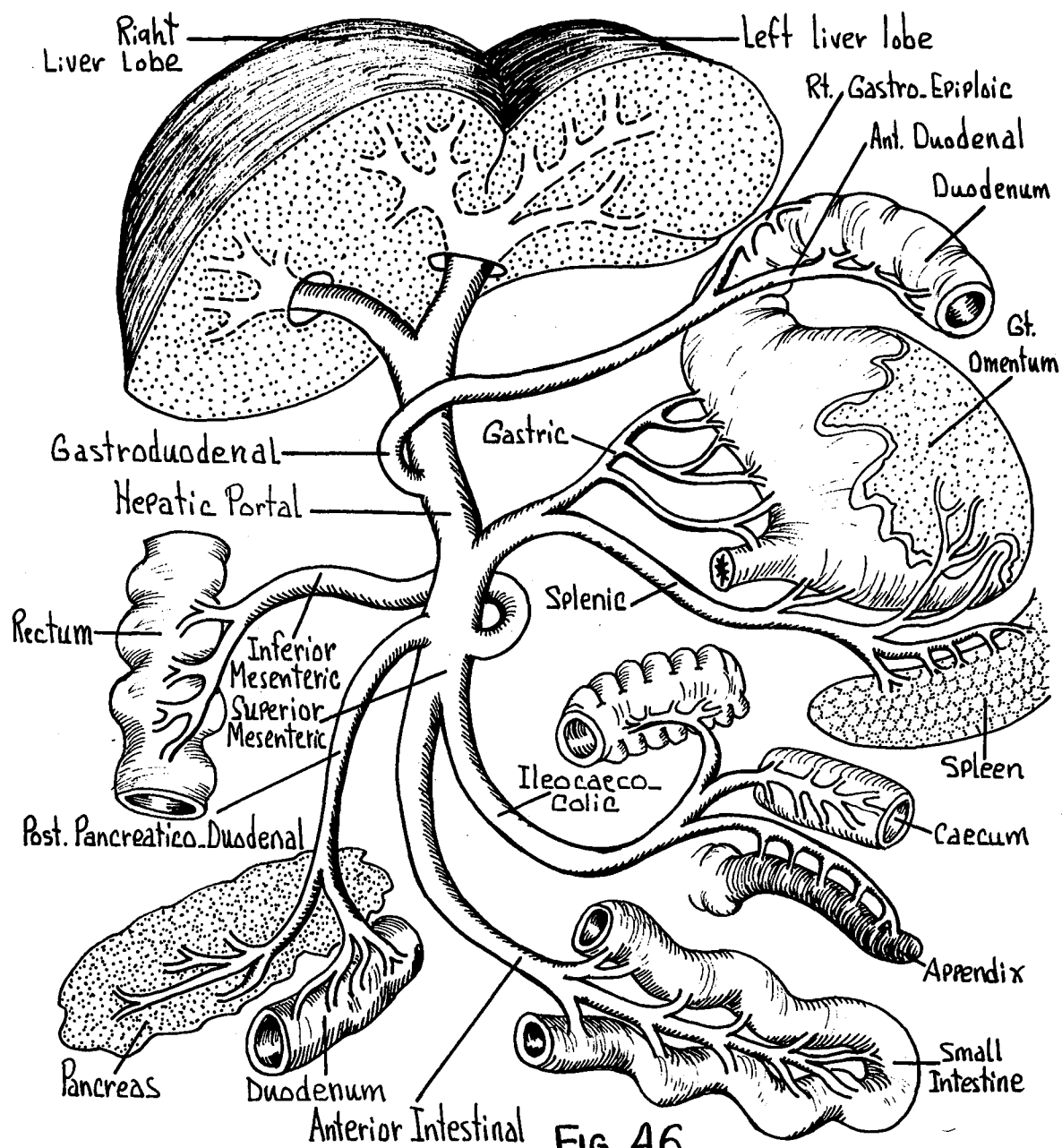


FIG. 46
HEPATIC-PORTAL SYSTEM
 Semi-Diagrammatic

XI. DIGESTIVE SYSTEM

SALIVARY GLANDS - The oral digestive glands. Paired.

Parotid Gland - Large diffusely situated gland ventral to the pinna. Drained by the parotid duct (Stenson's), passing over the lateral surface of the masseter to the oral cavity.

Submaxillary Gland - Ventral to the parotid gland and somewhat smaller in size. Drained by the submaxillary duct (Wharton's).

Sublingual Gland - Approximately the same size as the submaxillary gland. Lies cranial to it. The sublingual duct joins the submaxillary duct to enter the oral cavity as a single aperture.

TEETH - Total number of 28 in the adult. Composed of three types; incisors, premolars, and molars. Dental formula -
$$\begin{array}{cccc} 2 & 0 & 3 & 3 \\ \hline 1 & 0 & 2 & 3 \end{array}$$

TONGUE - A large muscular organ attached by muscles to the hyoid apparatus and bears numerous taste buds. The tongue covers the floor of the oral cavity. Attached anteriorly to the floor of the oral cavity by a median fold, the frenulum.

PHARYNX - Posterior oral cavity leading to the esophagus. Note the paired palatine tonsils in this region.

ESOPHAGUS - Muscular tube connecting the posterior pharynx with the stomach. Lies dorsal and to the left of the trachea.

STOMACH - (Fig. 39) Muscular sac which lies within the abdominal cavity at an obliquely transverse angle. Situated towards the left of the midline. Anterior part partially covered by left lobes of the liver.

Greater Curvature - Long posterior curved surface.

Lesser Curvature - Shorter anterior curved surface.

Cardiac Stomach - Proximal portion of the stomach into which the esophagus empties. Note the cardiac sphincter valve in this region.

Fundus of the Stomach - Large bulge at the antero-lateral region of the stomach near the cardiac stomach.

Body of the Stomach - Central portion of the stomach between the pyloric and fundic areas.

Pyloric Stomach - Distal most portion of the stomach which empties into the first portion of the duodenum. Note the pyloric sphincter valve.

GREATER OMENTUM - A thin sheet of peritoneum extending from the greater curvature of the stomach to cover the coils of the intestine. Usually containing deposits of fat.

LESSER OMENTUM - Portion of ventral mesentery between the stomach, duodenum, and liver. Composed of a gastrohepatic and a duodenohepatic omentum.

SMALL INTESTINE - (Fig. 39)

Duodenum - First portion of the small intestine following the pyloric valve. Entering the wall of the duodenum is the common bile duct from the liver, and more posteriorly the pancreatic duct.

Jejunum - About one-half of the remaining length of the small intestine beyond the duodenum.

Ileum - The remaining length of the small intestine to the ileocecal junction. Not sharply differentiated from the jejunum.

COMMON BILE DUCT - Small duct formed by the union of the hepatic ducts from the liver and the cystic duct from the gall bladder. Enters the first portion of the duodenum on the dorsal surface.

ILEOCECAL JUNCTION - (Fig. 48)

Ileum - Terminates as the ileocecal valve. Note the dilation in this region, the sacculus rotundum.

Caecum - Thin walled, very large and dilated diverticulum containing a spiral valve. The caecum terminates in an elongated slender vermiform appendix.

LARGE INTESTINE - (Figs. 39, 48) Often referred to as the colon. A continuation from the region of the sacculus rotundum.

Ascending Colon - The first part of the large intestine.

Haustra - Small sacculations on the surface of the first part of the colon.

Taenia - Longitudinal bands of muscle separating the haustra in the 1st part of the colon.

Transverse Colon - Short segment running from the ascending colon to the left.

Descending Colon - Continuation of the colon posteriorly terminating in the midline as the rectum.

Rectum - Terminal portion of the large intestine.

Anus - External posterior opening of the digestive tract.

DIGESTIVE GLANDS - (Figs. 39, 47) All are within the abdominal cavity.

Liver - Anterior most position within the abdominal cavity.

Anterior Lobes - Paired. Right and left sides separated by the falciform ligament.

Posterior Lobes - Paired. Caudad to the anterior lobes.

Caudate Lobe - Unpaired. Independent lobe caudad to the base of the posterior left lobe.

Gall Bladder - Spherical structure imbedded in the posterior surface of the right anterior liver lobe. Thin walled.

Pancreas - Diffuse mass of glandular tissue throughout the mesentery in the region of the duodenum. The pancreatic duct is small and enters the duodenum at a distance posterior to the entrance of the common bile duct.

SPLEEN - (Figs. 39, 46) Brownish elongated gland lying posterior and dorsal to the greater curvature of the stomach. An organ belonging to the circulatory system.

LYMPHATIC TISSUES - (Fig. 48)

Pancreas Aselli - Mesenteric lymph nodes along the course of the superior mesenteric artery.

Peyer's Patches - Lymphatic nodules along the dorsal walls of the intestine.

Sacculus Rotundus - Lymphoid patch at the terminal end of the ileum near the ileocecal valve.

Tonsilla Ileocecalis Major - A large intestinal lymphoid patch within the wall of the caecum. Dorsocaudad to the ileocecal valve.

Tonsilla Ileocecalis Minor - Intestinal lymphoid patch within the wall of the caecum. Dorsocranial to the ileocecal valve.

Vermiform Appendix - Terminal end of the caecum. An elongated diverticulum which is lymphoid in function.

DIAPHRAGM - (Fig. 39) Forming the division between the thoracic and abdominal cavities. A muscular partition with a central tendon. Perforated by the inferior vena cava and the esophagus. Respiratory in function.

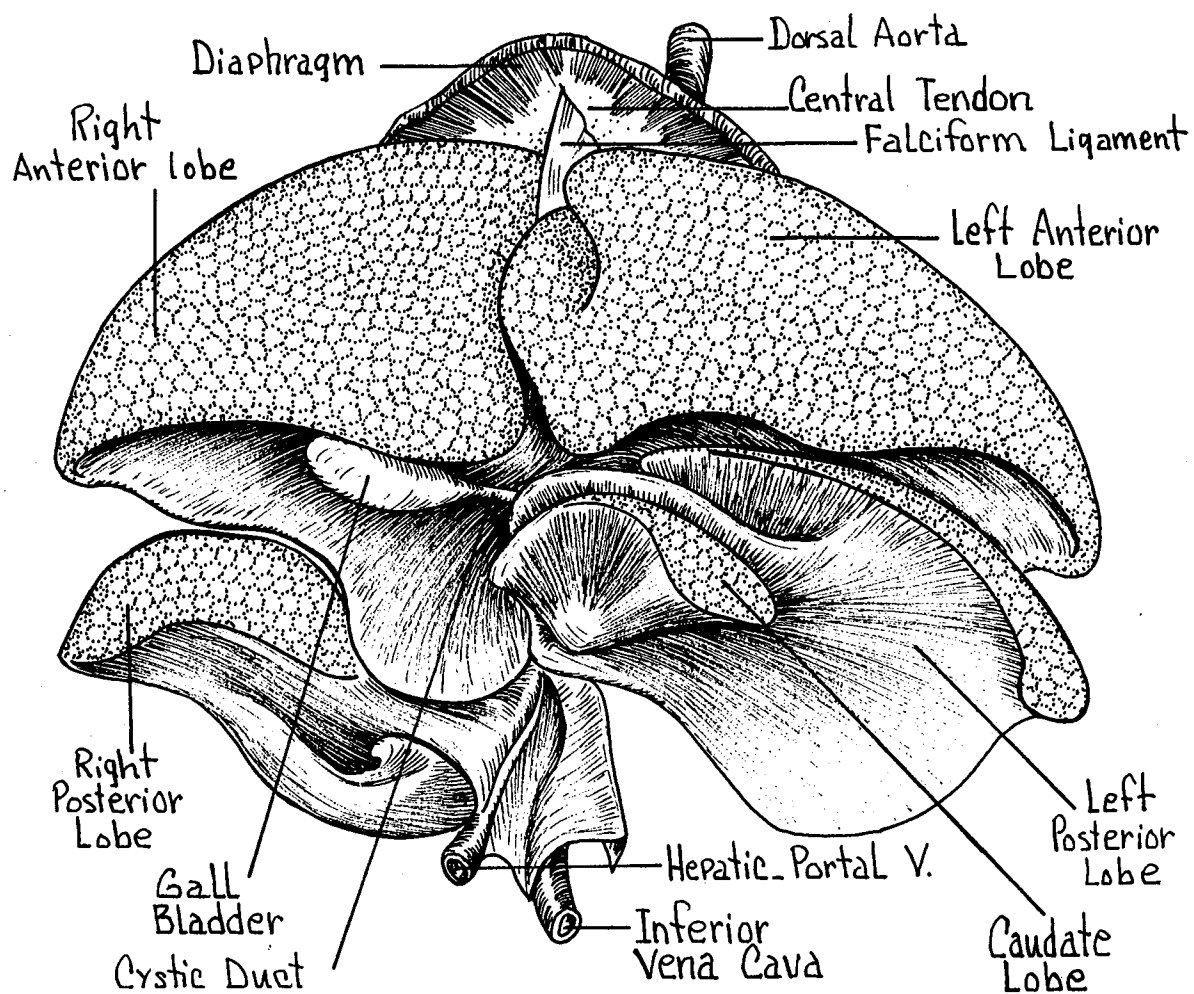


FIG. 47
LIVER
Anterior View

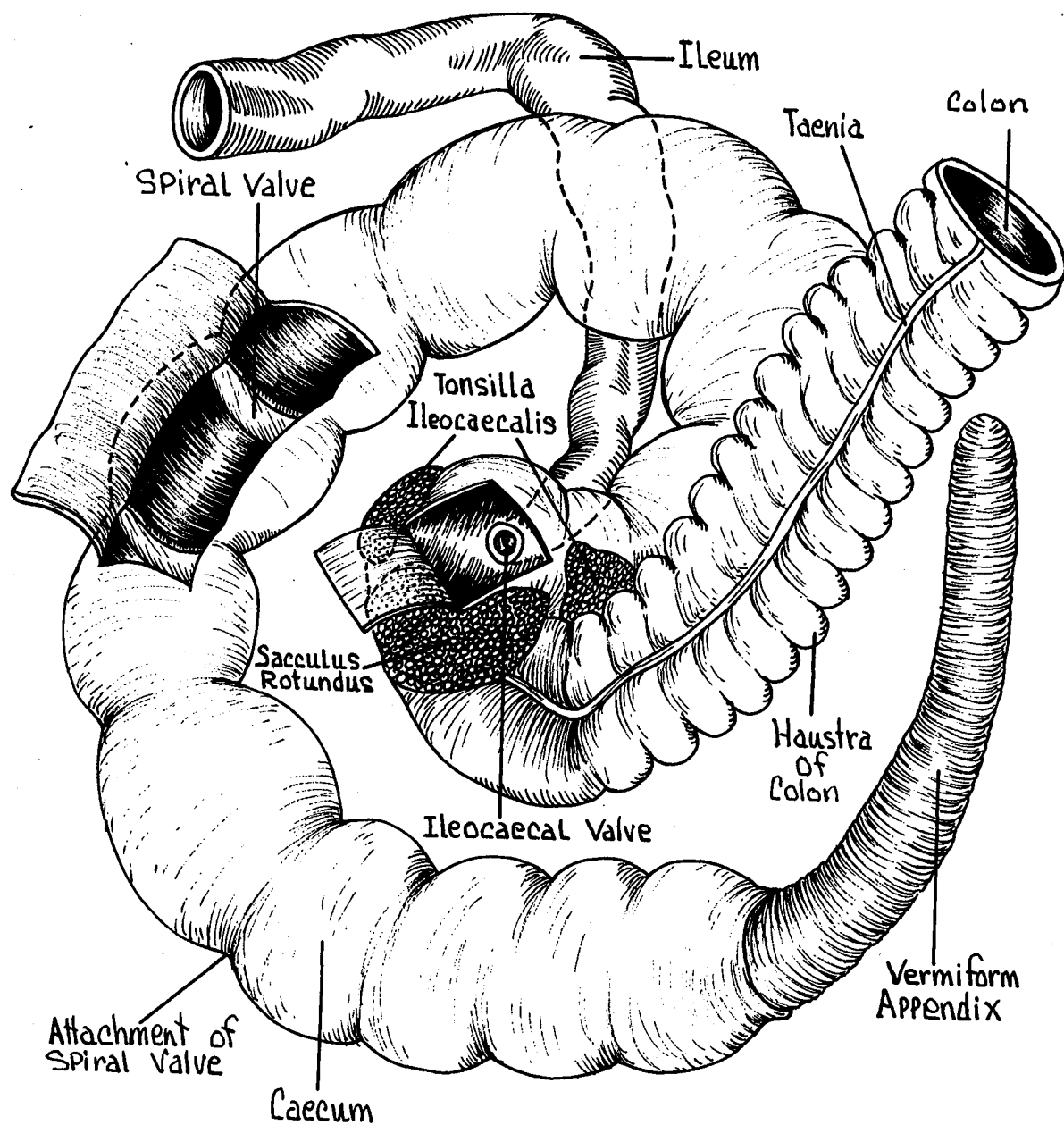


FIG. 48
ILEOCAECAL JUNCTION

XII. UROGENITAL SYSTEM

URINARY ORGANS - (Figs. 49, 50)

Kidneys - Paired. Located dorsally, the right kidney being more anterior than the left. Imbedded in fat.

Capsule - Fibrous coat immediately surrounding the external surface of the kidney.

Renal Hilus - Median concavity. Note the ureter, renal artery, and renal vein entering or leaving this area of the kidney.

Cortex - Narrow peripheral substance of the kidney as seen in a longitudinal section.

Medulla - Medial central portion of the kidney, including the renal papilla. Characterized by the radial striations.

Renal Pelvis - Enlarged funnel-like proximal end of the ureter within the kidney mass near the hilus region.

Renal Papilla - Projection of the medullary substance into the renal pelvis.

Ureter - The major duct from the kidney passing posteriorly to the base of the bladder.

Urinary Bladder - Ventro-posterior portion of the abdominal cavity. Muscular sac.

Urethra - Narrow tube from bladder to external opening.

SUPRARENAL GLAND (Adrenal) - Paired anterior to the kidneys.

An endocrine gland.

MALE REPRODUCTIVE ORGANS - (Fig. 49)

Testes - The male reproductive gland. Within the scrotal sacs, on the outside of the body wall, ventral and anterior to the anus.

Epididymis - First portion of the male reproductive duct.

Caput Epididymis - The enlarged anterior region.

The vas efferens empties into this duct from the testis.

Cauda Epididymis - The posterior constricted area along the medial side to the posterior region of the testis.

Vas Deferens - The major genital duct of the male. Passes from the posterior end of the testis into the abdominal cavity through the inguinal canal terminating in the urethra.

Prostate Gland - At the point of juncture of the vas deferens with the urethra, a white massive gland.

Seminal Vesicle - Located on the dorsal surface of the base of the bladder. Vas deferens enters ventrally.

Bulbourethral Gland - Dorsal wall of urethra behind the prostate gland.

Penis - Anterior and ventral to the scrotal sacs. Posteriorly directed. Attached to the ischium by the crus penis.

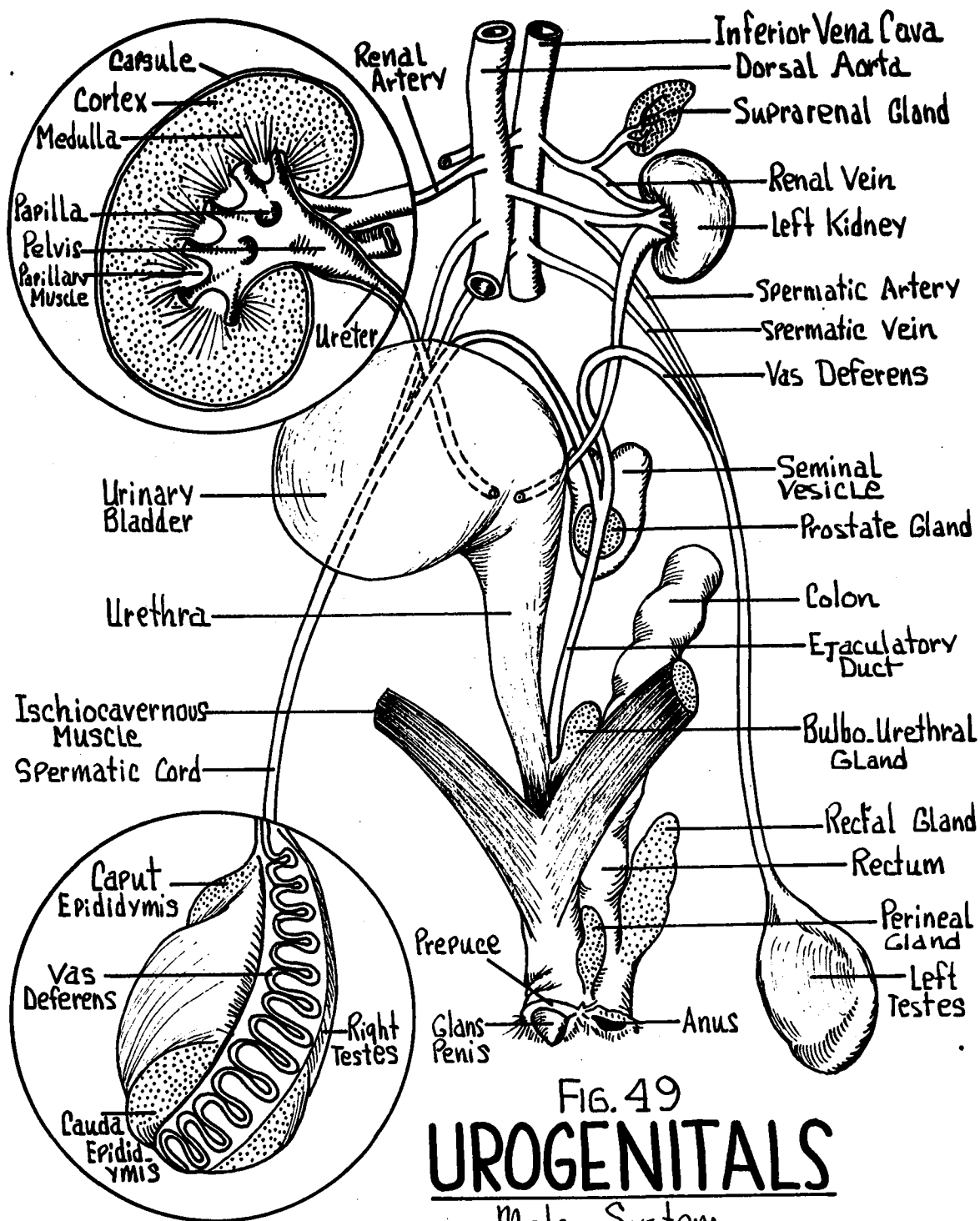


FIG. 49
UROGENITALS
 Male System

FEMALE REPRODUCTIVE ORGANS - (Fig. 50)

Ovaries - Small paired bodies along the dorsal body wall, posterior to the kidneys. The reproductive gland of the female. Supported along the dorsal wall by the mesovarium, a peritoneal fold.

Ostium Tubae Abdominale - Broad funnel-like expansion of the proximal uterine tube.

Uterine Tube - The first portion of the oviduct distal to the ostium tubae.

Body of the Uterus - A typical duplex-type uterus connecting independently to the vagina from the right and left sides. A highly muscular structure. The distal second portion of the oviduct.

Vagina - Tubular posterior continuation of the genital tract. It receives anteriorly the right and left apertures of the uteri. At its exit into the vulva, it unites with the urethra to form the urogenital sinus.

Bulbourethral Gland - Located along the dorsal wall.

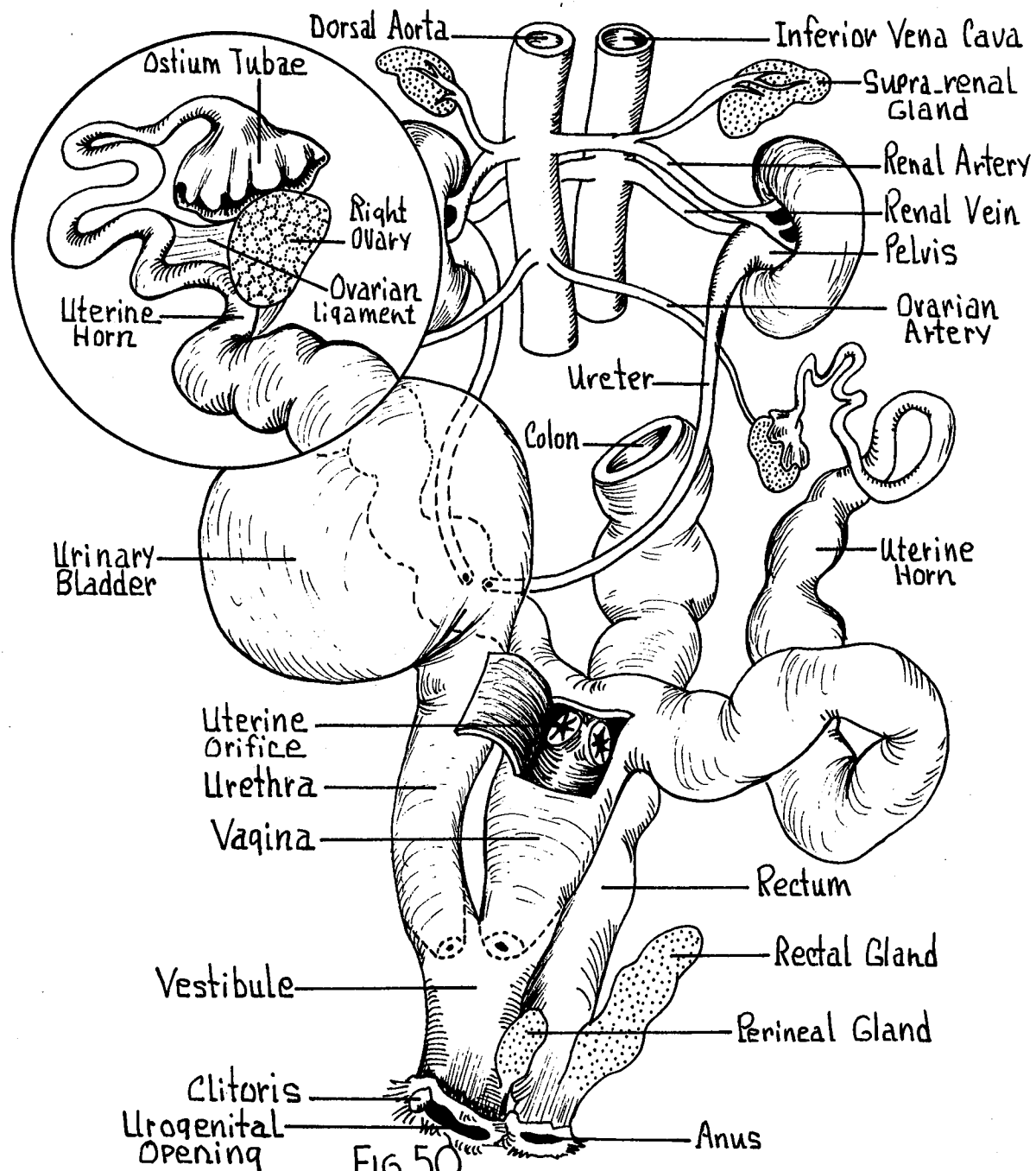


FIG. 50
UROGENITALS
 Female System

XIII. CENTRAL NERVOUS SYSTEM

MENINGES (Meninx) - The membranes surrounding the brain and spinal cord. Contains the cerebrospinal fluid.

Dura Mater - Tough outer sheath.

Pia Mater - More delicate, vascular sheath in direct contact with the brain and cord surface.

Arachnoid - Loose somewhat web-like membrane which connects the pia and dura mater. Not readily recognized in a gross dissection.

LATERAL ASPECT - (Fig. 51)

Cerebral Hemisphere - Paired. Smooth cortex due to absence of prominent gyri and sulci. Note the sylvian (lateral) fissure on the lateral surface.

Olfactory Bulb - Anterior projections from the region under the cerebral hemisphere. Paired.

Olfactory Tracts - Connecting band from olfactory bulb to the pyriform lobe of the cerebrum.

Optic Nerve (II) - The second cranial nerve passes under the cerebrum to the optic chiasma.

Cerebellum - Posterior to the cerebral hemisphere. Note the flocculus and vermis.

Medulla Oblongata - From which the major cranial nerves emerge. Ventral to the cerebellum.

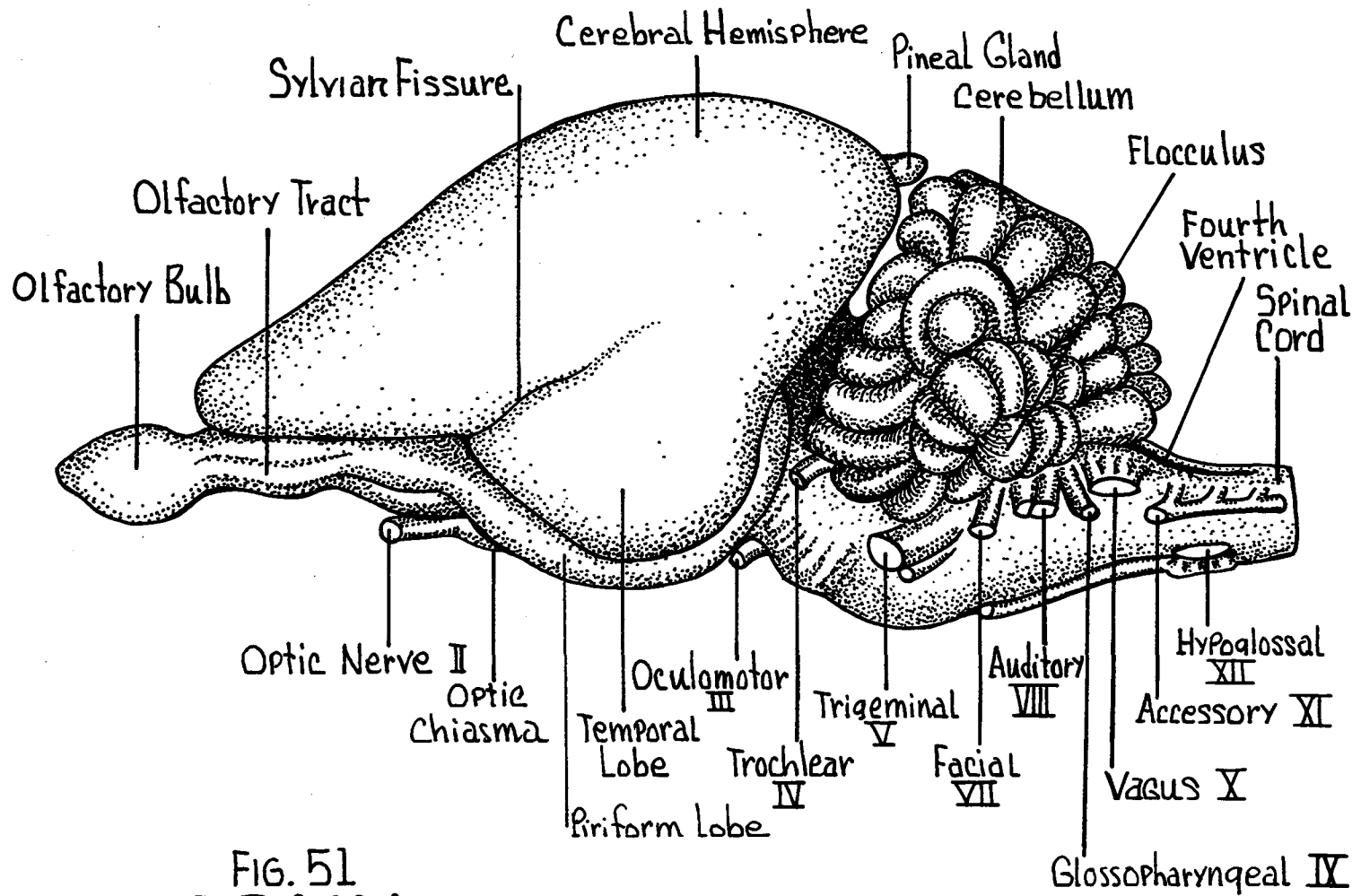


FIG. 51
BRAIN
 Lateral View

MEDIAN SAGITTAL SECTION - (Fig. 52)

Cerebral Hemispheres - Viewed on the medial service.

Not sectioned dorsal to the
corpus callosum.

Corpus Callosum - Longitudinal broad white band passing transversely from one hemisphere to the other. Forms the most dorsal structure in the midline.

Fornix - White narrow band extending ventrally and anteriorly from the hippocampus.

Foramen of Monro - Small opening posterior to the column of the fornix. Leads from the third ventricle to the lateral right and left ventricles of the cerebral hemisphere.

Septum Pellucidum - A thin septum between the body of the fornix and the anterior portion of the corpus callosum.

Anterior Commissure - Anterior to the ventral end of the fornix. A small white bundle of fibers.

Lamina Terminalis - Thin membrane extending from the anterior commissure ventrally to the region of the optic chiasma. Marks the anterior most boundaries of the third ventricle.

Spinal Cord - Posterior (caudal) continuation of the medulla oblongata.

Thalamus - Thickened lateral walls of the third ventricle.

Massa Intermedia - Rounded intermediate mass connecting the right and left thalami.

Pineal Gland (Body) - Conical structure projecting from the dorsal posterior portion of the third ventricle.

Corpora Quadrigemina - Four elevations (quadrigeminal bodies). in the dorsal region just posterior to the chorioid plexus of the third ventricle.

Superior Colliculus - Larger. Anterior pair.

Inferior Colliculus - Smaller. Posterior pair.

Aqueduct of Sylvius - Slender channel ventral to the corpora quadrigemina connecting the cavities of the third and fourth ventricles.

Anterior Medullary Velum - Thin membrane anterior to the cerebellum forming the anterior roof of the fourth ventricle.

Posterior Medullary Velum - Thin membrane posterior to the cerebellum and forms the posterior roof of the fourth ventricle and chorioid plexus.

Arbor Vitae - White branching structures seen on cross section of the cerebellum.

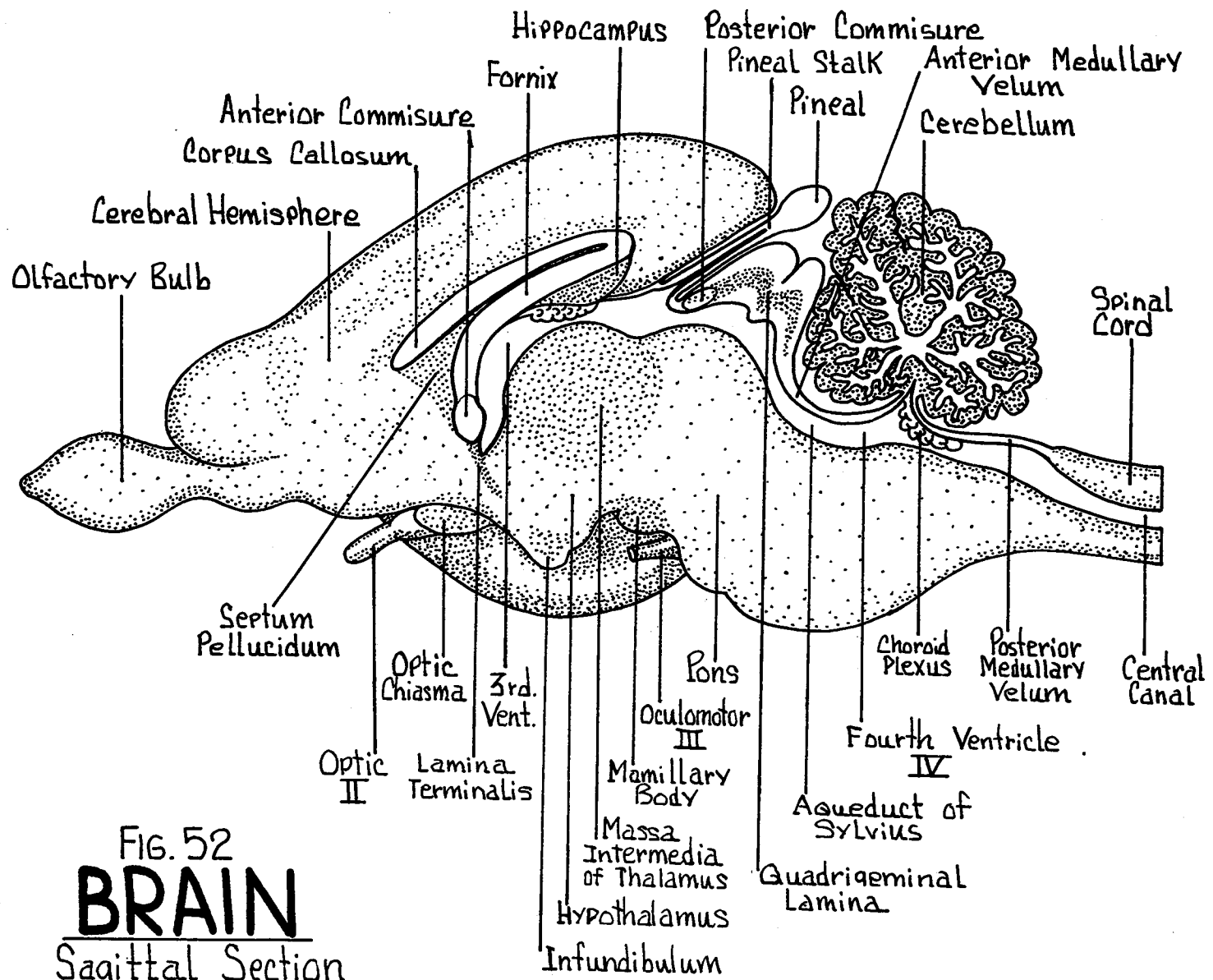


FIG. 52
BRAIN
 Sagittal Section

DORSAL ASPECT - (Fig. 53)

Cerebral Hemispheres - Paired. Right and left hemispheres separated by a median longitudinal fissure (sagittal fissure).

Olfactory Bulbs - Anterior swellings beneath the anterior portions of the cerebral hemispheres. Continues posteriorly as the olfactory tracts to the pyriform lobe.

Cerebellum - Posterior to the cerebral hemispheres.

Vermis - Median lobe.

Lateral Hemispheres - Paired lateral lobes.

Flocculus - From each hemisphere a narrow stalked lateral lobe.

Corpora Quadrigemina - Seen between the cerebrum and the cerebellum.

Medulla Oblongata - Partially overlapped by the vermis.

Note the thin wall of the triangular-shaped fourth ventricle.

Spinal Cord - Cylindrical extension from the posterior portion of the medulla caudad. Enters the neural canal within the vertebral column to continue posteriorly.

VENTRAL ASPECT - (Fig. 54)

Olfactory Bulbs - Anterior swellings continuing posteriorly as the olfactory tracts to the pyriform lobe of the cerebral hemispheres.

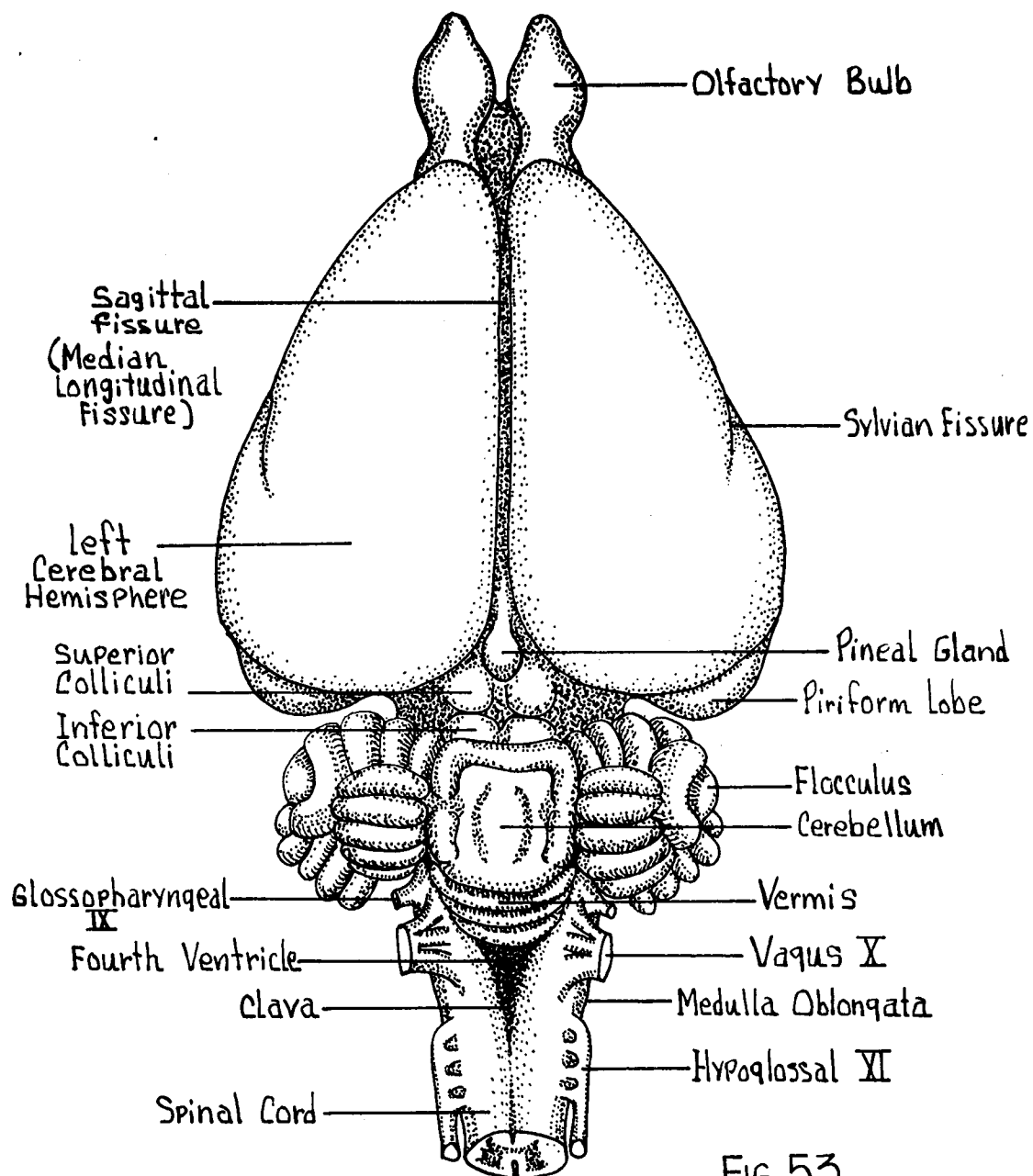


FIG. 53
BRAIN
 Dorsal View

Pyriform Lobes - Large ventral-posterior portion of the cerebral hemispheres.

Rhinal Fissure - Separates the pyriform lobe from the rest of the cerebrum.

Sylvian Fissure (Lateral Fissure) - Extends dorsally from the rhinal fissure along the lateral surface of the cerebrum.

Circle of Willis - Ring of blood vessels supplying the ventral surface of the brain.

Optic Chiasma - Crossing of the right and left optic nerves to continue posteriorly as the optic tracts.

Anterior Perforated Substance - Region between optic chiasma and olfactory tracts.

Tuber Cinereum - Rounded elevation posterior to the optic chiasma. For the attachment of the infundibulum of the pituitary gland.

Pituitary Gland (Hypophysis) - In an intact specimen, attached to the infundibulum. Endocrine in function.

Mamillary Bodies - Rounded elevations posterior to the tuber cinereum.

Cerebral Peduncles - Bundles passing obliquely forward from the region of the pons.

Pons - On the ventral surface a broad mass of fibers forming a commissural band extending transversely across the brain and dorsally towards the cerebellum.

Oculomotor (III) - Arises from the medial ventral region of the cerebral peduncles to pass anteriorly.

Trochlear (IV) - Arises from the region of the anterior medullary velum to pass along the lateral surface of the cerebral peduncles.

Trigeminal (V) - Large. Located posterior to the lateral portions of the pons. Arises by two roots, a larger sensory, and a smaller motor root.

Abducens (VI) - Small. Passes forward from the ventral surface of the medulla posterior to the pons.

Facial (VII) - Laterally placed. Arising from the medulla in close relation with the auditory (VIII).

Auditory (VIII) - Arising from the medulla posterior to the facial and trigeminal nerves.

Glossopharyngeal (IX) - Arises by several linear roots along the lateral margins of the medulla oblongata.

Vagus (X) - Arises from the lateral margins of the medulla in direct line with the glossopharyngeal and posterior to it.

Spinal Accessory (XI) - Arises by numerous roots along the lateral margin of the medulla.

Hypoglossal (XII) - Most posterior of the twelve cranial nerves. Arises by several roots from the ventral surface of the medulla.

Medulla Oblongata - Anterior swelling of the spinal cord.

Ventral Longitudinal Fissure - Median ventral groove extending from the medulla to the spinal cord.

SPINAL CORD - A thick cylindrical cord traversing the vertebral (neural) canal throughout its length. The cord terminates in the sacral region as the filum terminale.

Spinal Nerves - Formed by the union of two roots.

Dorsal Root - From the dorso-lateral region of the spinal cord.

Ventral Root - From the ventro-lateral region of the spinal cord.

Dorsal Root Ganglion - Enlarged swelling in dorsal root.

Dorsal Fissure - Narrow median groove.

Ventral Fissure - Wide ventral median groove.

Central Canal - Small cavity through the center of the cord.

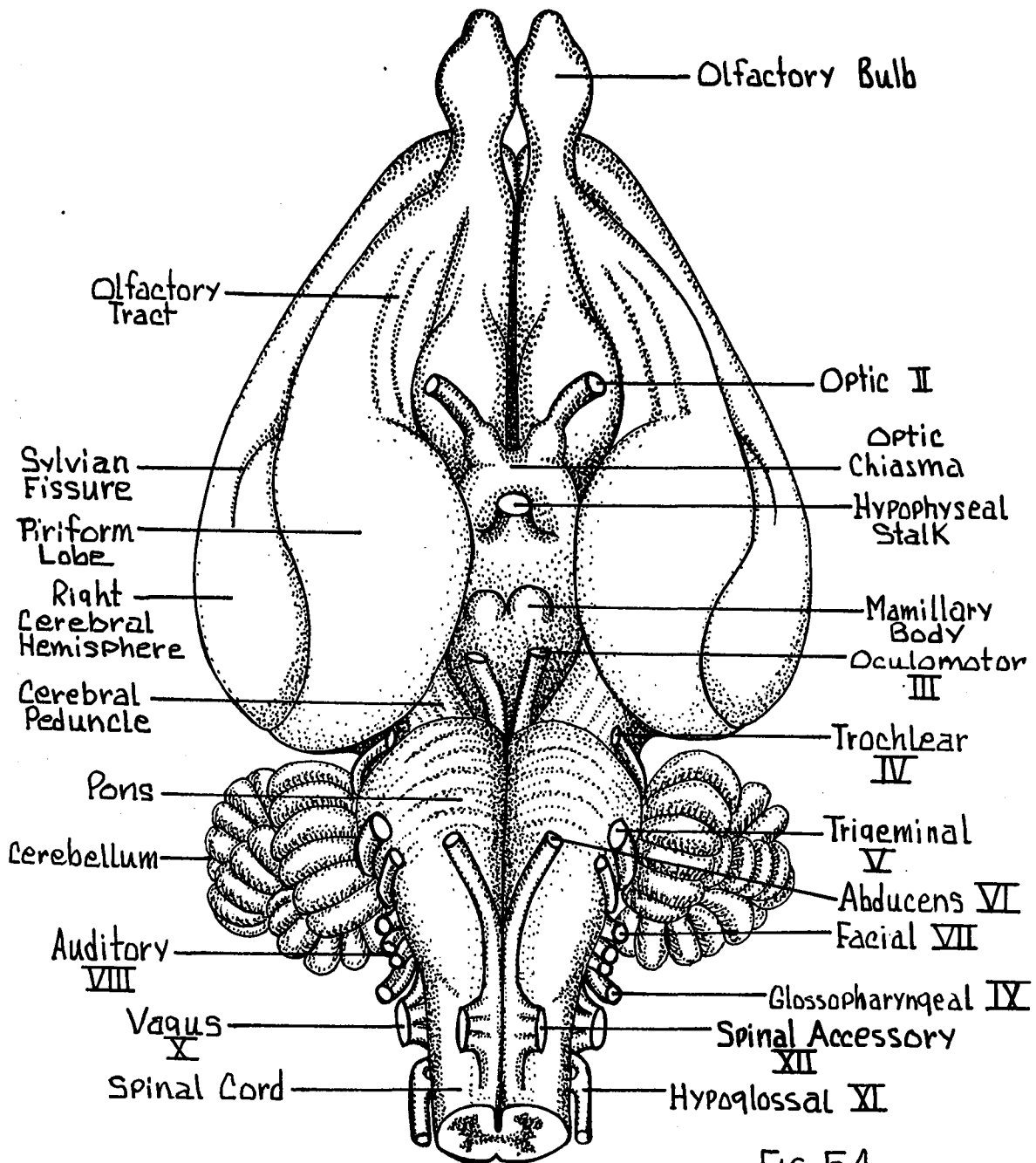


FIG. 54
BRAIN
 Ventral View

BIBLIOGRAPHY

XIV. BIBLIOGRAPHY

The following references are a selection of, and intended only as a condensed guide to, publications that are likely to be useful to students interested in descriptive and experimental morphology of rabbits.

Adams, Leverett A. and Samuel Eddy. Comparative Anatomy, An Introduction to the Vertebrates. New York: John Wiley and Sons, Inc., 1949.

Atwood, William H. Comparative Anatomy. Second edition. St. Louis: The C. V. Mosby Company, 1955.

Baldwin, Francis M. "Variations in the Carotid Arteries of the Rabbit." Anat. Rec. 15:49-51, 1919.

_____. "Notes on the Branches of the Aorta (arcus aortae) and the Subclavian Artery of the Rabbit." Anat. Rec. 19:173-183, 1920.

Bensley, B. A. Practical Anatomy of the Rabbit. Seventh edition. Revised by Craigie, E. H. Philadelphia: The Blakiston Company, 1946.

Bern, Howard and Boris Krichesky. "Anatomic and Histologic Studies of the Sex Accessories of the Male Rabbit." Univ. of California Publ. in Zool. 47:175-196, 1943.

Brodal, Alf. "The Cerebellum of the Rabbit." Jour. Comp. Neurol. 72:63-70, 1940.

Brown, Wade H., Louise Pearce, and Chester Van Allen. "Organ Weights of Normal Rabbits." Jour. Exp. Med. 43:733-741, 1926.

Bucy, Paul Clancy. "The Nictitating Membrane and the Superior Cervical Ganglion in the Rabbit." Jour. Comp. Neurol. 43:221-230, 1922.

Crabb, Edward Duane. Principles of Functional Anatomy of the Rabbit. St. Louis: John S. Swift Company, Inc., 1951.

_____. and Margaret A. Kelsall. "Organization of the Mucosa and Lymphatic Structures in the Rabbit Appendix." Jour. Morph. 67: 351-367, 1940.

_____. "An Anomalous Everted Piece of Ileum in an Adult Cottontail Rabbit." University of Colorado Studies Ser. D-1:221-223, 1941.

- Craigie, E. Horne. A Laboratory Guide to the Anatomy of the Rabbit. Philadelphia: The Blakiston Company, 1951.
- Drapeau, Elizabeth E. "An Anatomical Study of the Furless Condition in Rabbits," Jour. Morph. 54(2):365-388, 1933.
- Dunn, Thelma B. and Albert M. Kessel. "Injection and Clearing Method for the Rabbit's Ear," Jour. Nation. Cancer Inst. 4:359-360, 1944.
- Eales, Nellie B. "Note on the Abnormality in the Blood Vascular System of the Rabbit," Jour. Anat. 65:152-153, 1930.
- Edgeworth, F. H. The Cranial Muscles of Vertebrates. New York: The Macmillan Company, 1935.
- Emmens, C. W. "The Growth of Reproductive and Endocrine Organs of the Female Rabbit," Jour. Endocrinol. 1:409-416, 1939.
- Forster, Andre. "Le Masseter et le Pterygoiden Externe Chez Certains Rongeurs (cobaye, rat, lapin). Etude d'Anatomie Comparee et d'aptation," Arch. Anat. Histol. et Embryol. 9:193-226, 1929.
- Galsstone, S. "A Comparative Study in Vivo and Vitro of Rat and Rabbit Molars," Proc. Roy. Soc. (London) Ser. B. 126: 315-330, 1938.
- Girgis, A. "The Development of the Heart in the Rabbit," Proc. Zool. Soc. (London) 3:755-782, 1930.
- _____. "A Further Contribution on the Development of the Heart in the Rabbit," Proc. Zool. Soc. (London) 2:421-450, 1932.
- Goodrich, Edwin S. Studies on the Structure and Development of Vertebrates. London: The Macmillan Company, 1930.
- Grauer, Theophil P. "Regeneration in the Pancreas of Rabbit," Amer. Jour. Anat. 38:233-253, 1926.
- Hegner, Robert W. College Zoology. Fourth edition. New York: The Macmillan Company, 1939.
- Huxley, Thomas H. A Manual of the Anatomy of Vertebrated Animals. New York: D. Appleton and Company, 1872.
- Hyman, Libbie H. A Laboratory Manual for Comparative Anatomy. Chicago: University of Chicago Press, 1922.
- _____. Comparative Vertebrate Anatomy. Third edition. Chicago: University of Chicago Press, 1947.

- Johnson, Robert P. "Dissection of the Cranial Nerves Principally of the Rabbit" (unpublished paper, 1932).
- Kelsall, Margaret A. "Organization and Developmental Modifications in the Mucosa of the Rabbit Appendix" (unpublished Master's thesis, The University of Colorado, Boulder, 1940).
- _____. "Structure of the Saccules in the Procolon of the Pika," Jour. Morph. 70:115-119, 1942.
- Krause, Rudolph. Mikroskopische Anatomie der Wirbeltiere in Einzeldarstellungen I. Säugetiere. Berlin: Walter de Gruyter and Company, 1921.
- Kuhlendeck, Hartig, and Ruth N. Miller. "Pretecal Region of the Rabbit Brain," Jour. Comp. Neurol. 76:323-362, 1942.
- Lewis, A. A., and C. W. Turner. "The Size of the Rabbit Mammary Gland with Successive Lactations," Jour. Dairy Sci. 25:57-59, 1942.
- Little, M. E., and R. T. Kempton. A Laboratory Manual for Comparative Anatomy. New York: The Macmillan Company, 1928.
- McNutt, C. W., and P. B. Sawin. "A Genetic Study of the Pattern of the Vena Cava Inferior in the Rabbit," Genetics 27 1:156, 1942.
- Melanby, May, and Esther Killick. "Calcification in Rabbits," Jour. Physiol. 61:xxiii-xxiv, 1926.
- Mizu, Mitori. "Beitrage zur Histologischen Untersuchung der Ovarien des Kaninchens," Juzenkwaï Zasshi 32:, 1927.
- Nelson, E. W. The Rabbits of North America. North American Fauna No. 29. Washington: Government Printing Office, 1909.
- Noel, Rudolph J. "The Blood Vessels of the Jejunum and Ileum: A Comparative Study of Man and Certain Laboratory Animals," Amer. Jour. Anat. 72:294-326, 1934.
- Palmer, T. S. The Jack Rabbits of the United States. Bull. No. 8, Rev. Ed., U. S. Dept. Agric., Div. Biol. Survey. Washington: Government Printing Office, 1897.
- Parker, Thomas J., and William A. Haswell. A Textbook of Zoology. Vol. II. Sixth edition. London: The Macmillan Company, 1949.

- Pratt, Henry S. A Course in Vertebrate Zoology. New York: Ginn and Company, 1925.
- Quiring, Daniel P. Functional Anatomy of the Vertebrates. New York: The McGraw Hill Book Company, Inc., 1930.
- Rowett, H. G. Q. Dissection Guides, IV, The Rabbit. 5 vols. New York: Rhinehart and Company, Inc., 1957.
- Sawin, P. B., and C. W. McNutt. "Some Internal Morphological Variations and Their Relations to Adult Size in the Rabbit," Genetics 26:166-167, 1941.
- Sandstrom, Carl J., and Abraham Satzman. "A Comparative Study of the Clavicular Ligaments of the Rat, Rabbit, Cat and Dog," Anat. Rec. 29:23-32, 1944.
- Siddigi, M. A. H., and A. N. Millick. "On the Anatomy of Intercostal Spaces of Man and Certain Other Mammals," Jour. Anat. 69:350-355, 1935.
- Thompson, Eunice L. "Study of Collateral and Anomalous Circulation in the Rabbit" (unpublished Master's thesis, The University of Colorado, Boulder, 1932).
- Turttox Service Leaflets, 1955. How to Make Skeletons, No. 9. Chicago: General Biological Supply House, 1955.
- _____. The Embalming and Injection of the Cat and Laboratory Care of Embalmed Specimens, No. 21. Chicago: General Biological Supply House, 1955.
- _____. Injecting Vertebrate Skeleton, No. 55. Chicago: General Biological Supply House, 1955.
- Walker, Warren F., Jr. Vertebrate Dissection. Philadelphia: W. B. Saunders's Company, 1954.
- Walter, Herbert E., and Leonard P. Sayles. Biology of the Vertebrates. Third edition. New York: The Macmillan Company, 1949.
- Weichert, Charles K. Elements of Chordate Anatomy. New York: McGraw Hill Book Company, Inc., 1953.
- Whitehouse, R. H., and A. J. Grove. The Dissection of the Rabbit. London: The University Tutorial Press, 1933.