



12-15-2019

## Orofacial Pain and Menstrually Related Migraine

Chisa Nishihara  
*Nihon University School of Dentistry*

Keisuke Hatori  
*Nihon University School of Dentistry*

Yung-Chu Hsu  
*Chia-Yi Christian Hospital*

Kana Ozasa  
*Nihon University School of Dentistry*

Andrew L. Young  
*University of the Pacific, ayoung@pacific.edu*

*See next page for additional authors*

Follow this and additional works at: <https://scholarlycommons.pacific.edu/dugoni-facarticles>



Part of the [Dentistry Commons](#)

---

### Recommended Citation

Nishihara, C., Hatori, K., Hsu, Y., Ozasa, K., Young, A. L., Imamura, Y., & Noma, N. (2019). Orofacial Pain and Menstrually Related Migraine. *Acta Neurologica Taiwanica*, 28(4), 131–138.  
<https://scholarlycommons.pacific.edu/dugoni-facarticles/505>

This Article is brought to you for free and open access by the All Faculty Scholarship at Scholarly Commons. It has been accepted for inclusion in All Dugoni School of Dentistry Faculty Articles by an authorized administrator of Scholarly Commons. For more information, please contact [mgibney@pacific.edu](mailto:mgibney@pacific.edu).

---

## Authors

Chisa Nishihara, Keisuke Hatori, Yung-Chu Hsu, Kana Ozasa, Andrew L. Young, Yoshiki Imamura, and Noboru Noma

# Orofacial Pain and Menstrually Related Migraine

Chisa Nishihara<sup>1</sup>, Keisuke Hatori<sup>2</sup>, Yung-Chu, Hsu<sup>3</sup>, Kana Ozasa<sup>1</sup>, Andrew Young<sup>4</sup>,  
Yoshiki Imamura<sup>1</sup>, Noboru Noma<sup>1</sup>

## Abstract

**Purpose:** Migraine is a common, debilitating, primary headache disorder that can cause and be affected by odontalgia.

**Case report:** A 49-year-old woman (Patient 1) presented with pulsating pain in the left maxillary molar area, and a history of unsuccessful root canal treatment. She was ultimately diagnosed with menstrually related migraine without aura and zolmitriptan was prescribed, which reduced her headache and toothache together. A 45-year-old woman (Patient 2) presented with throbbing pain in the right maxillary molar and cheek area. Past repeated endodontic therapy had been unsuccessful. She was then diagnosed with menstrually related migraine without aura, and sumatriptan significantly reduced her headache and toothache. A 40-year-old woman (Patient 3) presented with pulsating pain near the left maxillary molar region. Pulpectomy was performed after she had previously received a diagnosis of pulpitis in the left maxillary second molar, but her pain did not subside. Patient 2 and 3 were misdiagnosed as pulpitis by dental practitioners and the pain did not relieve after pulpectomy. All patients were diagnosed as migraine by headache specialists and were treated with triptans, which resulted in satisfactory pain relief.

**Conclusion:** A thorough history and examination, as well as an understanding of migraine headaches, is necessary to differentiate odontogenic pain and migraine headaches.

**Key Words:** menstrually related migraine, orofacial pain, ICHD-3, headache

*Acta Neurol Taiwan 2019;28:131-138*

## INTRODUCTION

Migraine is a common, debilitating, primary headache disorder. According to the third edition of the International

Classification of Headache Disorders (ICHD-3), published by the International Headache Society in 2018<sup>(1)</sup>, typical characteristics of migraine without aura include “unilateral location, pulsating quality, moderate or severe intensity,

From the <sup>1</sup>Department of Oral Diagnostic Sciences, Nihon University school of Dentistry Tokyo, Japan. <sup>2</sup>Department of Endodontics, Nihon University School of Dentistry, 1-8-13 Kandasurugadai, Chiyoda-ku, Tokyo 101-8310, Japan. <sup>3</sup>Division of Neurology, Department of Internal Medicine, Ditmanson Medical Foundation Chia-Yi Christian Hospital, Chiayi, Taiwan. <sup>4</sup>Department of Diagnostic Sciences, Arthur Dugoni School of Dentistry, University of the Pacific, San Francisco, United States  
Received May 13, 2019.

Revised & Accepted December 17, 2019.

Correspondence to: Noboru Noma, Department of Oral Diagnostic Sciences, Nihon University school of Dentistry Tokyo, Japan

E-mail address: noma.noboru@nihon-u.ac.jp

aggravation by routine physical activity and association with nausea and/or photophobia and phonophobia." Migraine pain is usually felt at the temporal, frontal, or parietal region of the head.

It has been suggested that when pain occurs in forehead and temporal area, the term headache should be used; when the distribution of the pain occurs below the supraorbital rim, it is best described as facial pain<sup>(2,3)</sup>. Therefore, when typical unilateral features of a common migraine attack occur in an atypical pain location such as the face or jaw, it is often referred to as facial or midface migraine, and sometimes as lower-half migraine.

Some patients, in addition to the typical migraine features, also report atypical facial pain in one or both of the lower two distributions of the trigeminal nerve (V2 and V3)<sup>(2,3)</sup>. These patients are often first examined by a dentist, and the underlying migraine symptoms are often missed or misdiagnosed as odontogenic pain, trigeminal neuralgia, sinus headache, or other orofacial pain conditions, because migraine mimics other pathologies in the trigeminal system.

Migraine without aura is often associated with menstruation. The ICHD-3 includes criteria for "pure menstrual migraine without aura" (A1.1.1) and "menstrually related migraine without aura" (A1.1.2). However, these conditions are included in the Appendix "because of uncertainty over whether they should be regarded as separate entities"<sup>(1)</sup>. The present case series reviews the diagnosis and management of menstrual migraine, and the presentation of migraine with orofacial pain, including toothache.

## CASE REPORT

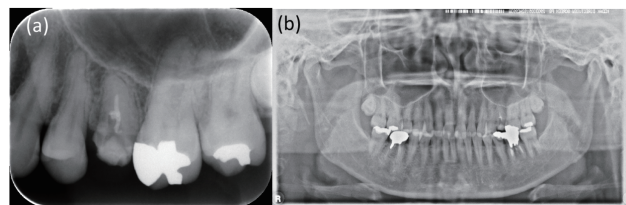
### Case 1.

A 49-year-old woman presented to the orofacial pain clinic at Nihon University with a chief complaint of pulsating pain, which had persisted for 2 years, in the left maxillary molar area. Although she also had a 20-year history of headaches, she had never experienced toothache until 2 years prior. Headache and toothache often developed before menstruation, and were accompanied by nausea, photophobia, and phonophobia. Her headache was occurring 4–5 times per month and usually persisted for 1–3 days. The intensity of the pain was usually mild (20–30

mm on the Visual Analogue Scale). However, the patient described occasional exacerbations of moderate to severe headache (60–70 mm on the VAS). By these symptoms, she fulfilled the ICHD-3 criteria for migraine headache.

Approximately 1 year before presenting at the orofacial pain clinic, the patient had seen a dentist for moderate pain in the upper left maxillary molar region. Under the impression of a periapical lesion, she underwent root canal treatment (RCT) of the upper left first premolar and was prescribed antibiotics; however, the pain persisted. She then consulted a neurologist. Computed tomography (CT) was performed, which did not reveal any intra-cranial pathology. She was diagnosed with menstrually related migraine, and zolmitriptan treatment was initiated, which reduced both the toothache and headache. The patient did not take the medication as often as prescribed due to the side effect of nausea.

The patient then presented to the dental school, where she was examined for a possible temporomandibular disorder (TMD). The neurological examination was normal. The temporomandibular joint (TMJ) was within normal limits. Muscle palpation elicited tenderness in the left temporalis muscle. Vertical and horizontal percussion was painless. Dental and panoramic radiographs did not reveal abnormalities (Fig 1a, b). Based on the clinical and dental radiographic examination, dental pathology was ruled out. The presence of photophobia and phonophobia, and her positive response to zolmitriptan, confirmed the diagnosis of migraine, rather than a TMD. She was referred back to her neurologist to control her migraine and associated toothache.



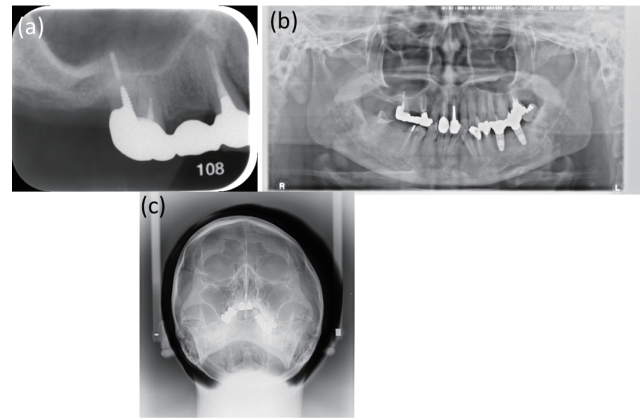
**Figure 1.** (a) Periapical and (b) panoramic radiographs showing no abnormal findings in the dentition or maxillary sinuses.

### Case 2.

A 45-year-old woman presented with throbbing pain in the right maxillary molar and cheek region. She reported that since the age of 35 years, she had experienced

throbbing right maxillary toothache with headache when fatigued, drinking alcohol, and before menstruation. The headaches were accompanied by photophobia, phonophobia, nausea, and, when severe, vomiting. Her response during such headaches was to go to bed. The headaches, which occurred almost weekly and persisted for approximately 24 h, had an intensity of 50 mm on the VAS. Approximately 2 months before seeking treatment at the endodontic clinic at our university hospital, she had consulted a general dental practitioner, who performed a pulpectomy after diagnosing pulpitis of the right maxillary first premolar. Over a period of 1 month, RCT was repeatedly performed for the right maxillary first molar at an endodontic clinic. However, the pain persisted, and she was referred to our orofacial pain clinic.

Neurological findings were normal. No abnormalities were observed in the temporomandibular joint. Muscle palpation elicited severe tenderness in the temporalis muscle on the right side, but did not reproduce the usual pain. Intraoral examination revealed no gingival tenderness around the maxillary right second molar. There was no percussion sensitivity in the maxillary right second premolar or second molar. Periapical, panoramic, and Waters radiographs revealed no abnormal findings in the dentition or maxillary sinuses (Fig. 2a–c).



**Figure 2.** (a) Periapical, (b) panoramic, and (c) Waters radiographs showing no abnormal findings in the dentition or maxillary sinuses.

The patient was asked to maintain a headache diary. An exclusive temporal link between headache and menstruation was noted, and a diagnosis of pure menstrual migraine was made (Table 1a). She was referred to a headache specialist, who prescribed sumatriptan; her headache and toothache dramatically improved.

**Table 1.** Headache diary

**A. Example of pure menstrual migraine**

	1	2	3	4	5	6	7	8	9	10	11	12	13	14	15	16	17	-----	26	27	28	29	30
Jan.				×	×	×	○	○	○	○													
Feb.				×	×	×	○	○															
Mar.					×	×	○	○	○														
Apr.			×	×	×	○	○																
May				×	×	×	○	○															
June							×	×	○	○													

**B: Example of menstrual related migraine**

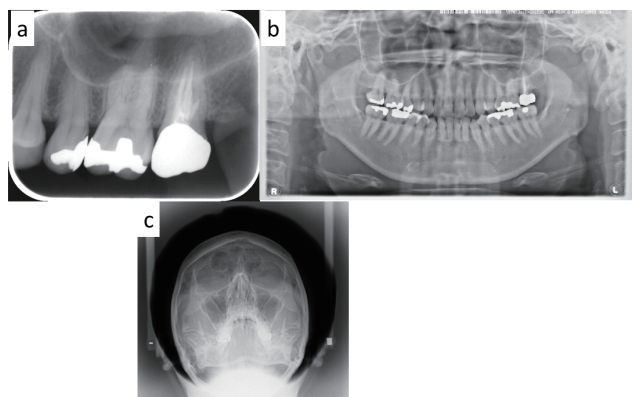
	1	2	3	4	5	6	7	8	9	10	11	12	13	14	15	16	17	-----	26	27	28	29	30
Jan.					×	×	○	○	×	○					×	×							
Feb.				×	×	×	○	○												×			
Mar.					×	×	×	○	○		×												
Apr.		×	×	×	×	○	○							×									
May				×	×	×	○	○															
June						×	×	×	○	○											×		

○ : menstruation      × : headache attacks

### Case 3.

A 40-year-old woman presented to our orofacial pain clinic with a chief complaint of pulsating pain of 2 year's duration in the left maxillary molar region. She reported a 4-year history of headache. Pulpectomy was performed after she had previously received a diagnosis of pulpitis in the left maxillary second molar, but her pain did not subside. The pain was present in the infraorbital, temporal, and maxillary regions on the left side and persisted for a few days to 1 week per episode. Pain intensity was usually moderate to severe (63 mm on the VAS). Headache and toothache were accompanied by nausea but not by photophobia or phonophobia. Headache and toothache were triggered by menstruation and odors (cigarette smoke). In the past, she had taken aspirin, which resulted in satisfactory relief. Over a period of 9 months, she repeatedly underwent RCT for the left maxillary second molar.

Her symptoms remained unchanged, and she was thus referred to our orofacial pain clinic. Neurologic findings were normal. There were no abnormal signs or symptoms in the bilateral temporomandibular joints. An intraoral examination revealed no gingival tenderness at the maxillary left second molar and no percussion pain. Dental, panoramic, and Waters radiographs revealed no abnormal findings involving the teeth or maxillary sinuses (Fig. 3 a-c).



**Figure 3.** (a) Periapical and (b) panoramic radiographs showing radiolucent areas in the maxillary left second molar. (c) A Waters radiograph did not show any abnormal findings in the teeth or maxillary sinuses. Radiolucent areas in the maxillary left second molar disappeared 1 year after the root canal treatment.

We asked the patient to keep a headache diary. Pure menstrual migraine was considered, as we noted a temporal link between headache and menstruation (Table 1a), and she was referred to a headache clinic. The patient declined treatment with a triptan class medication. It is not known if her symptoms later improved.

## DISCUSSION

The ICHD-3 specifies two major migraine subtypes of migraine headaches: migraine without aura (ICHD-3, 1.1), and migraine with aura (1.2)<sup>(1)</sup>. The term "facial migraine" is mentioned in the ICHD 3, but it is still considered a migraine headache rather than a separate subgroup. Facial migraines therefore follow the diagnostic criteria for migraine without aura, i.e., recurrent headache of moderate-to-severe intensity that persists for 4–72 h. Further, it has a pulsating quality and unilateral presentation, is aggravated by routine physical activity, and is associated with nausea and phonophobia, photophobia, or both<sup>(3,4)</sup>.

We described three patients with dental or facial pain as the chief complaint. Although the location of pain differed, all patients described migraine attacks that fulfilled the diagnostic criteria for migraine without aura, which was diagnosed by a headache specialist. In a previous small case report, the authors described migraine presenting solely as toothache, whereas most reports of migraine presenting in the face and mouth report concomitant typical unilateral headache<sup>(3,5)</sup>. Benoliel et al. reported 8 patients who had orofacial pain with vascular-type features similar to those of migraine without aura<sup>(6)</sup>. Daudia et al. identified 24 patients with facial pain in the second distribution of the trigeminal nerve and concomitant migrainous features in a cohort of 973 successively employed patients in a rhinology setting<sup>(7)</sup>. Penarrocha et al. considered this condition to be lower-half facial migraine<sup>(4)</sup>. In the present cases, the following diagnoses were initially considered: rhinosinusitis and myofascial pain for cases 1 and 2, pulpitis for case 3.

Migraines are frequently confused with sinus headache due to acute rhinosinusitis (ICHD-3 11.5.1)<sup>(1,8)</sup>, at least in part due to the overlap in location of these two headaches. Referred pain may explain the atypical pain sites in our migraine patients, as the somatic part

of the trigeminal nerve (V2 and V3) may converge with the visceral part (V1) of the trigeminal nucleus<sup>(9,10)</sup>. This can cause clinical symptoms in the lower-half facial distribution<sup>(4)</sup>. The second reason for a misdiagnosis is that migraine can cause symptoms that are similar to those of rhinosinusitis, such as facial pain, nasal congestion, and rhinorrhea via the superior salivary nucleus of the facial nerve.

To assess for the possibility of acute rhinosinusitis in patients 1 and 2, the patients were asked to bend forward. With that test, facial pain did not worsen. The diagnosis of acute rhinosinusitis was further excluded by panoramic and Waters radiographs, which revealed no abnormal findings in the teeth or maxillary sinuses. Other tests that can be used include topical anesthesia to the middle or superior turbinates, and CT imaging.

In all the presented cases, though migraines either caused or contributed to the toothache, and toothache was only present during headache, root canal treatments were performed. Cases 1 and 2 were only referred to an orofacial pain clinic after the general dentists or endodontists had started the inappropriate treatment for toothache. Prior root canal treatment can add an additional layer of complexity to the diagnostic process, as do migrainous features. This reinforces the need for accurate diagnosis in the initial examination.

All cases had headache in combination with pain

in the maxillary premolars and molars and the cheek, which are in the second division of the trigeminal nerve (Table 2). If a patient presents to a dental practitioner with a chief complaint of pain in the maxillary premolars, molars, or cheeks, possible dental conditions should be ruled out with appropriate testing such as percussion, apical tenderness, periodontal probing, cold testing, sensitivity to air, and radiographs. The most accurate indicator of dental pathology is the presence of percussion, pus, and apical tenderness, and radiographic findings. Patients may complain of dental pain with those tests, but the dentist needs to confirm if this pain is the familiar pain or headache. If clear causative dental pathology is not present, irreversible dental treatment should not be initiated, and non-dental causes of pain should be considered.

The authors propose here an algorithm for migraine diagnosis, which may prevent misdiagnosis, through a flowchart to progressively differentiate migraine from the other diseases (Table 3). However, this algorithm addresses solely odontogenic and migrainous etiologies. Other causes of pain in the trigeminal system, which can manifest in the dentition, include the already-mentioned sinusitis and myalgia/myofascial pain, as well as arthralgia of the temporomandibular joint, other headaches (such as trigeminal autonomic cephalgias<sup>(11)</sup>), neuropathic pain, and more ominous conditions such as cerebrovascular

**Table 2.** Pain characteristics and treatment

	Patient 1	Patient 2	Patient 3
Age (years)	49	45	40
Gender	Female	Female	Female
Duration of illness (years)	20	10	4
Attack duration (days)	1-3	1	2-3
Location	V2 left	V2 right	V2 left
Quality	Pulsating	Throbbing	Pulsating
Pain intensity (VAS, 0-100 mm)	30	50	63
Accompanying symptoms	Nausea Photophobia Phonophobia	Nausea Vomiting Photophobia Phonophobia	Nausea Osmophobia
Aggravating factors	Menstruation	Menstruation Alcohol/stress	Menstruation Odors(cigarette smoke)
Treatment	Zolmitriptan	Sumatriptan	Sumatriptan

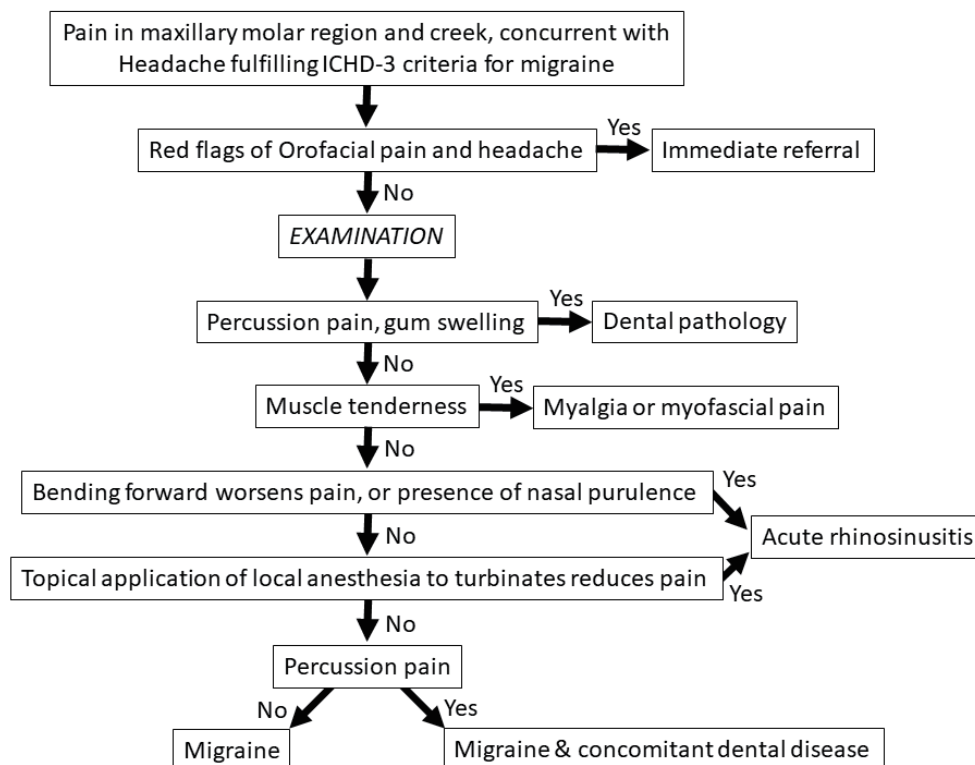


disease, meningitis, encephalitis, intracranial neoplasm, and extracranial neoplasm<sup>(12)</sup>. The latter, more ominous group should be suspected if a patient's history is positive for any “red flag” signs or symptoms (Table 4)<sup>(13)</sup>. The

presence of “red flags” warrants immediate referral for medical evaluation.

Menstrually related migraine frequently begins during the years after onset of menstruation<sup>(14)</sup>. It is most

**Table 3.** Diagnostic algorithm for toothache in a patient with migraine headache



**Table 4.** Red flag signs and symptoms in headaches

<b>“Red Flag” Signs and Symptoms in Headaches</b>
Over 50 years of age
“Worst” headache/thunderclap
Seizure/collapse/loss of consciousness
Nausea and vomiting (when migraine has been ruled out)
Change in headache character
Impairment/ loss of consciousness
Focal neurological deficits, papilledema and meningeal signs



prevalent in the fifth decade of life, and its prevalence declines after menopause<sup>(15)</sup>. Menstrually related migraine occurs without aura, although aura may be experienced with migraine at other times of the month. In both disorders, headaches naturally occur about 2 days before onset of bleeding and can last up to 5 days<sup>(16)</sup>. Nausea and vomiting appear to be more common for menstrual migraines than for typical migraine<sup>(17)</sup>. In the present case series, cases 1 had menstrually related migraine, whereas case 2 and 3 had pure menstrual migraine. In general, nausea and vomiting seem to be more common with menstrual migraines than with typical migraine. The migraine attacks in all the present cases were accompanied by nausea; however, only case 1 (menstrually related migraine) had associated vomiting (Table 2).

Menstrual migraine is thought to be related to hormone concentrations, specifically the rapid decrease in estrogen concentration just before bleeding onset. This may have been the cause for cases 1 and 2. Migraine may also be triggered by stress (case 1), alcohol (case 2) and cigarette odor (case 3). Treatment of menstrual migraine can be challenging because patients respond differently to the various treatment options<sup>(18)</sup>. The first step in treatment planning is to identify a link between headache and menstruation. This can be aided by having the patient keep a headache diary. Once a link is established, treatments that include over-the-counter medication and lifestyle changes can be initiated. Acute therapy aims to decrease attack symptoms, duration, and disability. Patients should consider avoiding triggers such as diet, chronobiologic factors, environmental factors, head and neck pain, physical exertion, and stress<sup>(19,20)</sup>. In the present case series, we discovered the link between headache and menstruation by using a headache diary (Table 1a, b). We advised patients to avoid triggers, namely, alcohol and stress (case 2; Table 2). Finally, as we mentioned earlier, since apical periodontitis or inflammation caused by physical stimuli may be one of the trigger factors, we recommend RCT for patients with apical lesions. Pharmacologic treatment consisted of a 5-hydroxytryptan 1B/1D receptor agonist (zolmitriptan), for cases 1, and sumatriptan for case 2. These treatments successfully reduced the frequency and intensity of pain episodes (Table 2).

## CONCLUSION

When migraines refer to the tooth or face, they can lead to inappropriate dental treatment and iatrogenic damage. Patients in cases 1, 2 and 3 received incorrect diagnoses of pulpitis or periapical lesions and were treated with repeated RCT. When patients with a history of headache visit a dental practitioner complaining of toothache, dentists should examine the relationship between toothache and headache. Patients with no sensitivity to percussion and normal radiographic findings should be assessed for nonodontogenic causes, such as migraine, and referred for consultation with appropriate medical specialists. For patients with migraine and concomitant dental disease, appropriate dental treatment may decrease the symptoms of migraine.

## Conflict of interest

The authors have stated explicitly that there are no conflicts of interest in connection with this article.

## REFERENCE

1. Headache Classification Committee of the International Headache Society (IHS) The International Classification of Headache Disorders, 3rd edition. *Cephalalgia* 2018;38:1-211.
2. Obermann M, Mueller D, Yoon MS, Pageler L, Diener H, Katsarava Z. Migraine with isolated facial pain: a diagnostic challenge. *Cephalalgia* 2007;27:1278-1282.
3. Alonso AA, Nixdorf DR. Case series of four different headache types presenting as tooth pain. *J Endod* 2006;32:1110-1113.
4. Penarrocha M, Bandres A, Penarrocha M, Bagan JV. Lower-half facial migraine: a report of 11 cases. *J Oral Maxillofac Surg* 2004;62:1453-1456.
5. Namazi MR. Presentation of migraine as odontalgia. *Headache* 2001;41:420-421.
6. Benoliel R, Elishoov H, Sharav Y. Orofacial pain with vascular-type features. *Oral Surg Oral Med Oral Pathol Oral Radiol Endod* 1997;84:506-512.
7. Daudia AT, Jones NS. Facial migraine in a rhinological setting. *Clin Otolaryngol Allied Sci* 2002;27:521-525.
8. Eross E, Dodick D, Eross M. The Sinus, Allergy and Migraine Study (SAMS). *Headache* 2007;47:213-224.

9. Arendt-Nielsen L, Laursen RJ, Drewes AM. Referred pain as an indicator for neural plasticity. *Prog Brain Res* 2000;129:343-356.
10. Bartsch T, Goadsby PJ. The trigeminocervical complex and migraine: current concepts and synthesis. *Curr Pain Headache Rep* 2003;7:371-376.
11. Khan J, Quek SY, Markman S. Nasopharyngeal carcinoma masquerading as TMJ orofacial pain. *Quintessence Int* 2010;41:387-389.
12. Noma N, Shimizu K, Watanabe K, Young A, Imamura Y, Khan J. Cracked tooth syndrome mimicking trigeminal autonomic cephalgia: A report of four cases. *Quintessence Int* 2017;48:329-337.
13. Lynch KM, Brett F. Headaches that kill: a retrospective study of incidence, etiology and clinical features in cases of sudden death. *Cephalgia* 2012;32:972-978.
14. Recober A, Geweke LO. Menstrual migraine. *Curr Neurol Neurosci Rep* 2005;5:93-98.
15. Vetvik KG, Russell MB. Are menstrual and nonmenstrual migraine attacks different? *Curr Pain Headache Rep* 2011;15:339-342.
16. Vetvik KG, MacGregor EA, Lundqvist C, Russell MB. Self-reported menstrual migraine in the general population. *J Headache Pain* 2010;11:87-92.
17. MacGregor EA. Menstrual migraine. *Curr Opin Neurol* 2008;21:309-315.
18. MacGregor EA. Migraine Management During Menstruation and Menopause. *Continuum (Minneapolis)* 2015;21:990-1003.
19. Spierings EL, Ranke AH, Honkoop PC. Precipitating and aggravating factors of migraine versus tension-type headache. *Headache* 2001;41:554-558.
20. Wober C, Holzhammer J, Zeitlhofer J, Wessely P, Wober-Bingol C. Trigger factors of migraine and tension-type headache: experience and knowledge of the patients. *J Headache Pain* 2006;7:188-195.