



May 8th, 2:15 PM - 5:00 PM

Primary Failure of Eruption: Failure is Not an Option

Jonathan Starley
University of the Pacific

Follow this and additional works at: <https://scholarlycommons.pacific.edu/excellence-day>



Part of the [Dentistry Commons](#)

Starley, Jonathan, "Primary Failure of Eruption: Failure is Not an Option" (2024). *Excellence Day*. 67.
<https://scholarlycommons.pacific.edu/excellence-day/2024/events/67>

This Presentation is brought to you for free and open access by the Arthur A. Dugoni School of Dentistry at Scholarly Commons. It has been accepted for inclusion in Excellence Day by an authorized administrator of Scholarly Commons. For more information, please contact mgibney@pacific.edu.

OKU Sutro Excellence Day Project Cover Sheet

Project Title

Primary Failure of Eruption: Failure Is Not An Option

Full name(s) and class year(s) of all project collaborators

Example: Jane Smith, DDS 2022; John Smith, DDS 2022

Jonathan Starley Orthodontics 2024
Faculty: Dr. Heesoo Oh; Dr. David Lam

Project Category

Residents - Orthodontics

Enter your abstract text here (max 300 words)

This patient presented to the orthodontic clinic with a chief complaint of multiple unerupted teeth in the upper left quadrant and one unerupted tooth in the lower left quadrant. Primary failure of eruption was the suspected diagnoses. The patient was told the teeth would need to be extracted by a previous oral surgeon and came in looking for other options. Due to the nature of primary failure of eruption, orthodontic force applied to the teeth would lead to the teeth being ankylosed. It was proposed to use corticotomy surgery in conjunction with orthodontic treatment to facilitate tooth movement and retrieve the unerupted teeth as well as close the bite on the left side. After surgery where corticotomies were performed as well as extraction of the third molar and second premolar in the upper left quadrant, orthodontic forces were applied utilizing a lower TAD as indirect anchorage to prevent side effects in the lower arch. We were able to successfully retrieve the upper left canine, achieve movement of the upper left premolar, and some slight extrusion of the first molar as well as moving the lower left second molar into position. Unfortunately, the upper left second molar was unsuccessful and needed to be extracted. Due to the lack of extrusion, we were able to achieve with the upper left first molar, we are planning an onlay crown in order to restore the occlusion and function as well as a future implant in the upper left second premolar region.

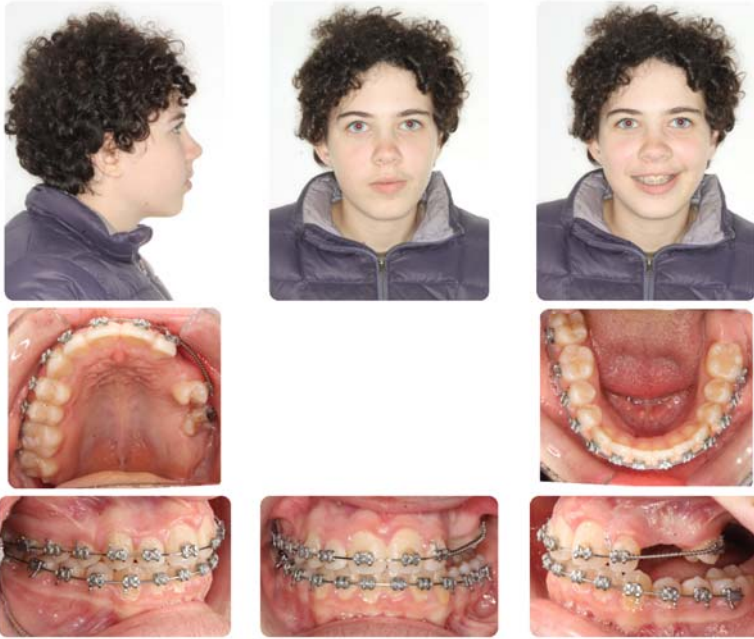I would like to thank Dr. Oh for her supervision and guidance throughout the case as well as Dr. Lam for his surgical expertise and implementation of the surgical plan and Dr. Al-Wakeel for helping us with the post-orthodontic prosthodontic and restorative plans. I would also like to thank my patient Jessica and her parents for being compliant and for the sacrifices they have made to make all of this possible.



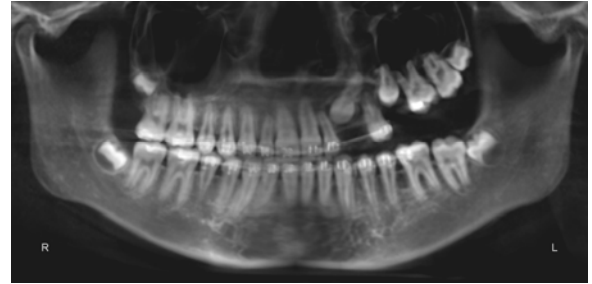
Primary Failure of Eruption: Failure Is Not An Option

Orthodontic Resident: Jonathan Starley; Faculty: Dr. Heesoo Oh; Dr. David Lam

Initial Imaging from 12/08/2023



- 15 year old female
- Patient came in for multiple unerupted/partially erupted teeth in upper left quadrant
- Primary failure of eruption suspected

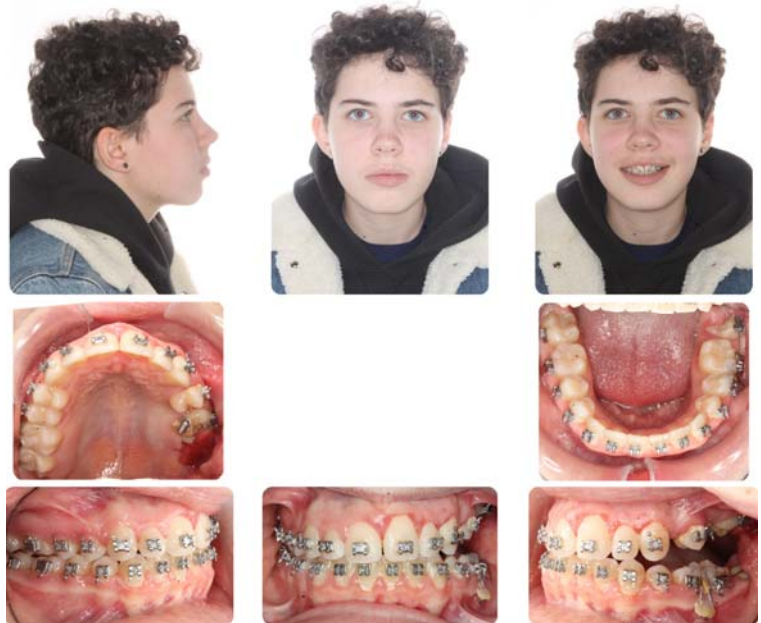

Treatment Plan:

- Extraction of UL third molar and second molar
- Corticotomy performed in UL quadrant near remaining teeth in order to facilitate movement of teeth
- TAD placement in LL for indirect anchorage
- Elastics used to apply force and to move UL teeth into the arch

Outcome and Plan:

- UL Canine was brought into arch successfully
- UL first molar was extruded, though not completely
- UL second molar was extracted due to lack of movement after corticotomy
- Plan is to leave space for UL second premolar implant and a full coverage only to restore the first molar



Initial

Current

