



May 8th, 2:15 PM - 5:00 PM

Lateral Substitution with Full Fixed Appliances

Jeff Roseth
University of the Pacific

Edrick Tan
University of the Pacific

Follow this and additional works at: <https://scholarlycommons.pacific.edu/excellence-day>



Part of the [Dentistry Commons](#)

Roseth, Jeff and Tan, Edrick, "Lateral Substitution with Full Fixed Appliances" (2024). *Excellence Day*. 61.
<https://scholarlycommons.pacific.edu/excellence-day/2024/events/61>

This Presentation is brought to you for free and open access by the Arthur A. Dugoni School of Dentistry at Scholarly Commons. It has been accepted for inclusion in Excellence Day by an authorized administrator of Scholarly Commons. For more information, please contact mgibney@pacific.edu.

OKU Sutro Excellence Day Project Cover Sheet

Project Title

Lateral Substitution with Fixed Appliances

Full name(s) and class year(s) of all project collaborators

Example: Jane Smith, DDS 2022; John Smith, DDS 2022

Jeff Roseth, Ortho Resident 2024; Edrick Tan, DDS 2024

Project Category

Residents - Orthodontics

Enter your abstract text here (max 300 words)

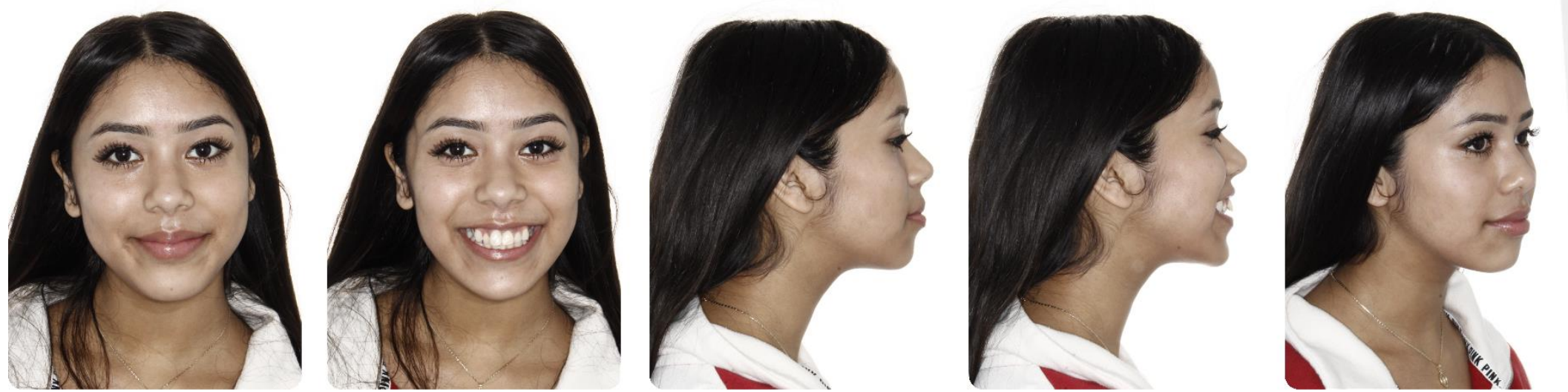This patient reported to the orthodontic clinic with a chief concern of crowding in the maxillary and mandibular arches. The patient had previous trauma to her U1s during a biking accident about 5 years prior to coming in for her initial ortho consultation. U1s were previously restored with root canals and composite fillings. Upon re-evaluation of root canals at UOP, prior to starting ortho treatment, it was determined that the prognosis for UL1 was hopeless and UR1 needed new root canal therapy.

After consults from the Endo, Ortho and restorative departments, it was determined that the treatment plan would include full comprehensive orthodontics with fixed braces and extractions of UL1 and LL4. Crown of UL1 was to be used as pontic when closing the space. UL2 would be substituted for the UL1 with veneer being placed on UR1 and UL2 with enameloplasty of UL3 to improve shape and contour following orthodontic treatment. LL4 extracted due to crowding, lower midline deviated to the right and to maintain CI I molar/canine relationship. Elastics were used as needed for titration of anchorage although TADs were discussed as well. Patient finished with CI I occlusion although both upper and lower midlines are deviated about 1.5-2mm to the left. Crown lengthening performed U2-2 in preparation for veneers on UR1 and UL2. I would like to thank Dr. Heesoo Oh for her diligent supervision with this case. I would also like to thank Edrick Tan, restorative, perio and endo faculty for their efforts and communication with this case.

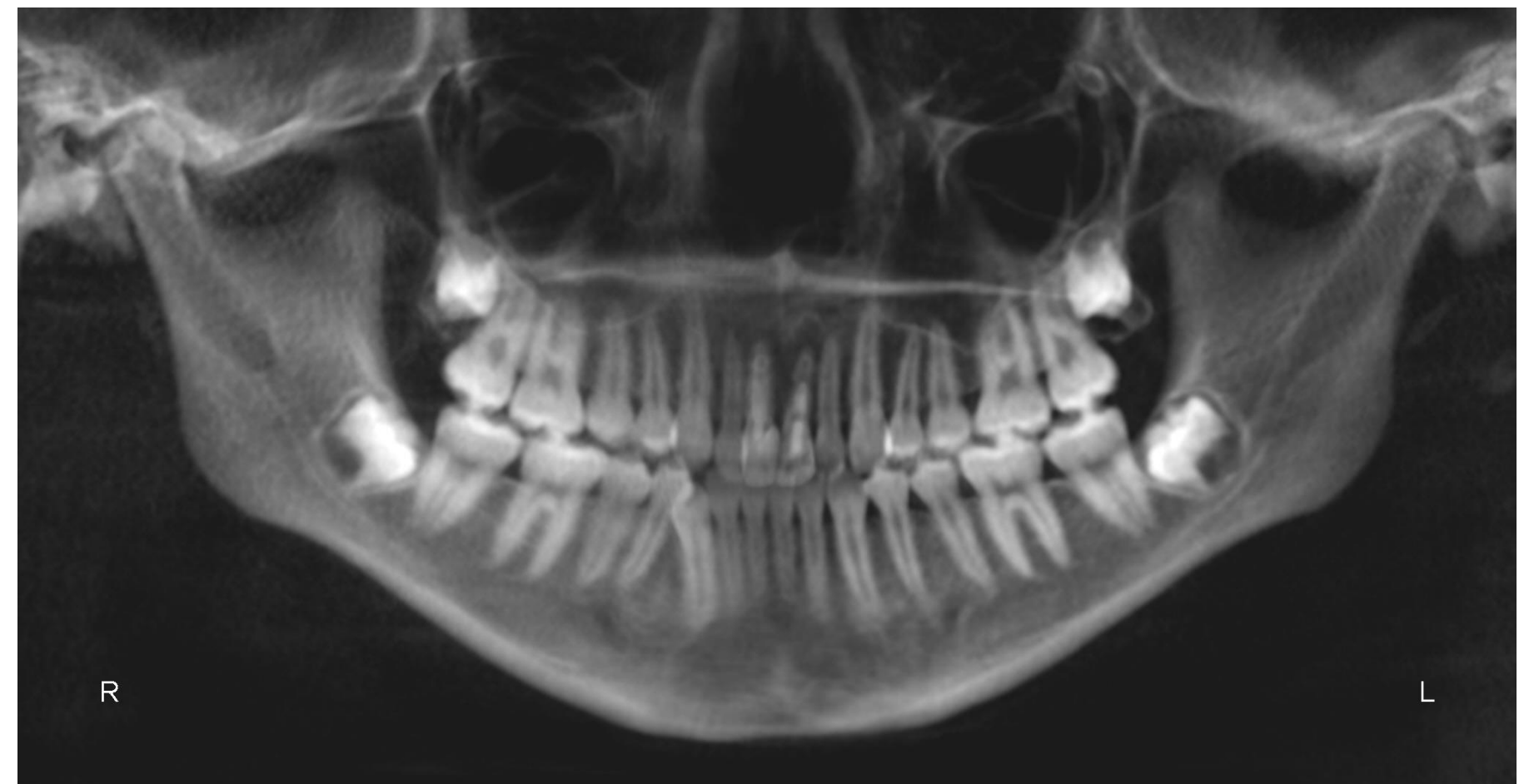
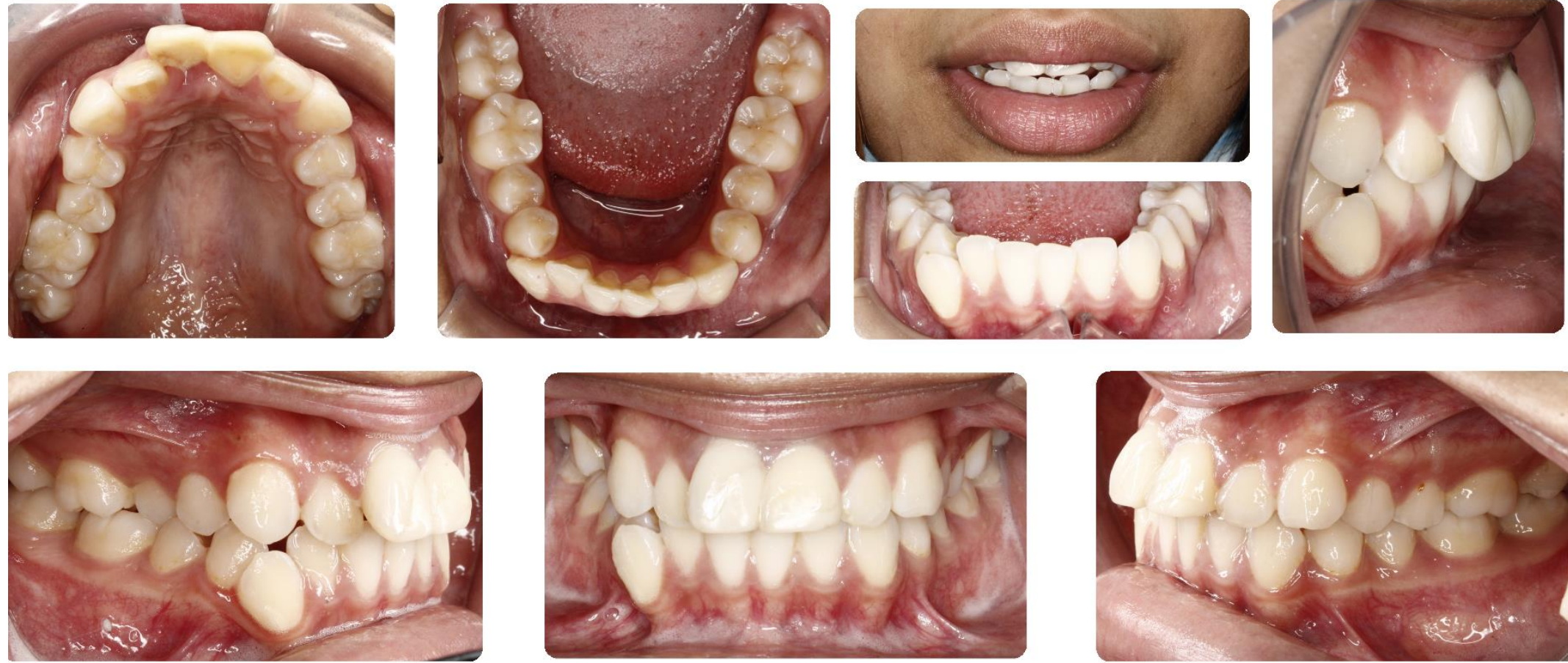Lateral Substitution with Full Fixed Appliances

Orthodontic Resident: Jeff Roeth; Faculty: Dr. Heesoo Oh; DDS student: Edrick Tan

Initial composite and panoramic radiograph from 4/29/19



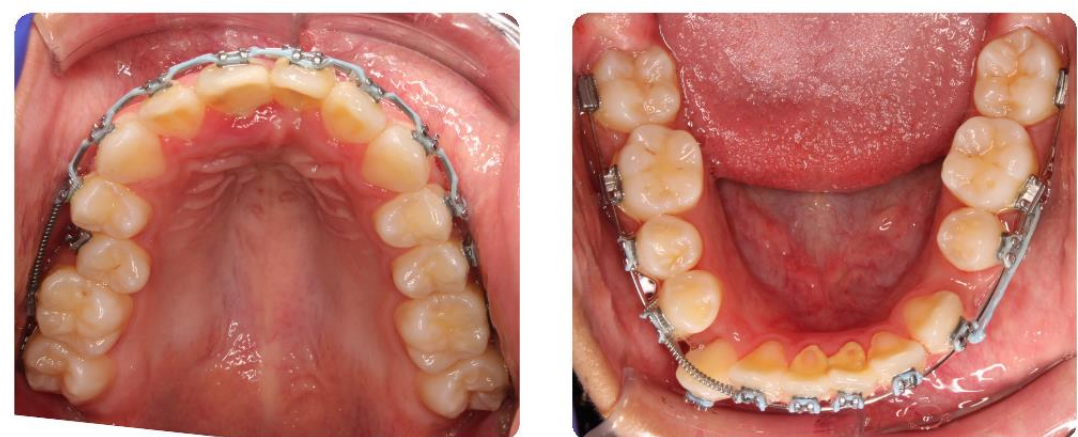
- 14 year old female
- CC: Patient would like to correct upper and lower crowding
- Tx Start: 7/16/2021



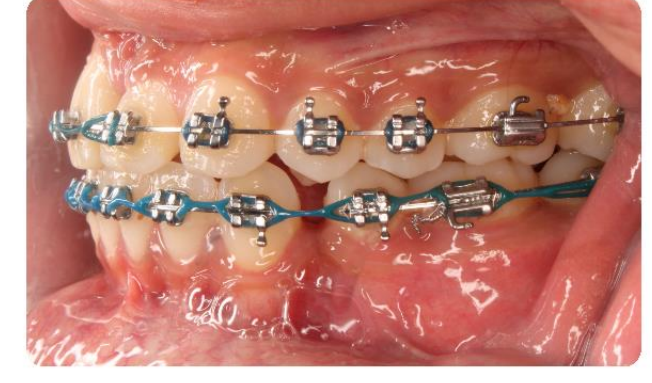
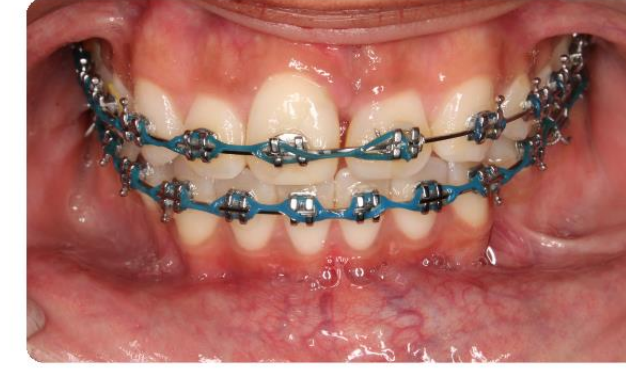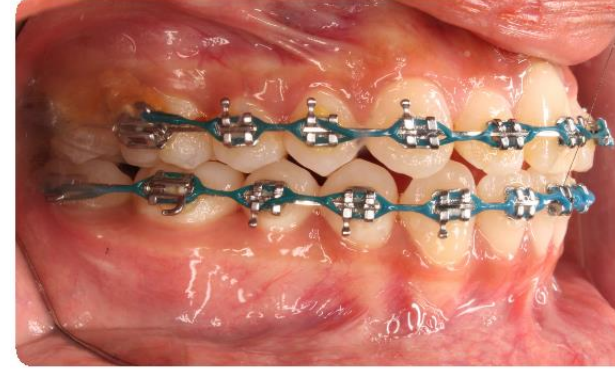
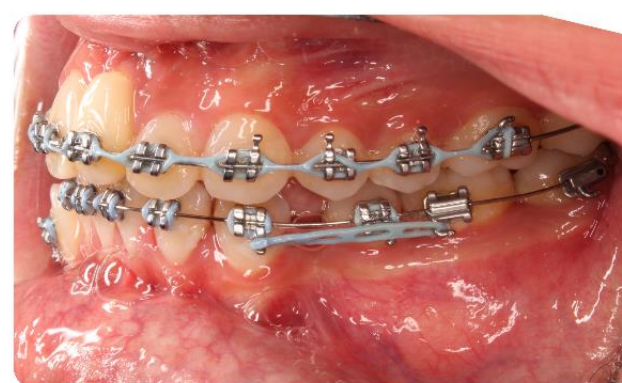
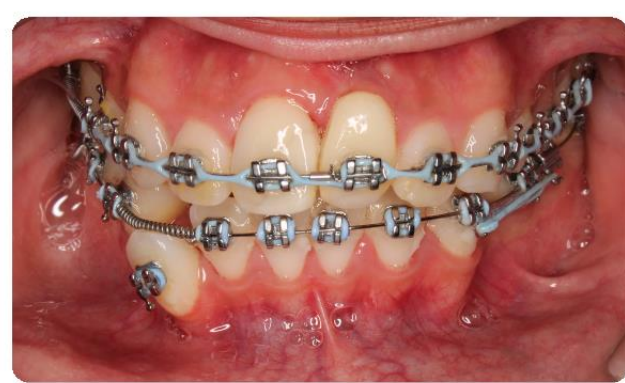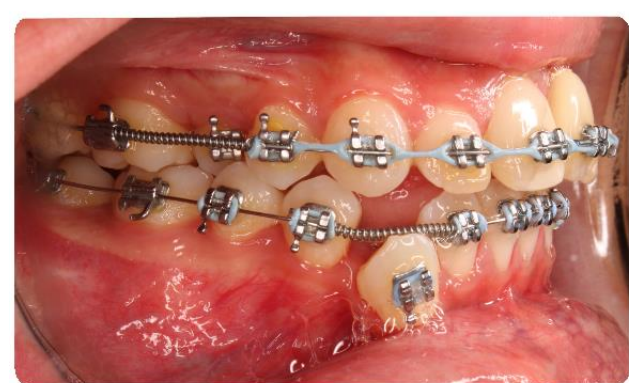Tx plan:

- Lateral substitution with ext of #9, 21
- Elastics as needed for anchorage

10 month progress



1Y8M progress

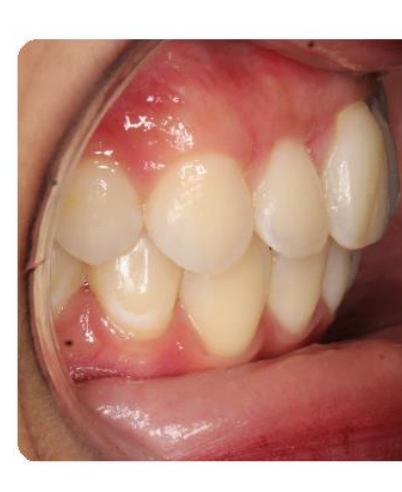
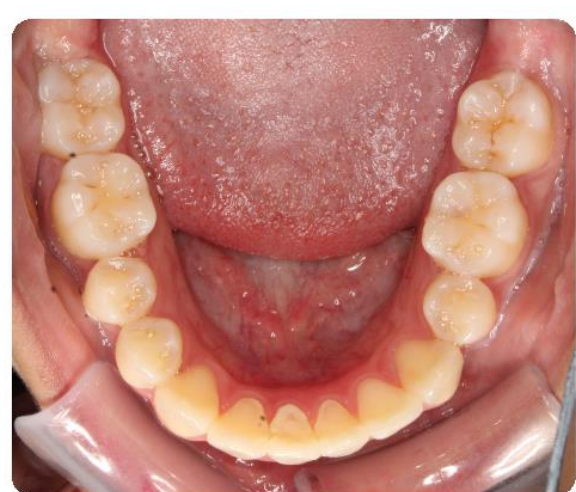
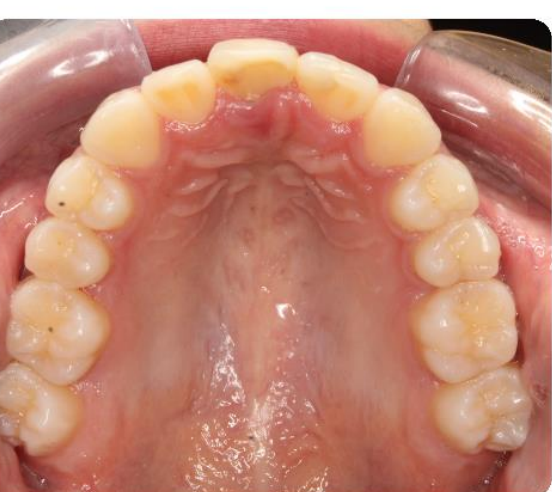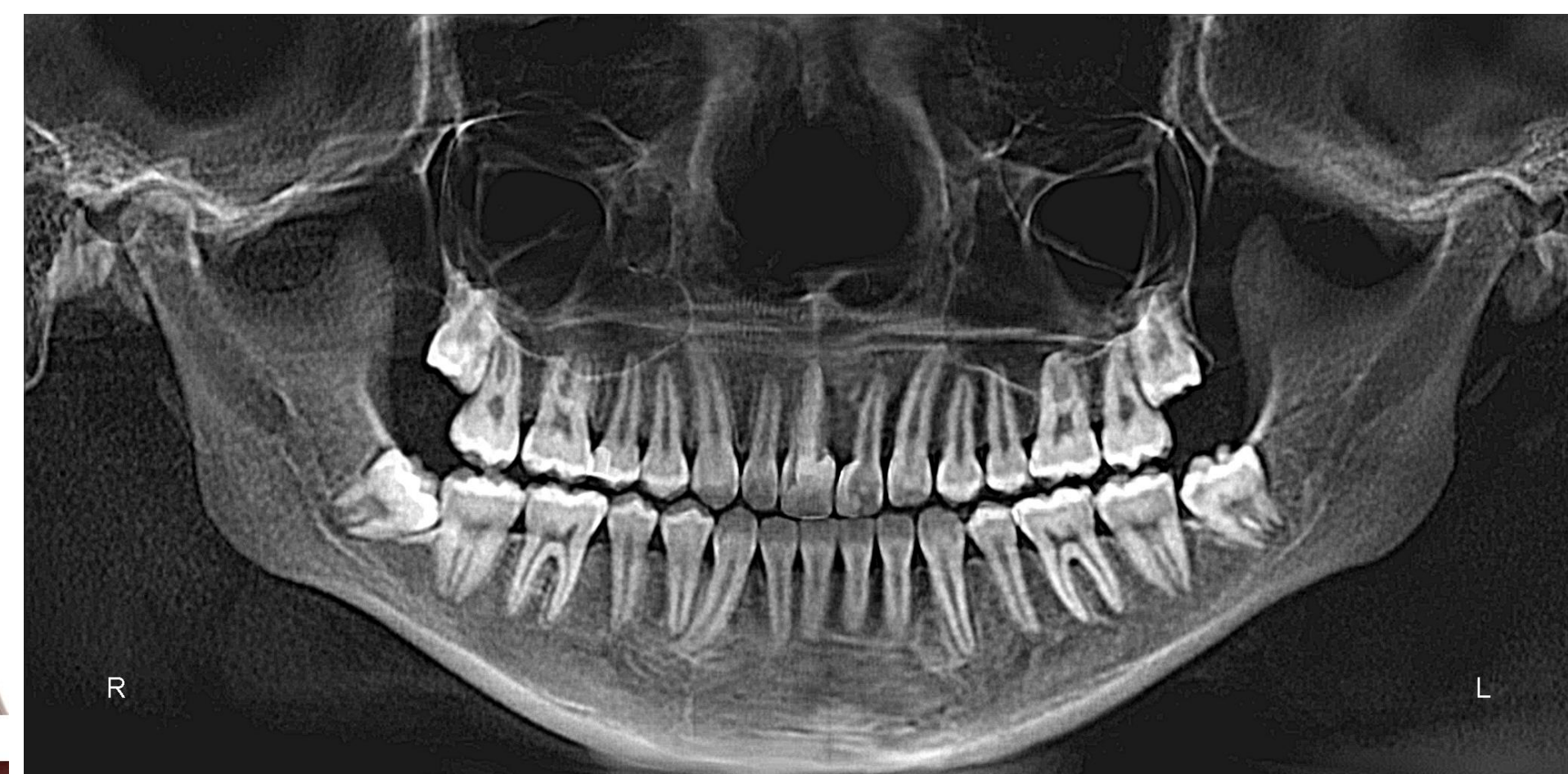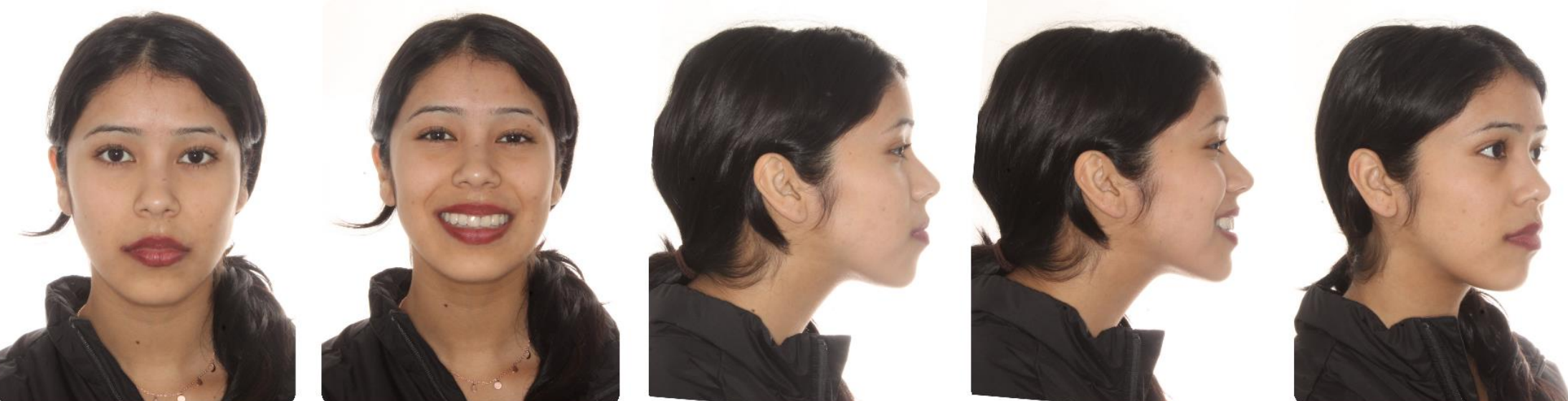Final – post orthodontic treatment

Tx End: 2/27/2024

Total Treatment time: 2Y7M

Photo taken post-crown lengthening (4/3/2024)



- Crown lengthening completed 7, 8, 10
- Whitening to be completed prior to provisional restorations
- Veneers planned for #8, #10

