



May 8th, 2:15 PM - 5:00 PM

Endosseous Implant PLacement in the Le Fort I Maxilla

Kathleen Pham
University of the Pacific

Follow this and additional works at: <https://scholarlycommons.pacific.edu/excellence-day>



Part of the [Dentistry Commons](#)

Pham, Kathleen, "Endosseous Implant PLacement in the Le Fort I Maxilla" (2024). *Excellence Day*. 8.
<https://scholarlycommons.pacific.edu/excellence-day/2024/events/8>

This Presentation is brought to you for free and open access by the Arthur A. Dugoni School of Dentistry at Scholarly Commons. It has been accepted for inclusion in Excellence Day by an authorized administrator of Scholarly Commons. For more information, please contact mgibney@pacific.edu.

Endosseous Implant Placement in the Le Fort I Maxilla

Kathleen Phan, DMD
AEGD 2024

UNIVERSITY OF THE
PACIFIC
Arthur A. Dugoni
School of Dentistry



Intro

My name is Kathleen Phan

Graduated from Tufts School of Dental
Medicine in 2023.

PGY-1 2024 AEGD UOP

Born and raised in the San Jose. Will
be practicing in the Peninsula and
South Bay Area



**CC: “I want to fix
my smile”**

HPI: Pt presents for POE. Pt reports that he had extensive dental work completed since his childhood in Poland.

Patient History

Social Hx: Patient is a retired electrical engineer. Pt lives in the East Bay Area with his wife. Has adult children. No hx of smoking, drinks socially.

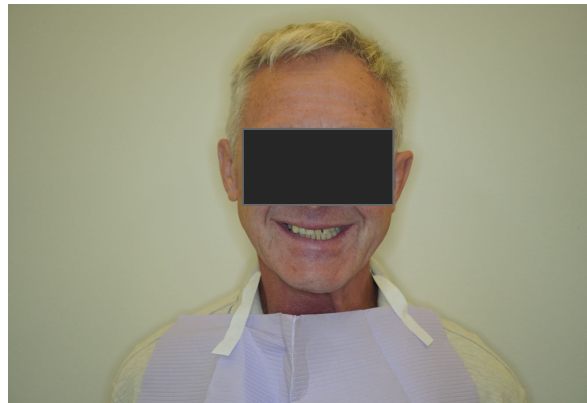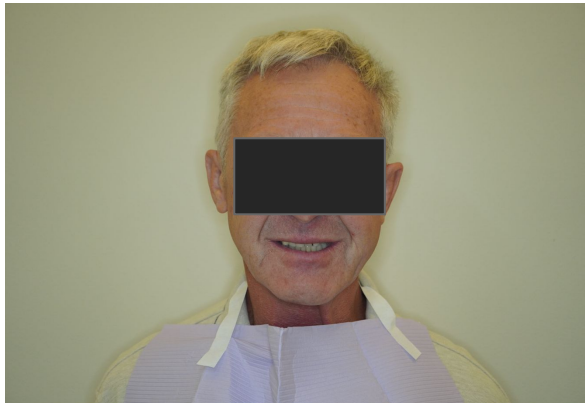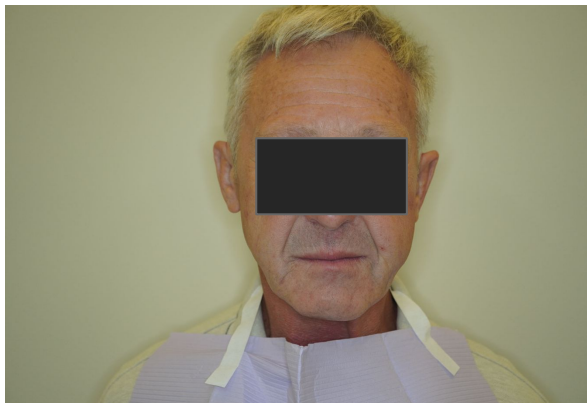Medical hx: HTN

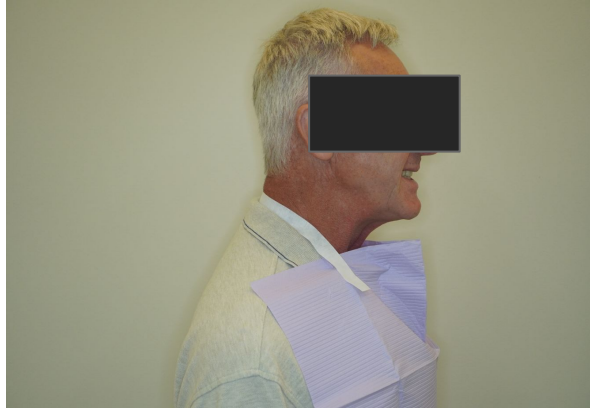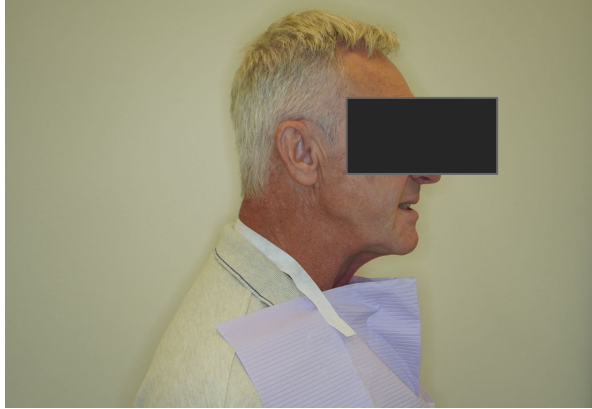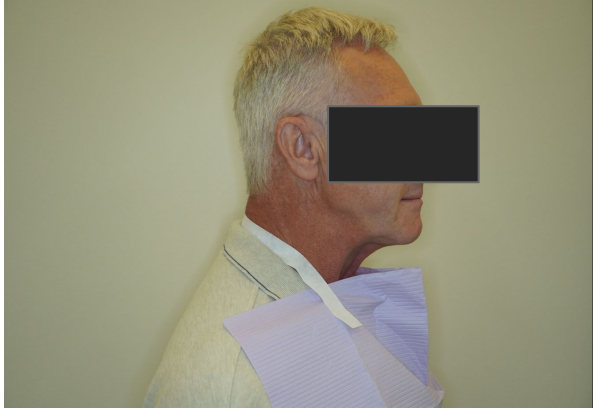Allergies: NKDA

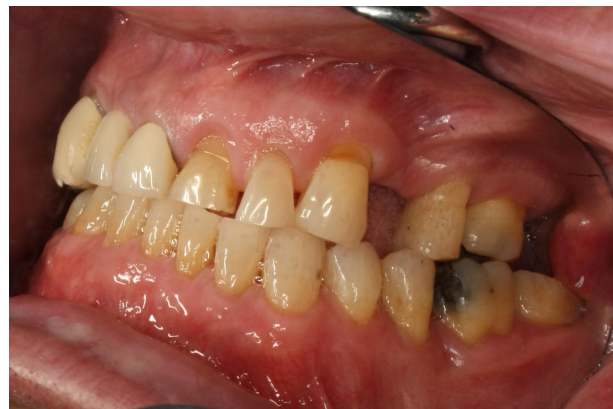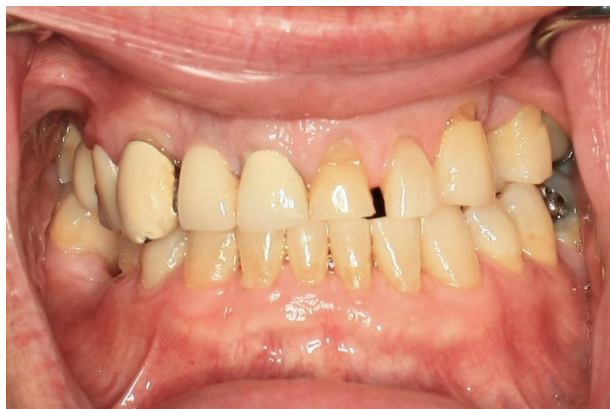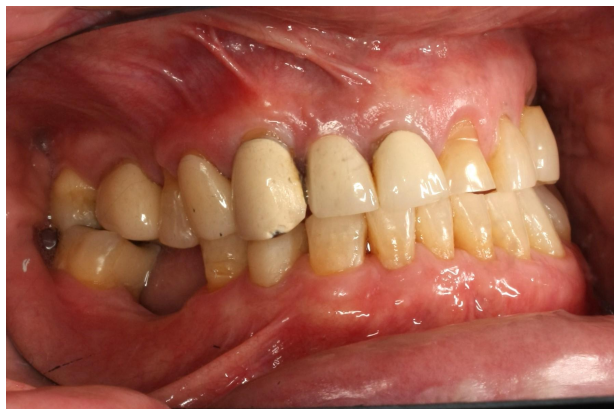Medications:

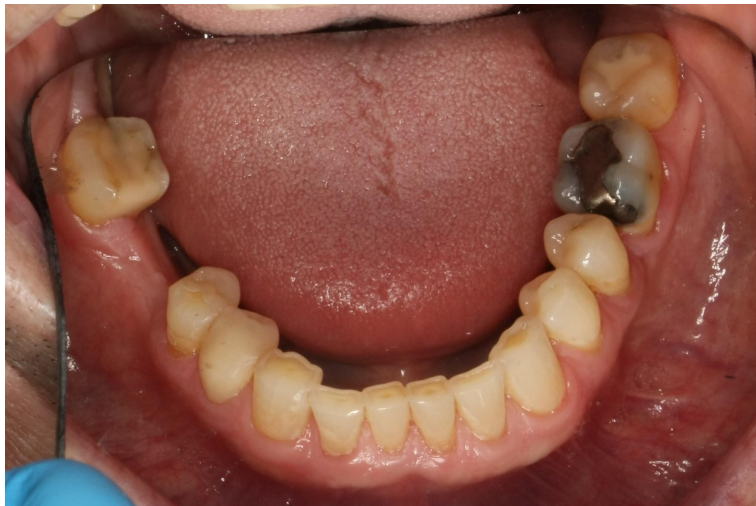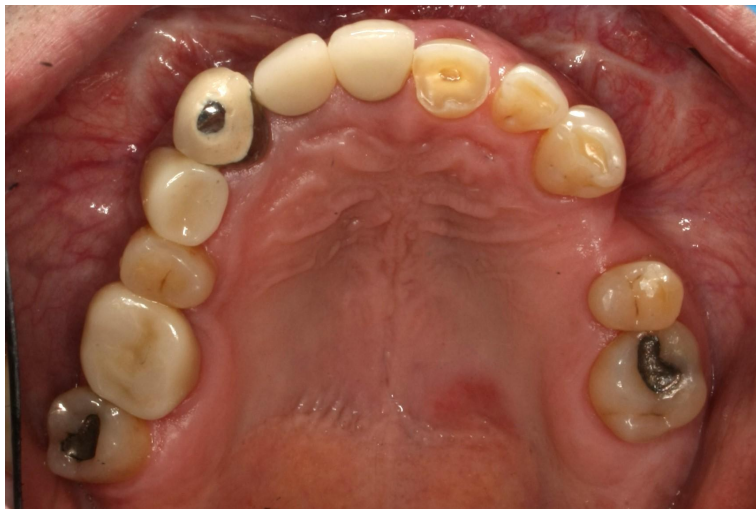
Lisinopril 10mg - QD

Propranolol 5mg - QD



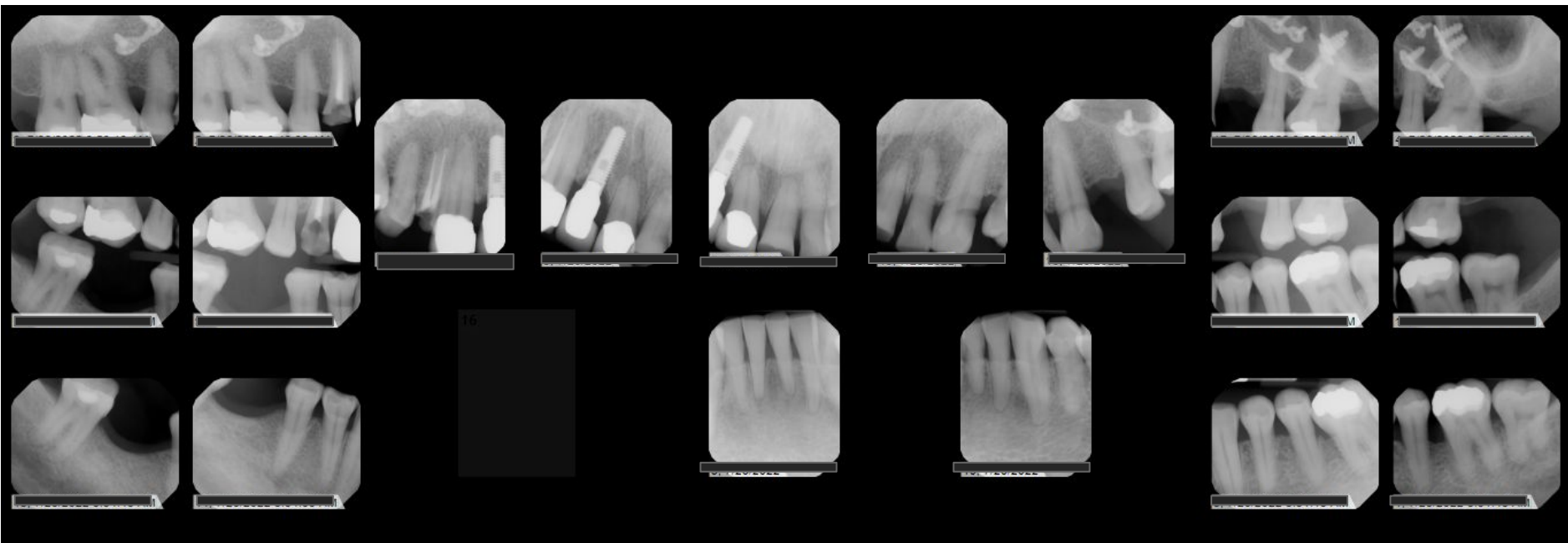




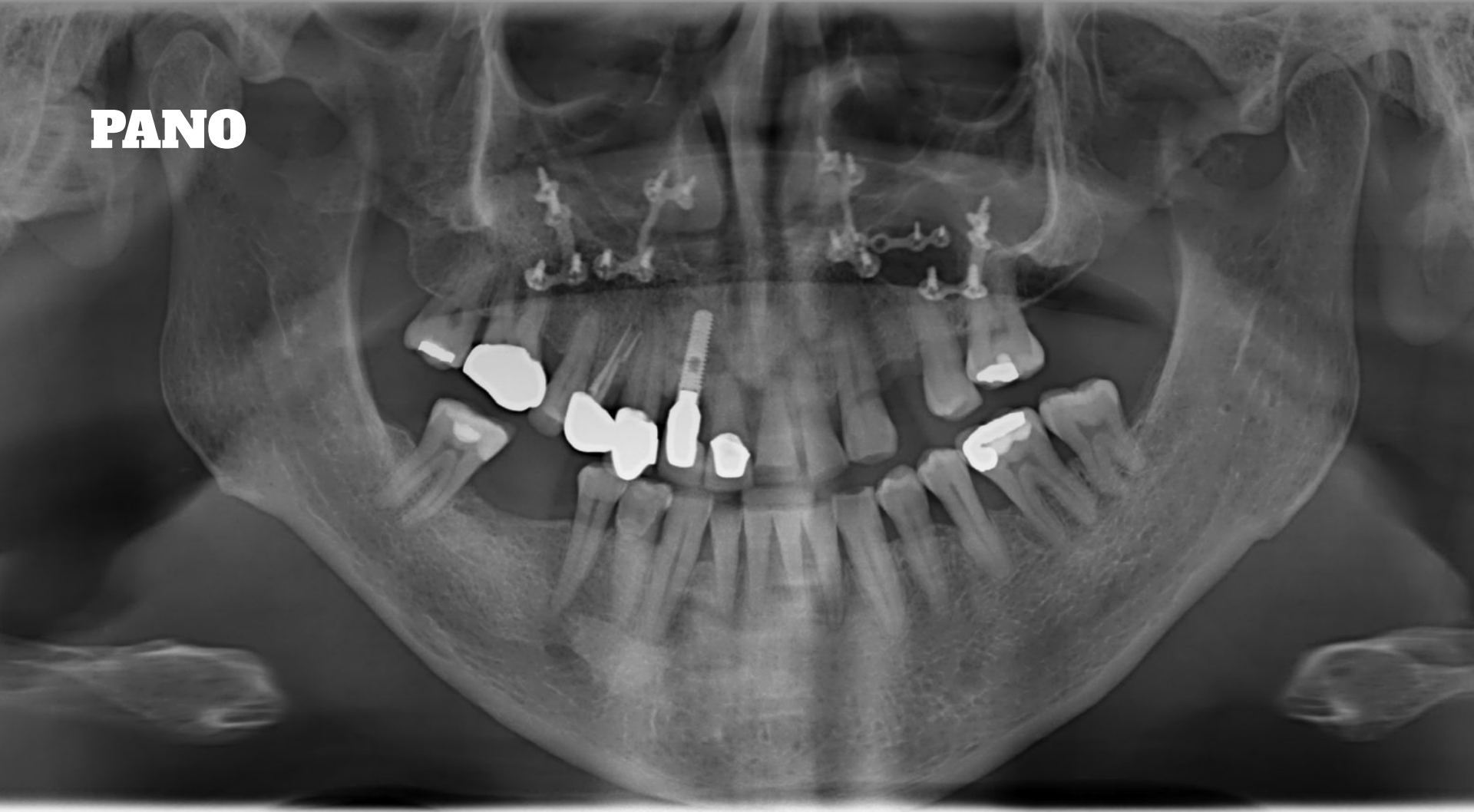

DENTAL HISTORY:

- Orthodontia ~1961 in Poland
- Le Fort I osteotomy ~15 years ago + Ortho
- Orthodontia 2022 w/ Dr. Ricupito for extrusion of #5 for restorative purposes
- Occlusion: R – Canine Class III, L – Canine Class I
- Notable generalized attrition observed
- #2 and #5 crowns delivered in spring 2023
- Pt expressed dissatisfaction w/ bulbous appearance of #6 PFM crown
- #6 has open margins
- Perio: Generalized Chronic Moderate Periodontitis Grade B Stage II – PD <5mm
- CAMBRA:
 - Caries Risk High
 - ATP Score: 2851 (from last POE 3/2023)
 - pH 6



PANO



Dental Findings

#1 O(a)

#2 PFM

#3 missing

#4 RCT, PFM abut

#5 CZ crown

#6 PFM crown

#7 Implant, PFM cement crown

#8 PFM crown

#9 Attrition

#10 Attrition

#13 Attrition

#14 missing

#15 O(a)

#17 O(c)

#18 MO(a)

#20-27 Attrition

#28 OB(c)

#29 B Abfraction

#30 missing

#31 missing

#32 MO(c)

TX OPTIONS

TX OPTION 1

- Phase 1: Diagnostic/Prophylactic
Resident Review
SPT
CAMBRA
- Phase 2: Operative
#17 O GI
- Phase 3 Major Restorative
#6 PFM Replacement
#12 CZ Crown
#30 CZ Crown
- Unphased Endo/Surgical
#12 Implant Placement
#30 Implant Placement

TX OPTION 2

- Phase 1 Diagnostic/Prophylactic
Resident Review
SPT
CAMBRA
- Phase 2 Operative
#17 O GI
- Phase 3 Major Restorative
#6 PFM Replacement
#11-x-13 FPD
#29-x-31 FPD

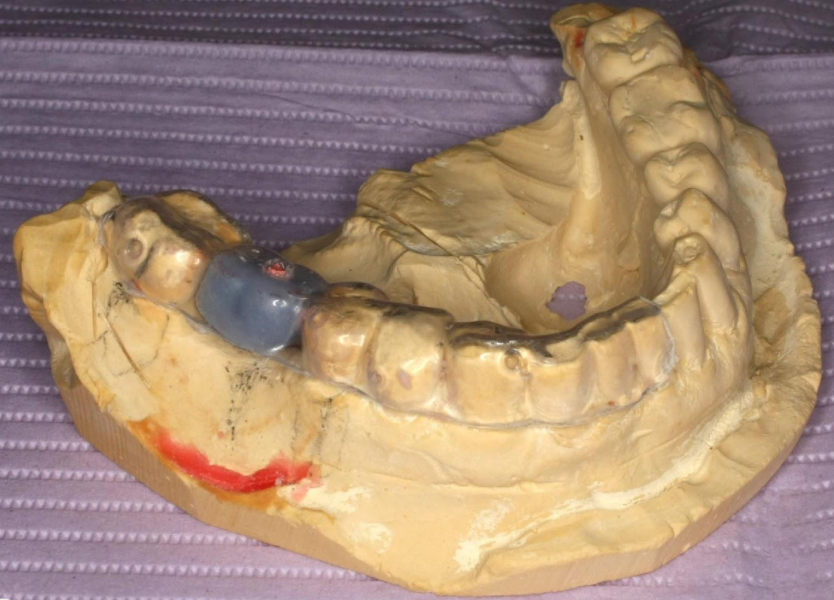
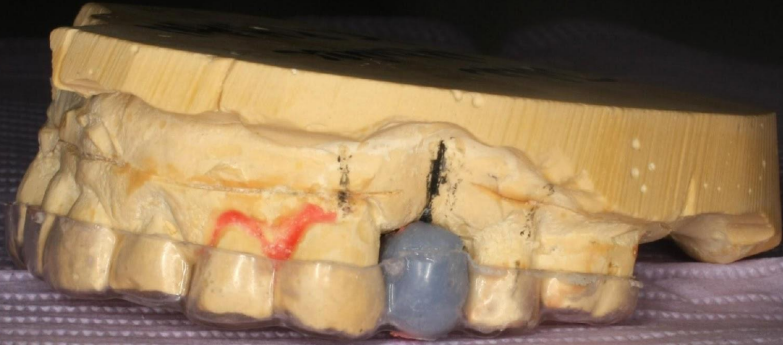TX OPTIONS

TX OPTION 1

- Phase 1: Diagnostic/Prophylactic
Resident Review
SPT
CAMBRA
- Phase 2: Operative
#17 O GI
- Phase 3 Major Restorative
#6 PFM Replacement
#12 CZ Crown
#30 CZ Crown
- Unphased Endo/Surgical
#12 Implant Placement
#30 Implant Placement

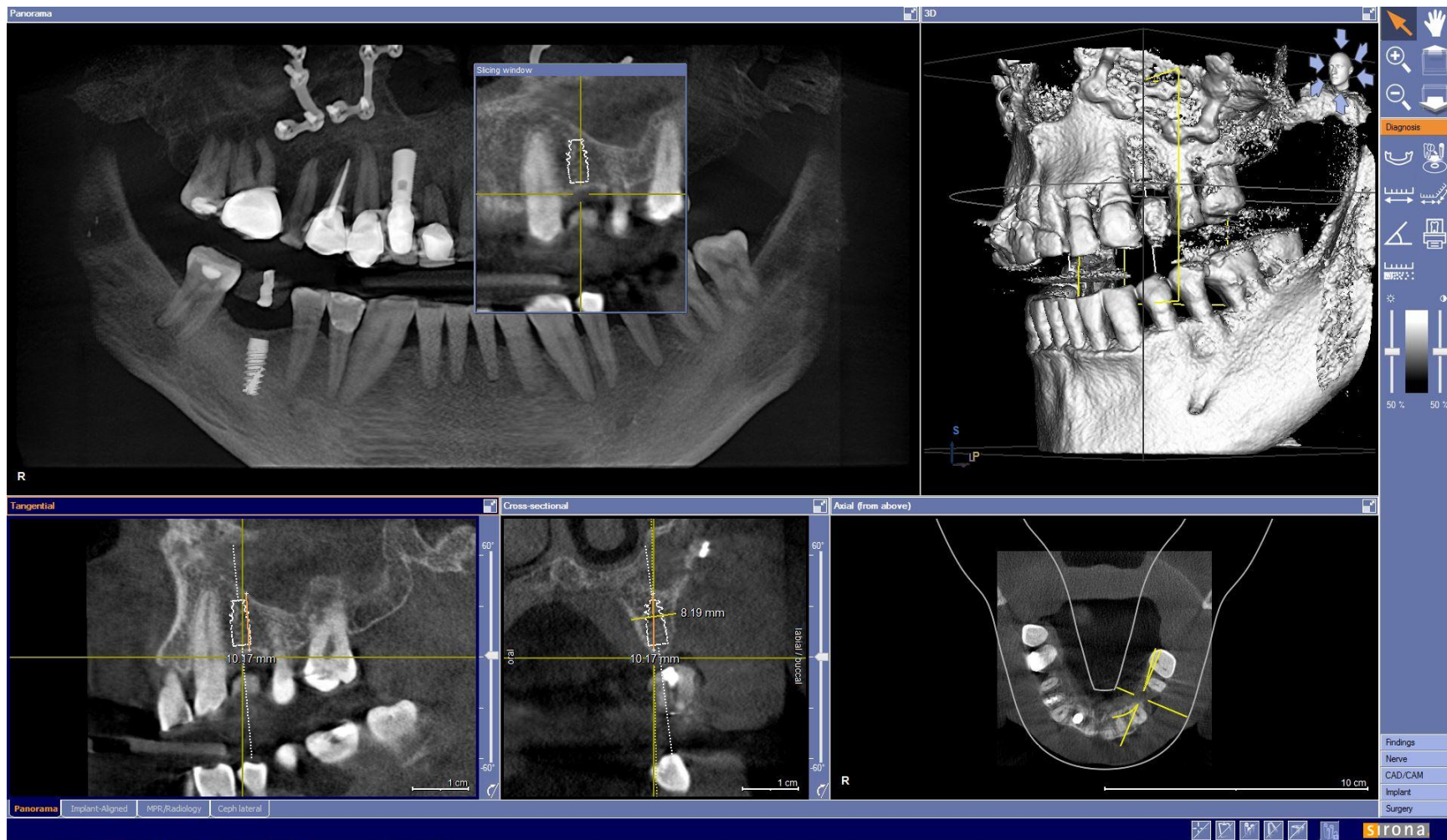
TX OPTION 2

- Phase 1 Diagnostic/Prophylactic
Resident Review
SPT
CAMBRA
- Phase 2 Operative
#17 O GI
- Phase 3 Major Restorative
#6 PFM Replacement
#11-x-13 FPD
#29-x-31 FPD



RADIOGRAPHIC STENTS


#12



IMPLANT SELECTION

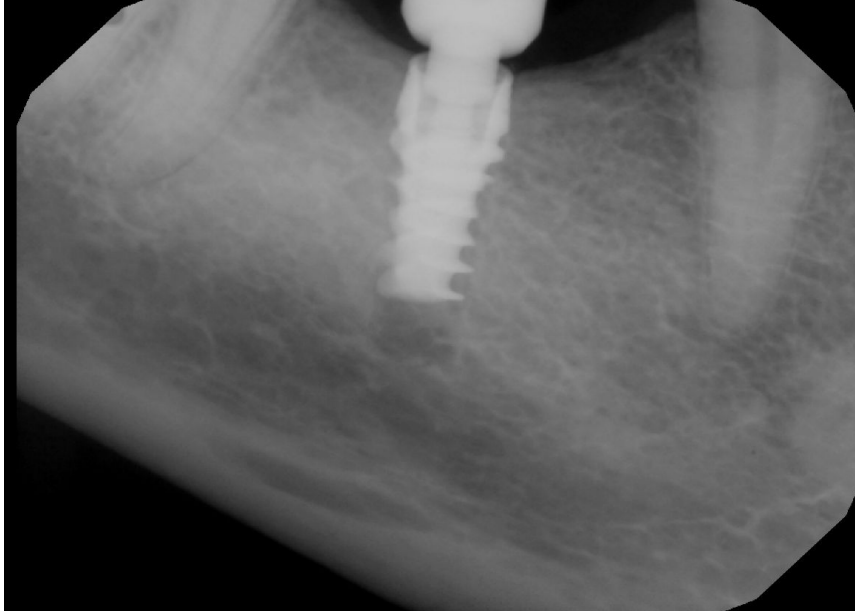
- Nobel Active
Internal Conical
Connection
Textured Collar
- #30
NobelActive RP 4.3 x
10mm
- #20
NobelActive RP 4.3 x
8.5mm

NP 3.5
RP 4.3
RP 5.0

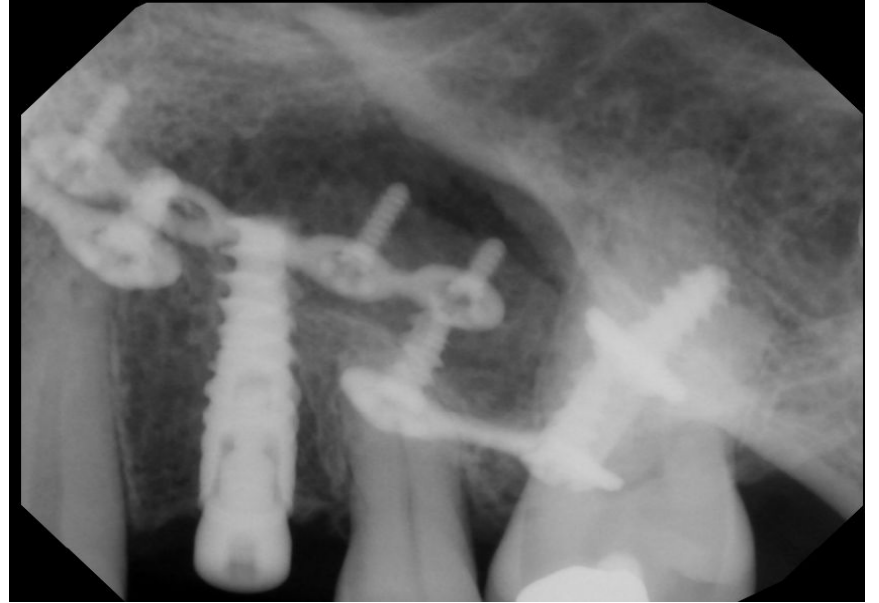


Post Op Plans

- 1) 1 week FU to assess healing and osseointegration**
- 2) 2 phase implant placement
3-4 months healing before crown placements**
- 3) During waiting period fabrication of #6 crown**

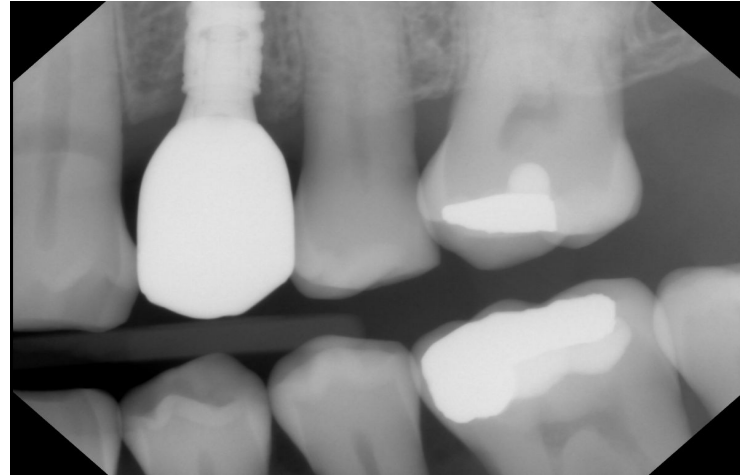
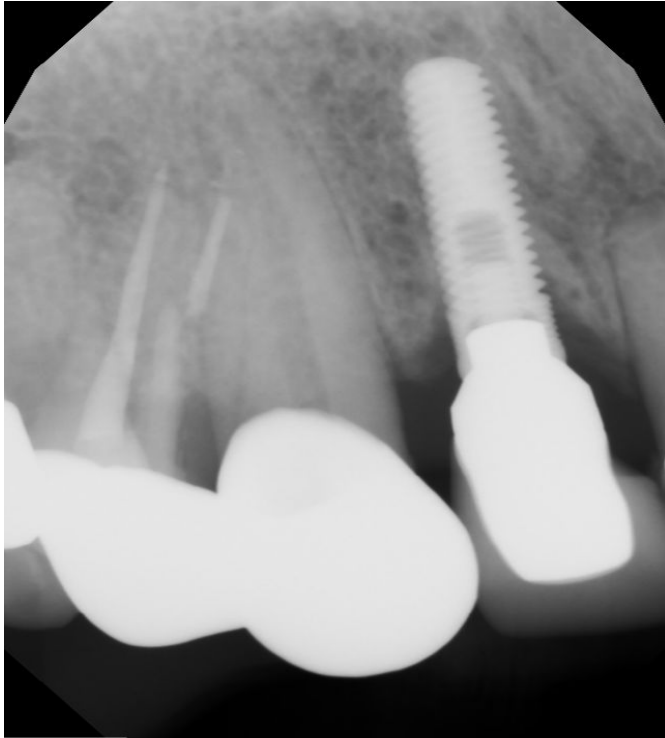

#30

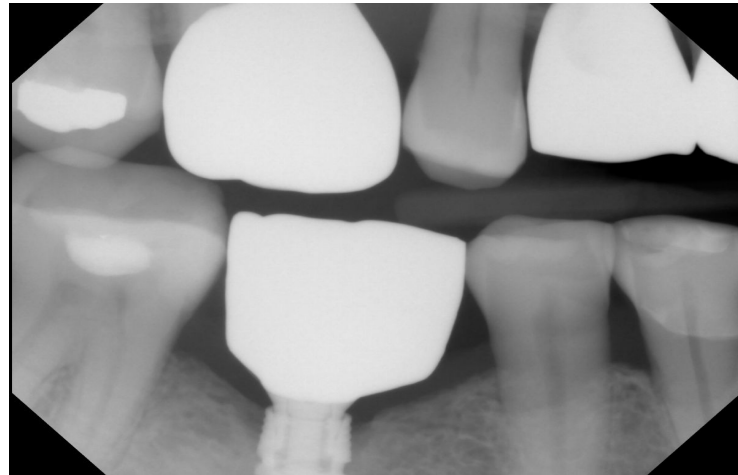


#12

**#6
layered
zirconia
crown**



#12



#30

**Pt was
informed to
keep these
area clean
due to
generalized
perio**

Questions?

**Special thank you to the Union City
Team, Dr. Allen Wong, Dr. Debra
Woo, Dr. William Lee, and Dr.
Michael Beckley**