



---

Excellence Day

26th Annual Pacific Excellence Day (2024)

---

May 8th, 2:15 PM - 5:00 PM

## Smile Restoration

Cameron Goodin  
*University of the Pacific*

Follow this and additional works at: <https://scholarlycommons.pacific.edu/excellence-day>



Part of the [Dentistry Commons](#)

---

Goodin, Cameron, "Smile Restoration" (2024). *Excellence Day*. 1.  
<https://scholarlycommons.pacific.edu/excellence-day/2024/events/1>

This Presentation is brought to you for free and open access by the Arthur A. Dugoni School of Dentistry at Scholarly Commons. It has been accepted for inclusion in Excellence Day by an authorized administrator of Scholarly Commons. For more information, please contact [mgibney@pacific.edu](mailto:mgibney@pacific.edu).

# OKU Sutro Excellence Day Project Cover Sheet

## Project Title

Smile Revitalization

## Full name(s) and class year(s) of all project collaborators

*Example: Jane Smith, DDS 2022; John Smith, DDS 2022*

Cameron Goodin, DDS 2024  
Sandy McLaren - 2B GPL  
Karen Schulze - 2B Floor Faculty

## Project Category

DDS/IDS - Clinical Awards: CAD CAM



## Enter your abstract text here (max 300 words)

I have a patient with Sjögren's syndrome who presented to the clinic wanted to "fill her missing spaces and be able to smile again".

She presented with decay/recurrent decay on almost every single tooth. We needed to address her dry mouth prior to proceeding with any restorative procedures. After working with her Primary, changing some medications, reinforcing oral hygiene habits, her oral health looked like a completely new person. We then proceeded to start with her restorative treatment.

We decided on doing monolithic zirc crowns on: #5-14, & 28. We started with #5,28, and then #14 via traditional impressions to keep posterior stops. Then we prepped and temped #6-13 at the same time and scanned with an itero for a digital final impression.

Special thank you to:  
Dr. Sandy McLaren - 2B GPL  
Dr. Karen Schulze - 2B Floor Faculty  
Carlos Correa - PSL


This case could not have been done without the help of these three individuals. Thank you for your time, patience, and mentorship.



# Excellence Day Smile Revitalization

Cameron Goodin (D24248)

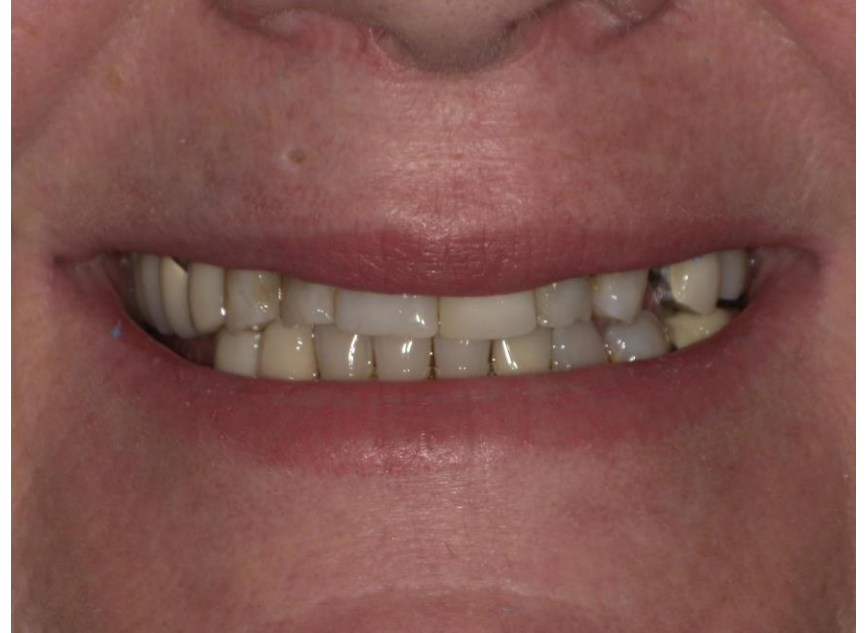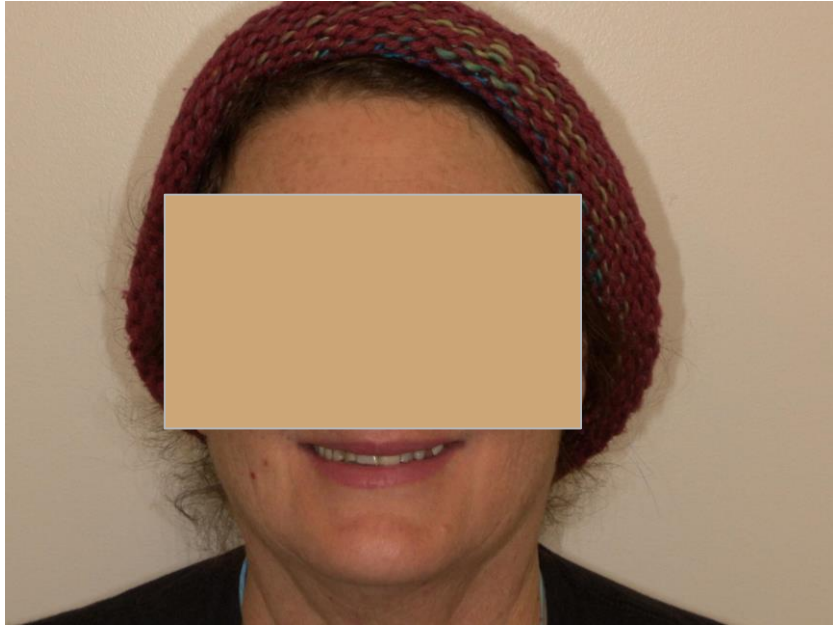A. Johnson  
Pt ID: 1191273



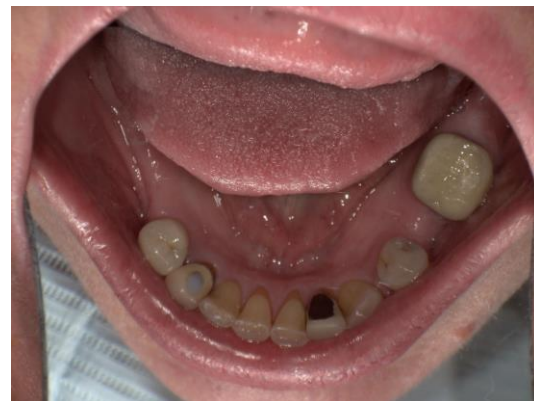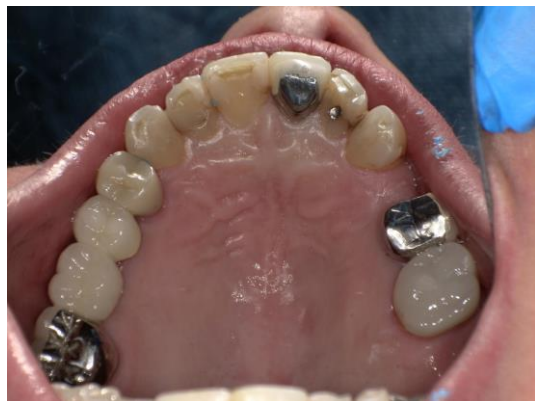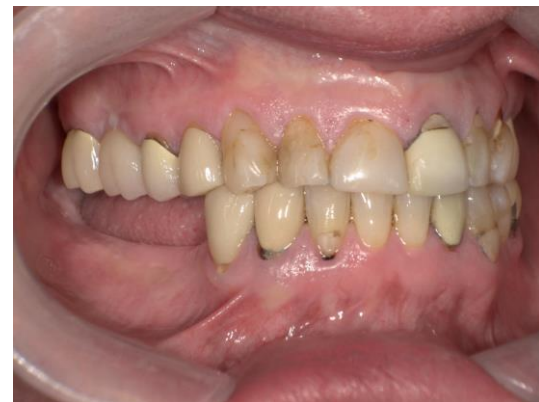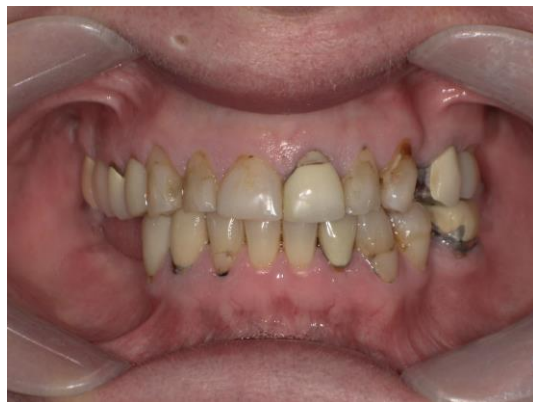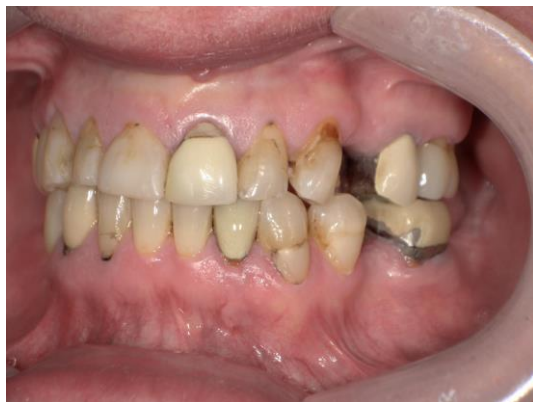# Case Summary

- 58 yo Female
- CC: "I want to fill missing spaces with implants, and want to make smile look better."
- Med Hx: Sjogren's syndrome, Severe anxiety, High blood pressure
- Medications: Losartan 25 mg, Hydrochlorothiazide 12.5 mg, Hydroxyzine 25 mg (prior to dental Appts), Sertraline 25 mg.
- ALL: Clindamycin - 5 years ago, lower half of body broke out in hives, Norco/Vicodin - Nausea/vomiting and stomach sensitivity
- PSH: None reported
- Social Hx: Pt has had severe dental anxiety in the past when visiting the clinic, Pt reports PTSD from previous periodontal surgery.
  - -EtOH, -Tobacco, -Marijuana

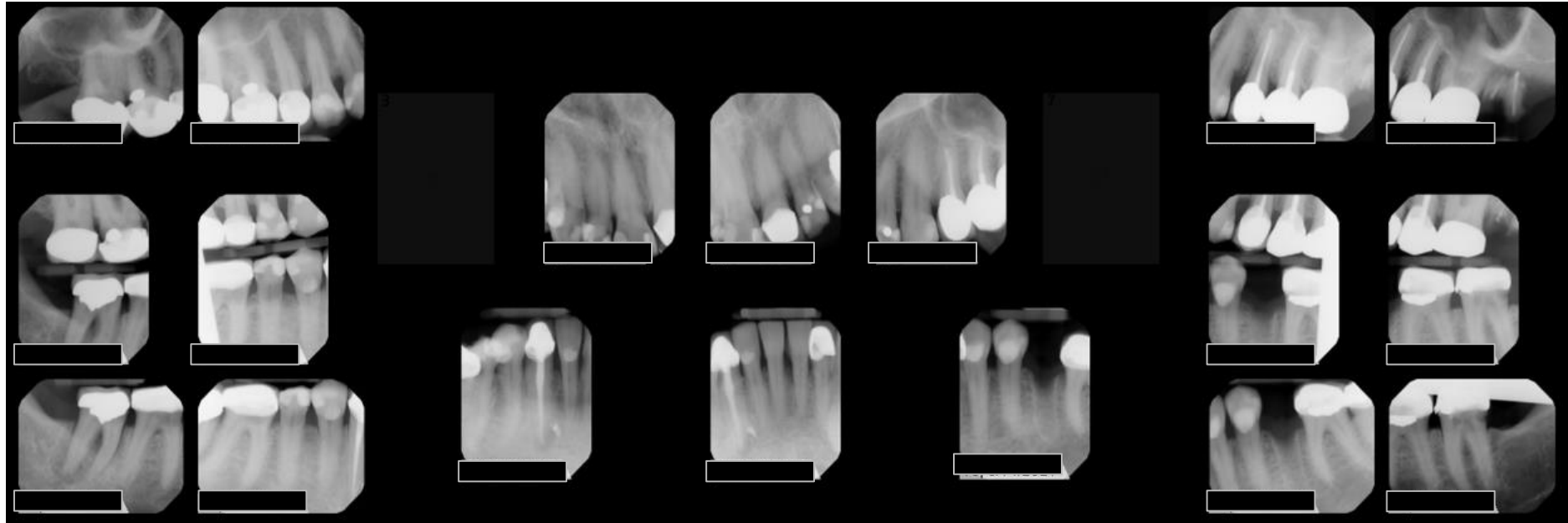
A. Johnson -Pt ID: 1191273



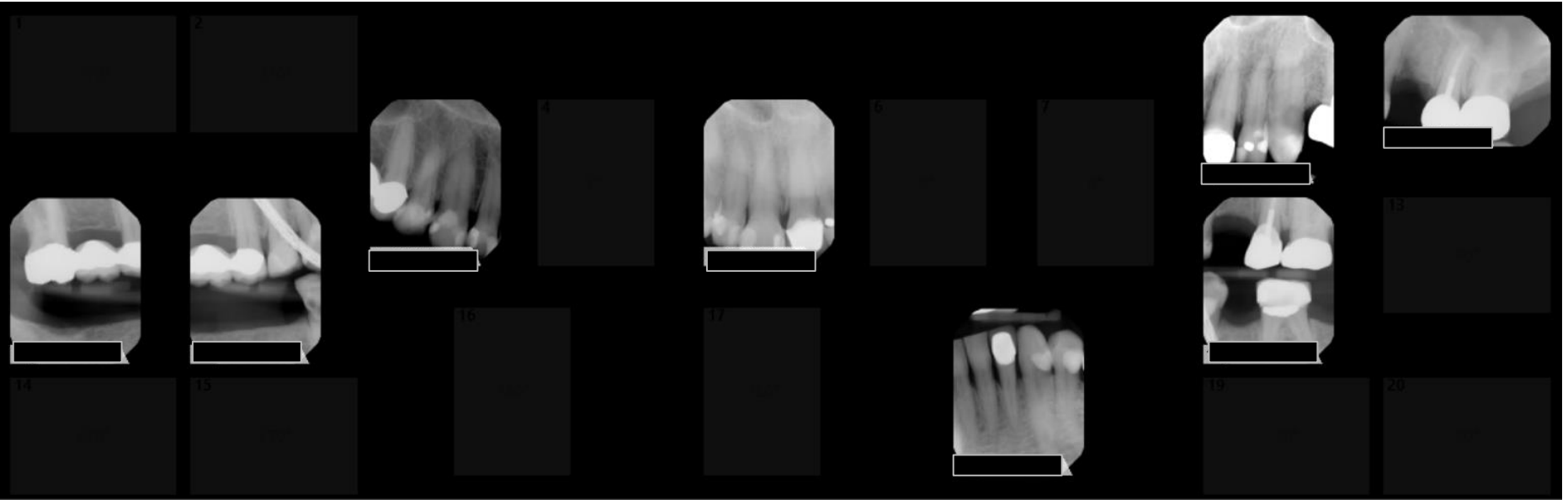
# Initial Photos



# Initial FMX: Radiographs

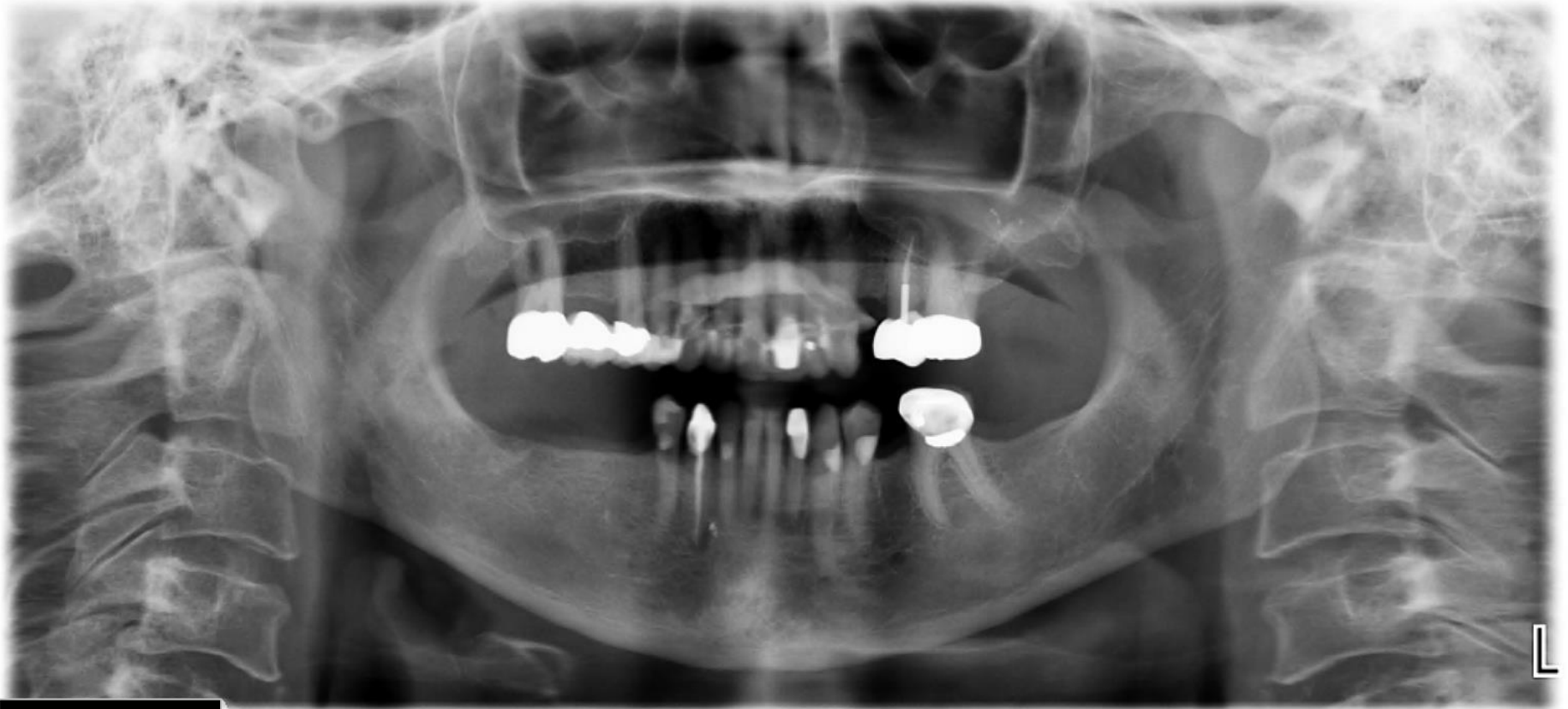


# More Recent Anterior PA's





# Panoramic Radiograph





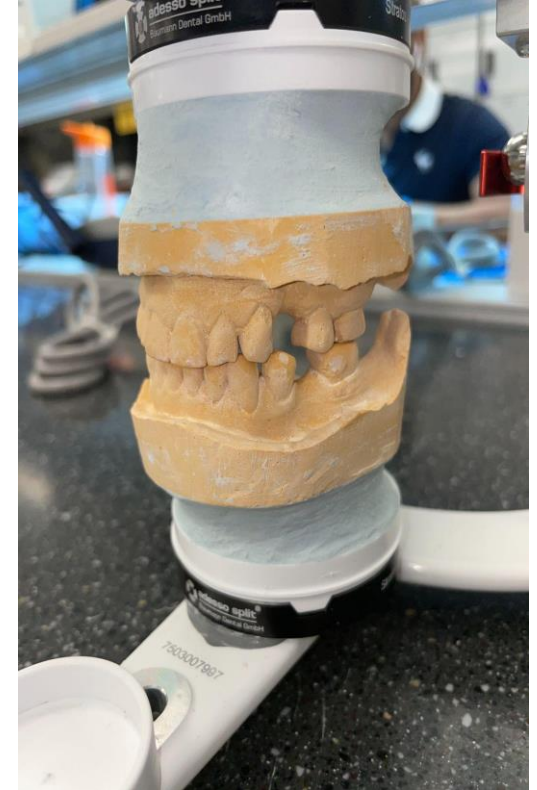
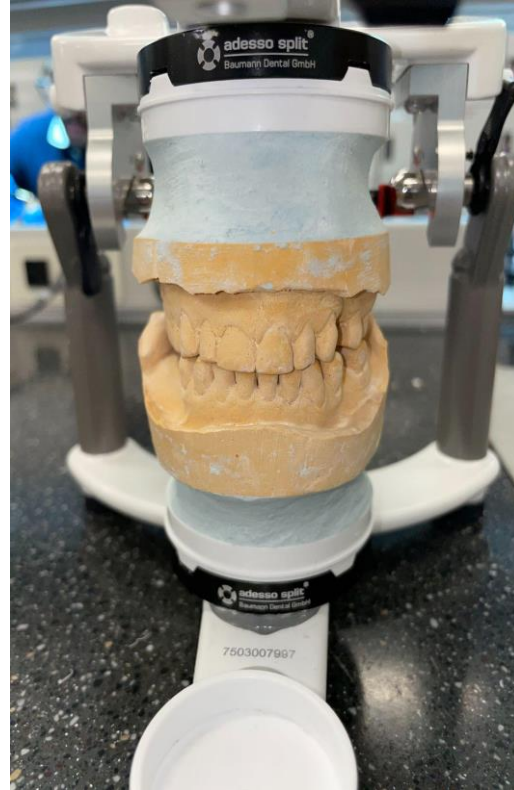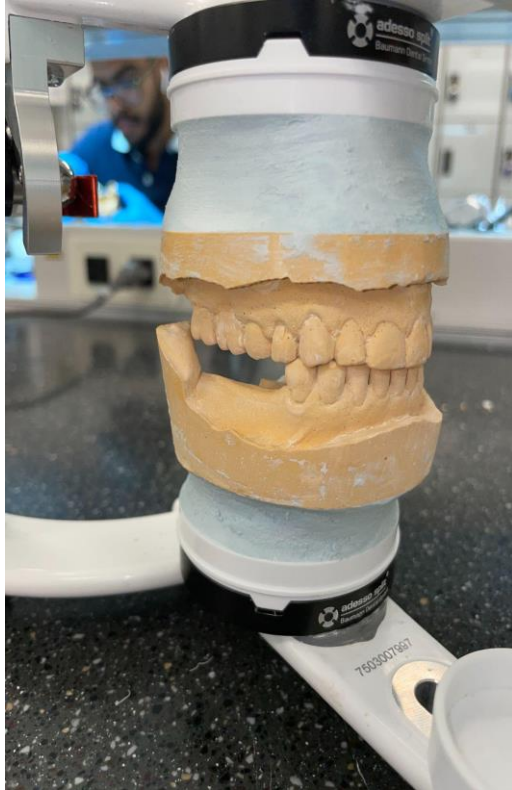# Periodontal Findings/Plaque Index

- Diagnosis: Stage II Grade B localized periodontitis on UR and generalized healthy gingiva on a reduced periodontium
- Plaque index: 1.2
- Reported at home OH habits
  - Brush 1x/daily with Colgate in the AM
  - Floss maybe 1x/week
  - ACT mouthwash before bed

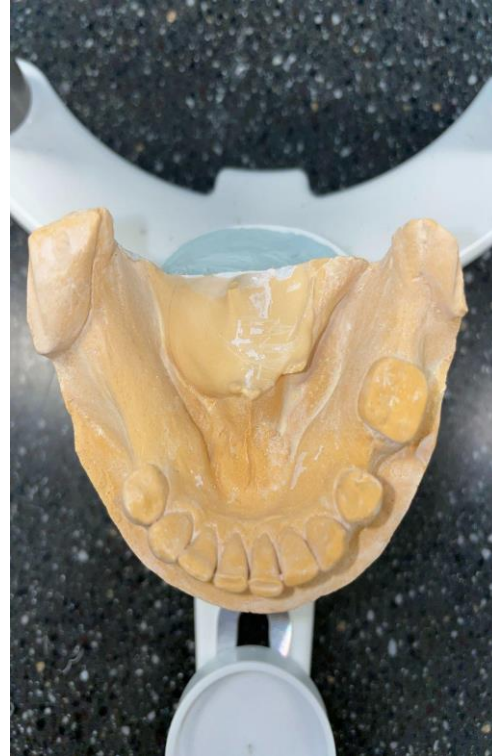
# Caries Risk Assessment

- Disease Indicator: Recurrent caries on almost every restoration in her mouth
- Diagnosis: Extreme caries risk
- Reasoning: Xerostomia (Sjogren's syndrome)

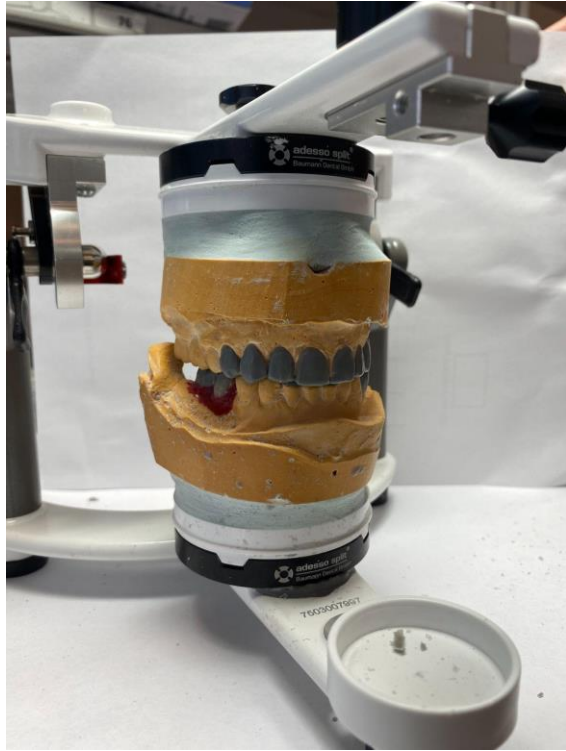# Diagnostic Models



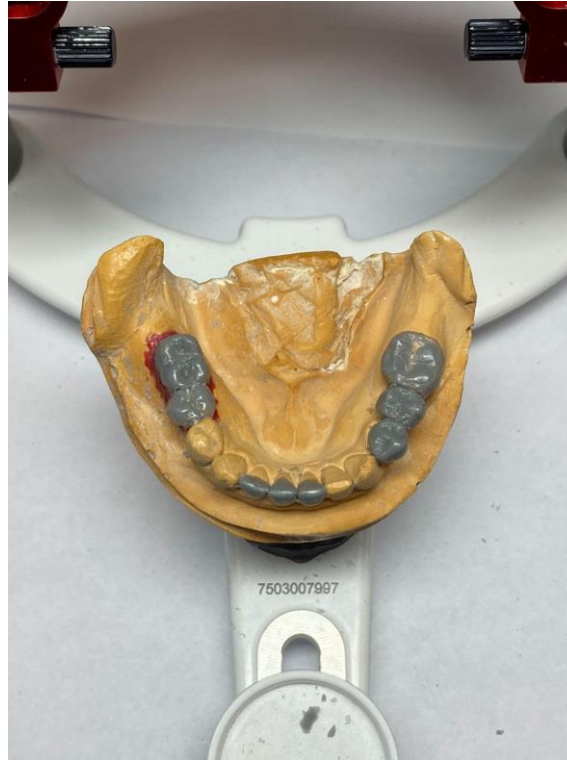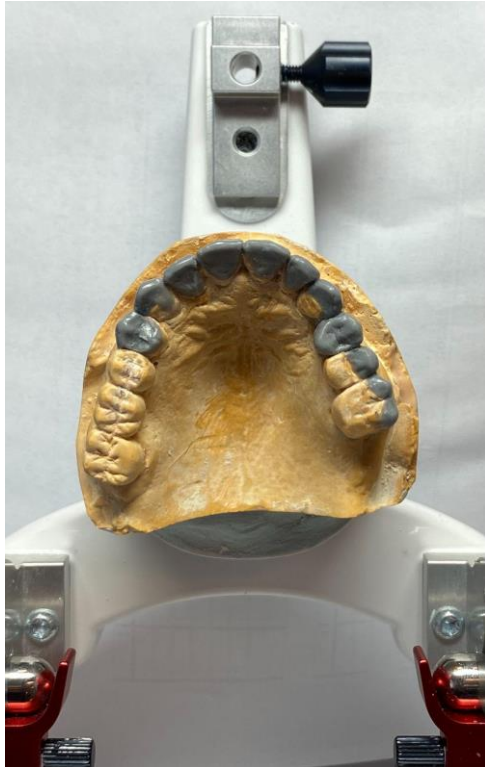# Diagnostic Models



# Smile Design/Ideal Final



# Smile Design/Ideal Final







# Treatment Plan: Restoring the Anterior with Crowns



# Disease Control Phase

1. SRP UR + Prophy + OHI + ITE
  2. Carifree maintenance rinse
  3. Carifree Boost spray
  4. Prevident 5000 toothpaste
  5. Core buildups: #5, 14, 6-11, & 13, 14, 23 & 28 as needed
  6. #21 DOBc, #22 MBc, 26 Fc, 27 Fc
- #13 and #27 Previously Treated RCTs - CBCT to evaluate PARL - lesions present on both.
    - Endo consulted - No need for Re-treatment until Pt becomes symptomatic, then apicoectomies may be necessary - continue to monitor

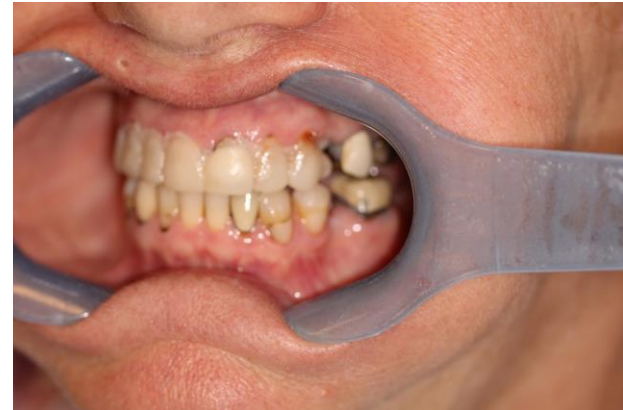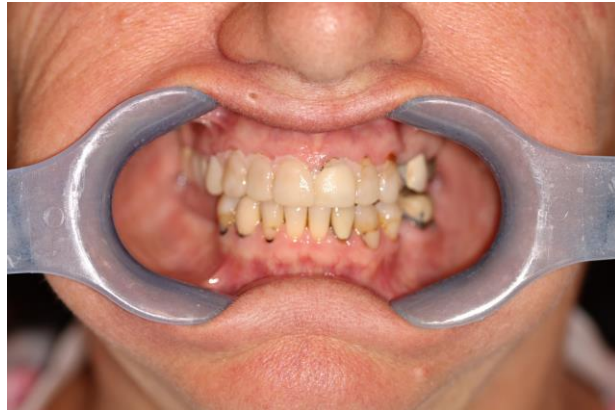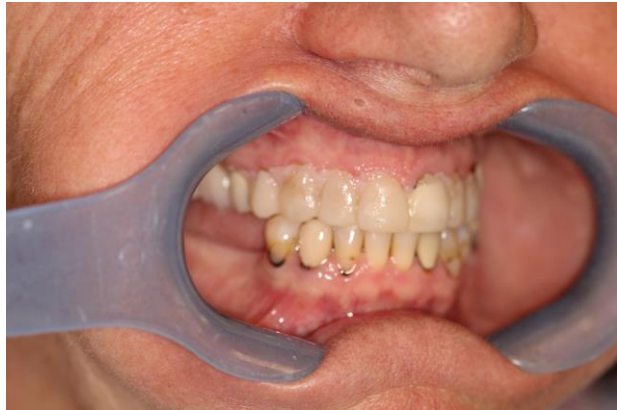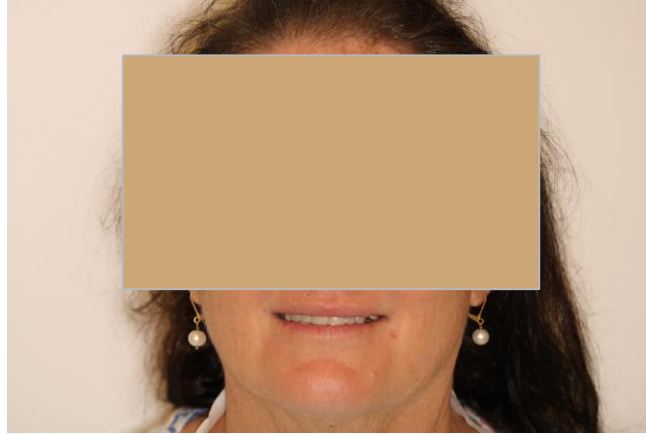# Reconstructive Phase:

1. Mono-Zirc Crowns #5,14,28 to maintain posterior stops
2. Mono-Zirc Crowns #6-13.
3. Mono Zirc Crown #23
4. Implants and BG at #20, 29 and #31 for Implant Bridge

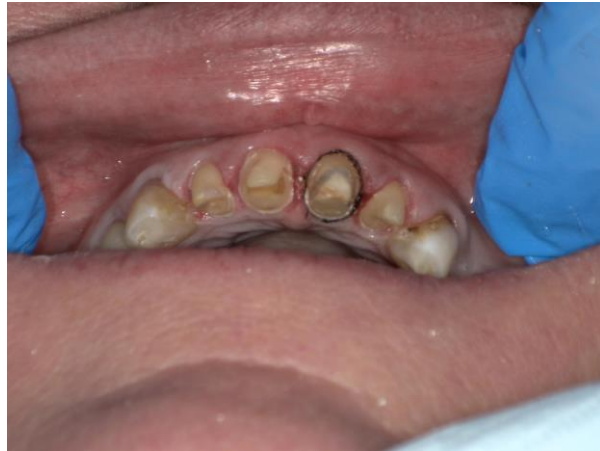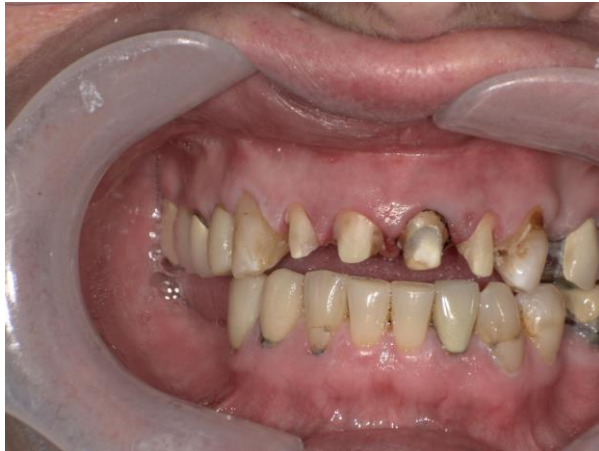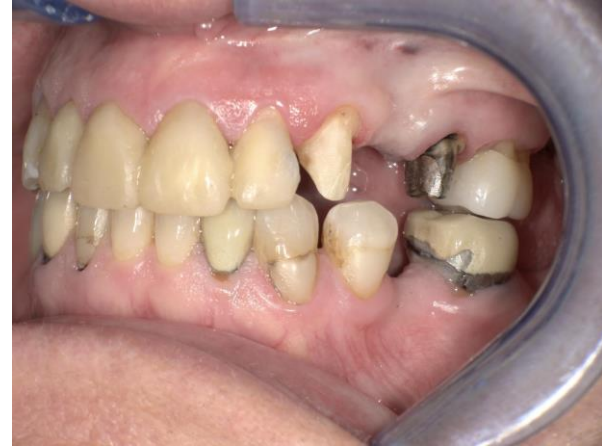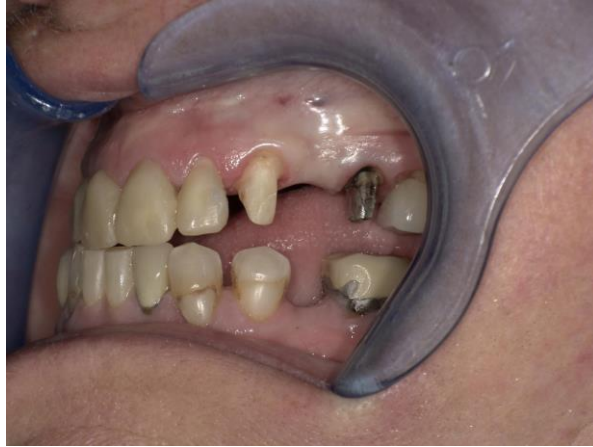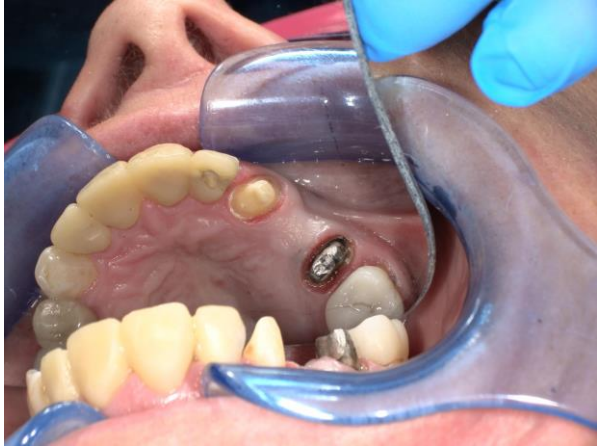# Maintenance Phase

1. Maxillary Night Guard
2. SPTs 4x/Year
3. Refill CAMBRA products as needed
4. Annual Exam

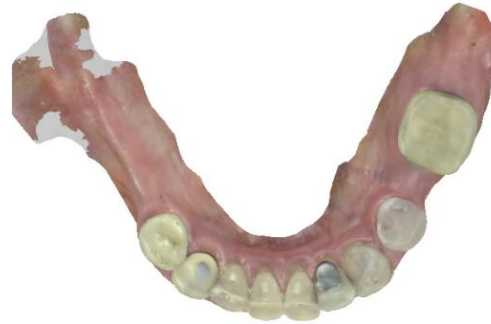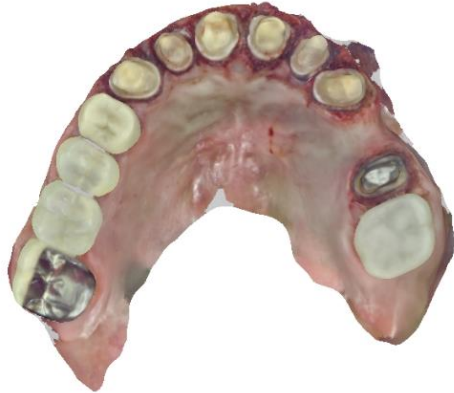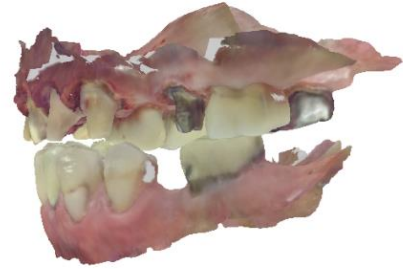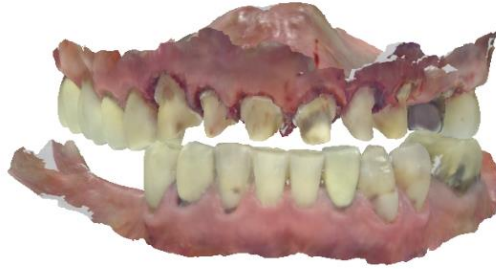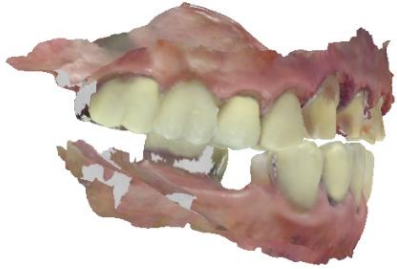# Smile Design



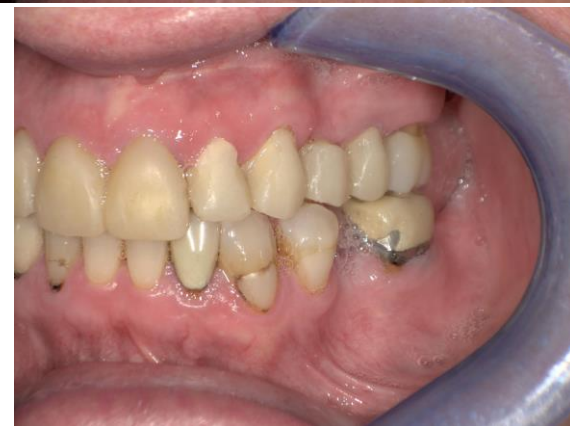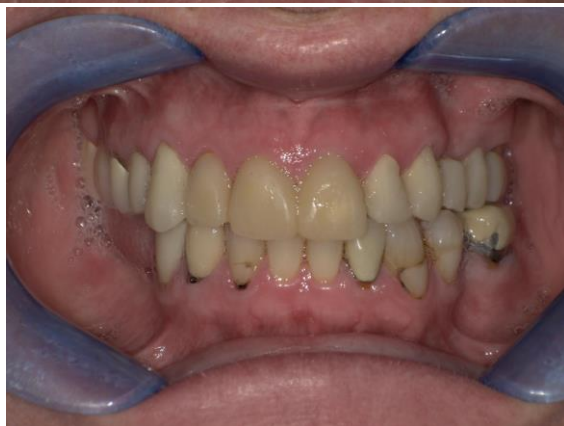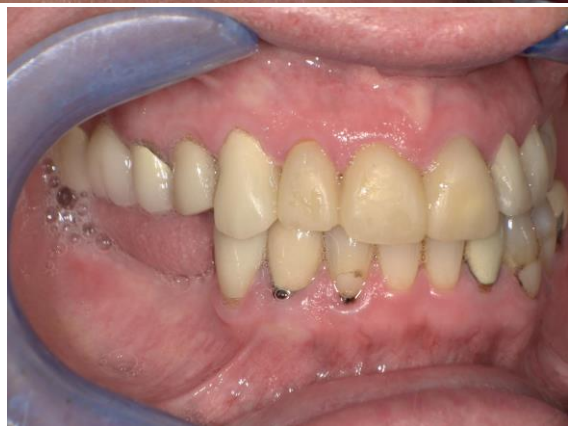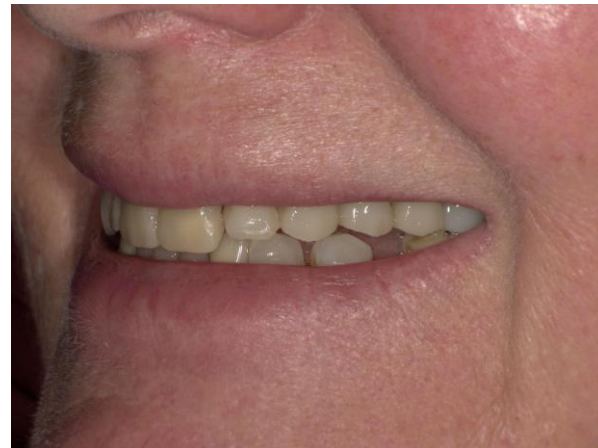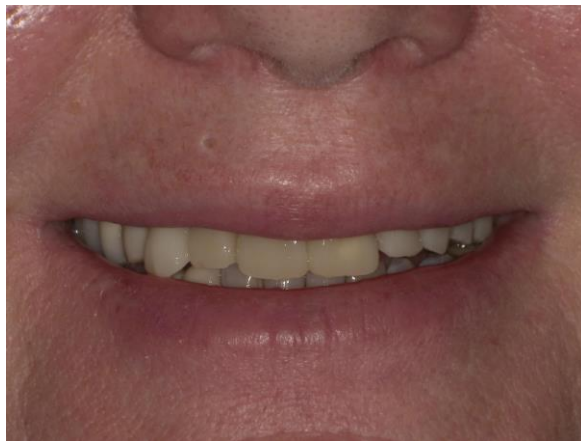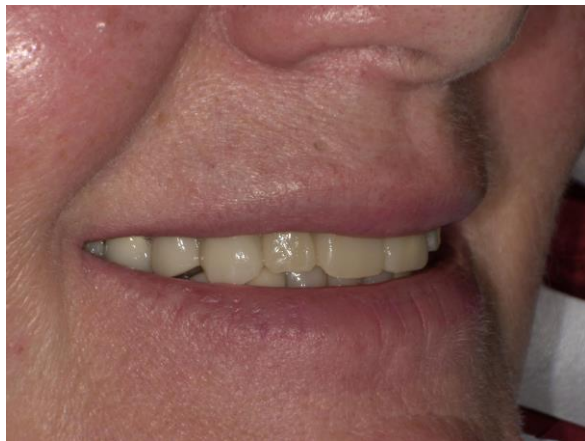# Photos



# iTero Scan Overview



# Temporaries



# Final Restorations

... Loading...



# A Special Thank You to:

- Dr. Sandy McLaren - 2B GPL
- Dr. Karen Schulze - 2B Floor Faculty
- Carlos Correa - PSL
- Marceyl Jones- 2B Scheduler
- Dispensary Staff
- Colton Gruhler - D24250

# References

- Smiley, Christopher J et al. "Systematic review and meta-analysis on the nonsurgical treatment of chronic periodontitis by means of scaling and root planing with or without adjuncts." *Journal of the American Dental Association (1939)* vol. 146,7 (2015): 508-24.e5. doi:10.1016/j.adaj.2015.01.028
- Leinonen J, Vähänikkilä H, Raninen E, Järvelin L, Näpänkangas R, Anttonen V. The survival time of restorations is shortened in patients with dry mouth. *Journal of Dentistry*. 2021;113:103794. doi:https://doi.org/10.1016/j.jdent.2021.103794
- Albashaireh, Zakereyya S.M., et al. "Two-Body Wear of Different Ceramic Materials Opposed to Zirconia Ceramic." *The Journal of Prosthetic Dentistry*, vol. 104, no. 2, 2010, pp. 105–113., [https://doi.org/10.1016/s0022-3913\(10\)60102-3](https://doi.org/10.1016/s0022-3913(10)60102-3).
- Mengatto CM, Coelho-de-Souza FH, de Souza Junior OB. Sleep bruxism: challenges and restorative solutions. *Clin Cosmet Investig Dent*. 2016 Apr 22;8:71-7. doi: 10.2147/CCIDE.S70715. PMID: 27217798; PMCID: PMC4853149.
- Dioguardi M, Stellacci C, La Femina L, et al. Comparison of Endodontic Failures between Nonsurgical Retreatment and Endodontic Surgery: Systematic Review and Meta-Analysis with Trial Sequential Analysis. *Medicina (Kaunas)*. 2022;58(7):894. Published 2022 July 4. doi:10.3390/medicina58070894