

# Inferior Alveolar Nerve Block in Pediatric Patients: Quantitative Assessment

## Introduction

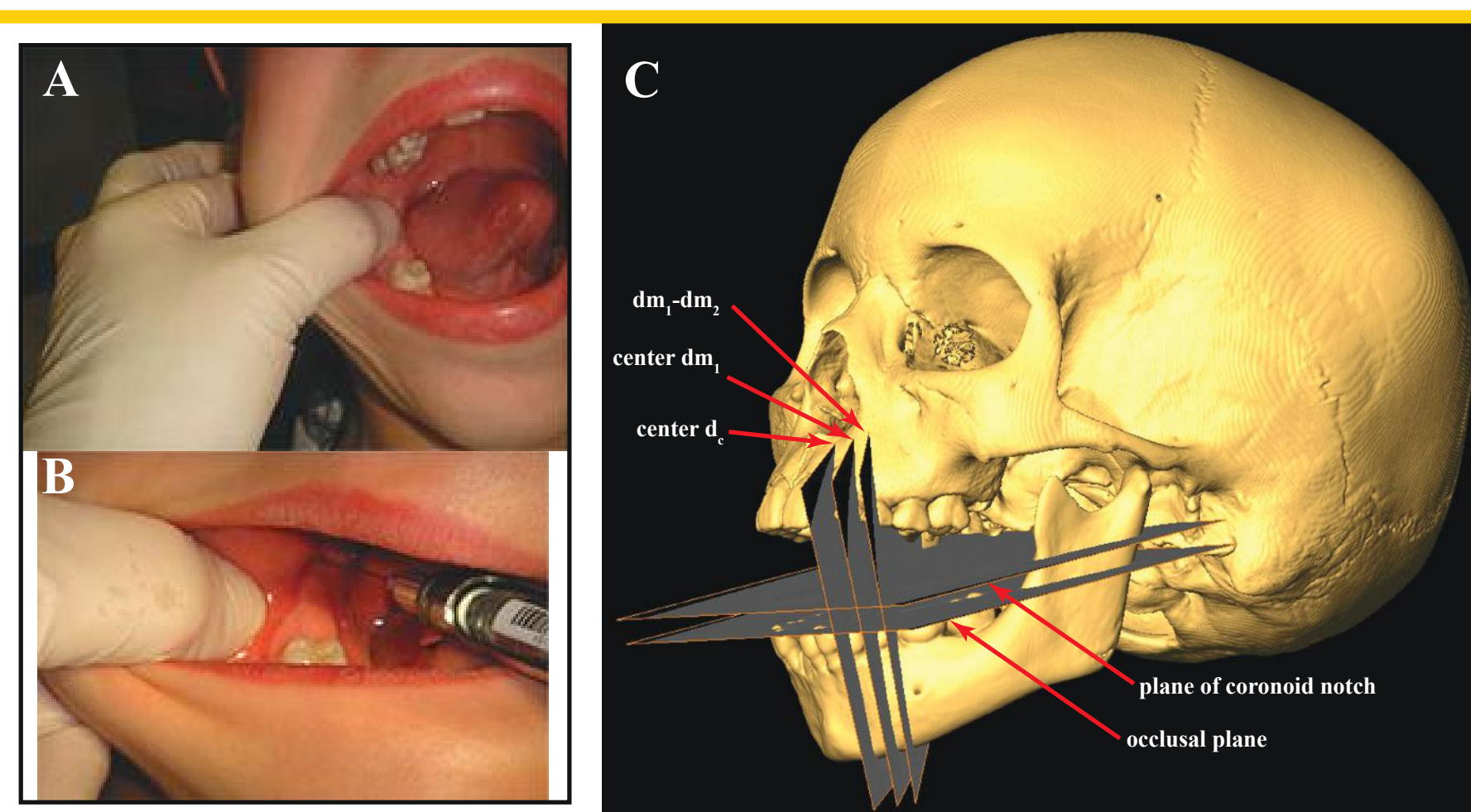
Local anesthetic overdose has resulted in a disproportionately high number of deaths and serious morbidity in children, leading to the erroneous assumption that the anesthetic is more toxic in children than adults.

Because children/juveniles are likely to be fearful of having an injection, one endeavors to ensure a complete nerve block with a single attempt. Problems can arise, however, when further injections are required to achieve a complete block of the nerve.

Recommended doses are appropriate for a complete loss of sensation in the area supplied by the nerve. However, it is imperative that the clinician insert the needle in the proper location to maximize the anesthetic effect.

Currently, there is a lack of quantitative assessments of techniques employed in inferior alveolar nerve blocks in pediatric patients.

To assess outcomes of variations in the procedure for blocking the inferior alveolar nerve, we evaluate five sequential developmental age groups. We evaluated three starting tooth positions and two injection height landmarks. We also introduce a new needle insertion landmark, located at the junction of the posterior maxillary alveolar ridge and pterygoid plates.



**Figure 1A-C:** Oral cavity (A) and suggested injection site (B) in a 3-4.0 year old child. Image (C) shows an isosurface reconstruction of the skull of a 7-8.0 year old juvenile. All five planes examined in this work are depicted and include the occlusal and coronoid notch planes and planes through the  $d_c$ ,  $dm_1$ , and  $dm_1-dm_2$ . All of these teeth have been recommended as starting points for the injection.

## Materials and Methods

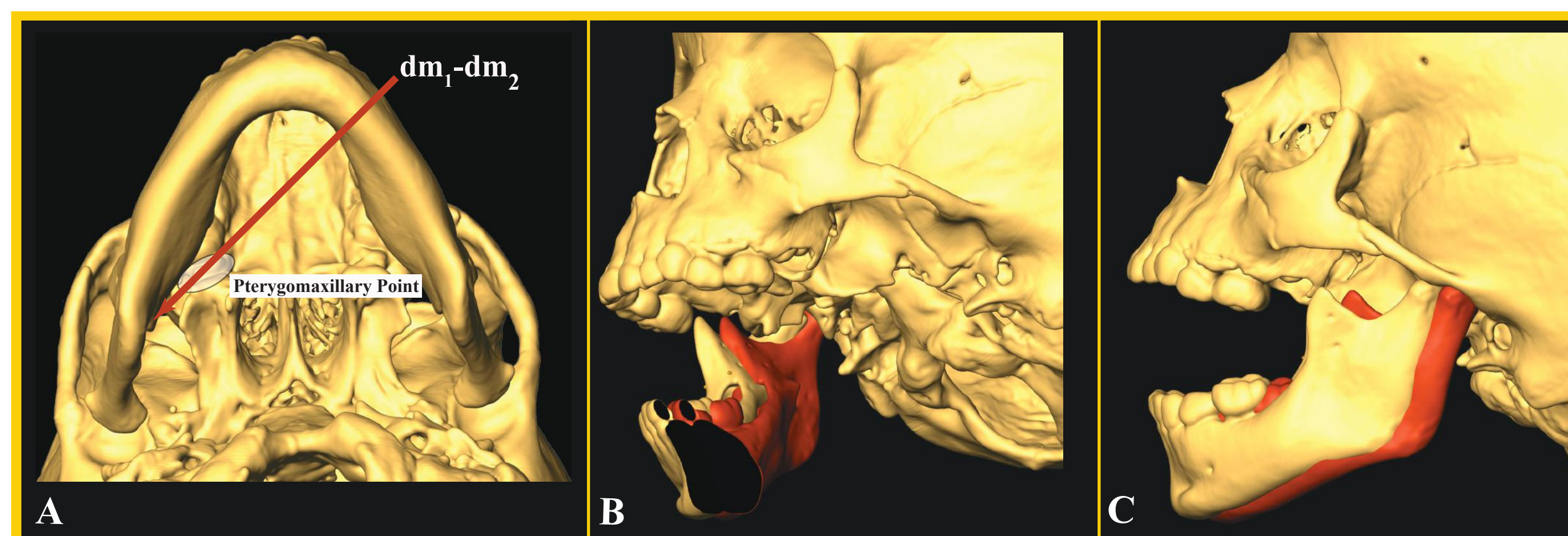
We compiled a sample of skulls ( $n=50$ ) from the Institute of Dental History and Craniofacial Study, UOP. Skulls were imaged on a GE LightScribe VCT-scanner. The data was reconstructed with a standard convolution kernel (0.3-mm isotropic voxels).

We employed the CT scans for developmental age determination. Assessment of developmental age is based solely on the amount of crown/root calcification; eruption pattern was not considered. Ages represent a mean age for all teeth and were determined with reference to Schour and Massler (1941). We generated five age delimited groups for analysis, which are as follows: 1) 2.5-3.6, 2) 4.0-4.8, 3) 5.0-5.9, 4) 6.0-6.9, and 5) 7.1-8.7 years of age. The sample size is approximately 10 per group.

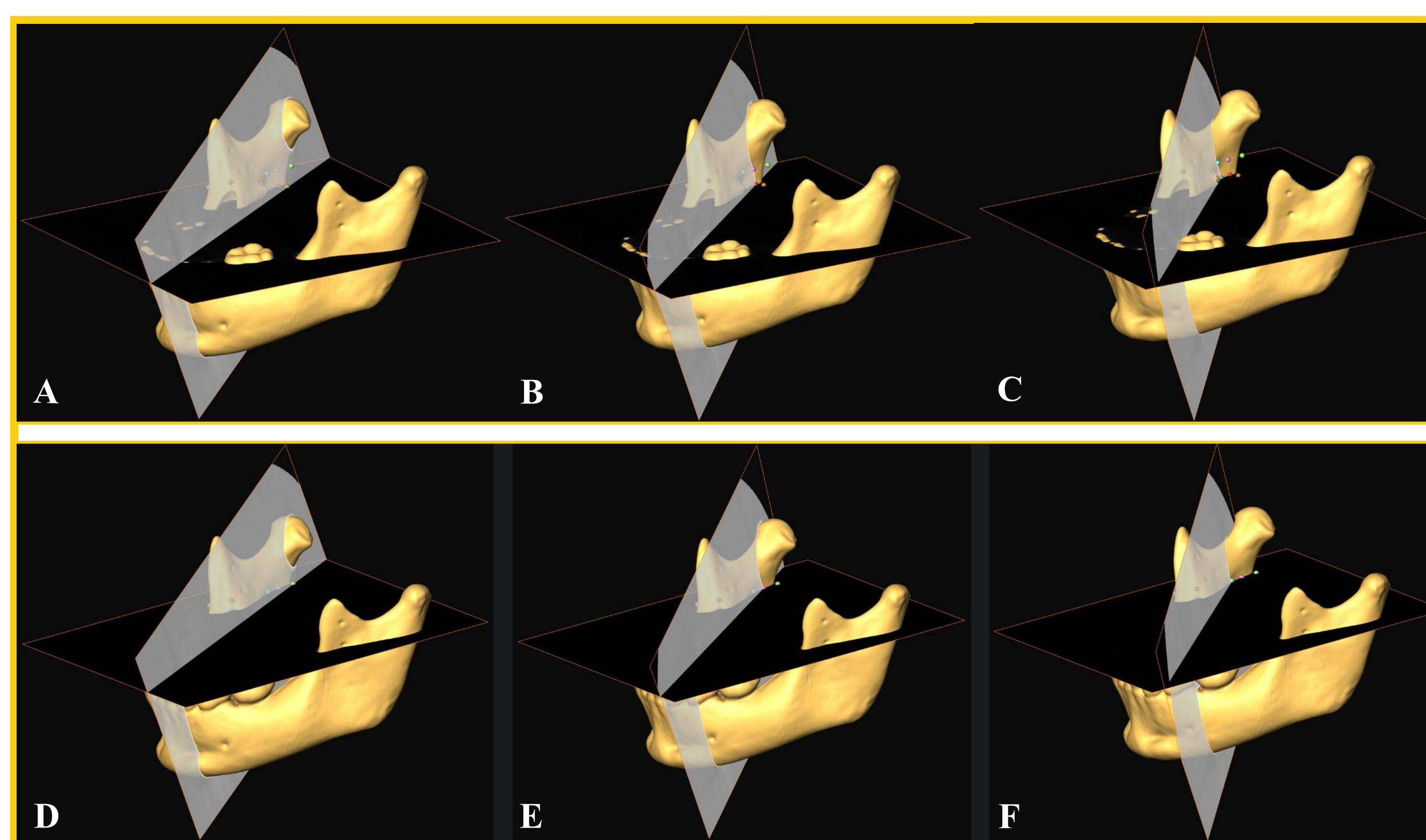
For the analysis, isosurfaces of the cranium, mandible, and a duplicate mandible were created. The two mandibles were positioned virtually, both with the condyles approximately 1.0 mm inferior to either the articular eminence or the glenoid cavity. A distance of 21 mm was maintained between the occlusal edges of the incisors, as recommended for this injection (Figs. 1-2).

To test injection height, we employed two parallel orthoslices, one at the occlusal plane and one at the height of the coronoid notch (Fig. 1). To test initial starting positions, we bisected the  $d_c$ ,  $dm_1$ , and  $dm_1-dm_2$  interproximal region with orthoslices that then pass through our pterygomaxillary point. 3D landmarks were placed at the intersection of the occlusal or coronoid notch plane and each of the planes passing through the lower teeth, to establish the position of the needles tip relative to the mandibular foramen (Fig. 3).

Height values were measured between the anterosuperior-most point of the mandibular foramen (superior lingula) and the occlusal and coronoid notch planes.

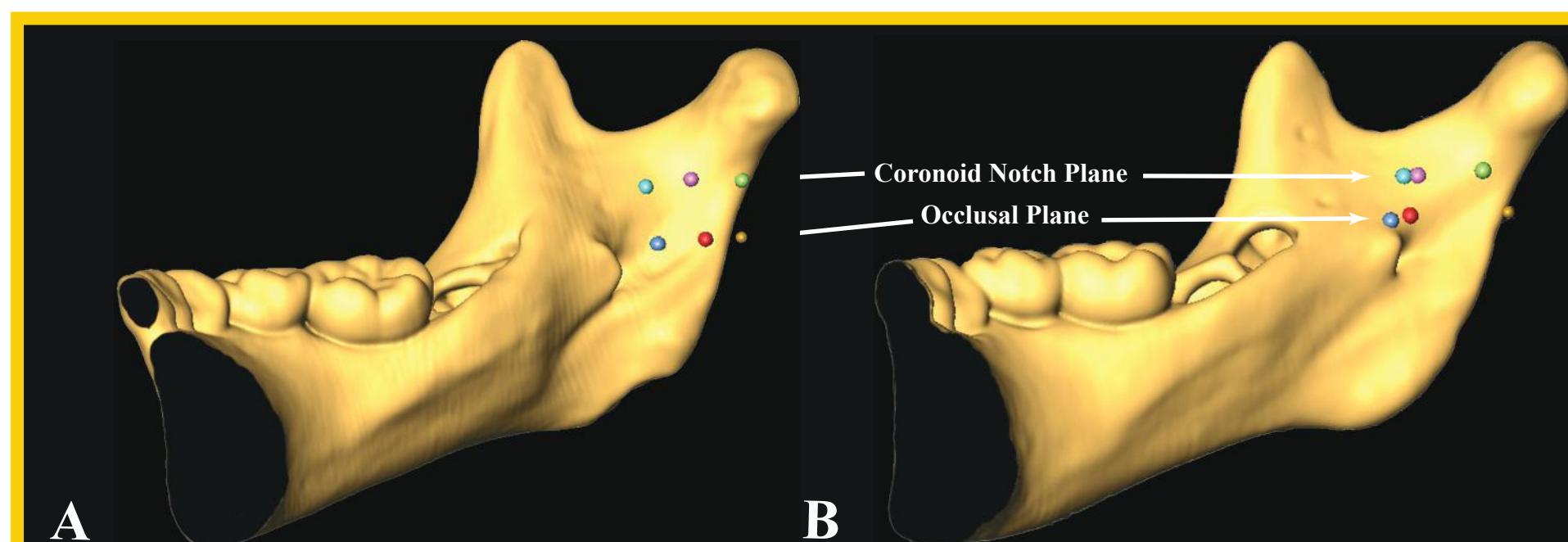


**Figure 2:** (A) Inferior view of skull showing the trajectory of the injection needle starting from the interproximal space between  $dm_1-dm_2$  and passing through the pterygomaxillary point (junction of the posterior alveolar ridge and pterygoid plates). (B-C) Mandible (red) positioned in the glenoid cavity and (yellow) on the articular eminence. Note in (B-C) the distance the mandible is translated anteriorly. In order to use the pterygomaxillary point, the mandible must be positioned on the articular eminence, due to the landmark's location on the maxilla. Positioning the mandible on the eminence is recommended whether one uses our pterygomaxillary point landmark or the so-called 'pterygomandibular raphe'.

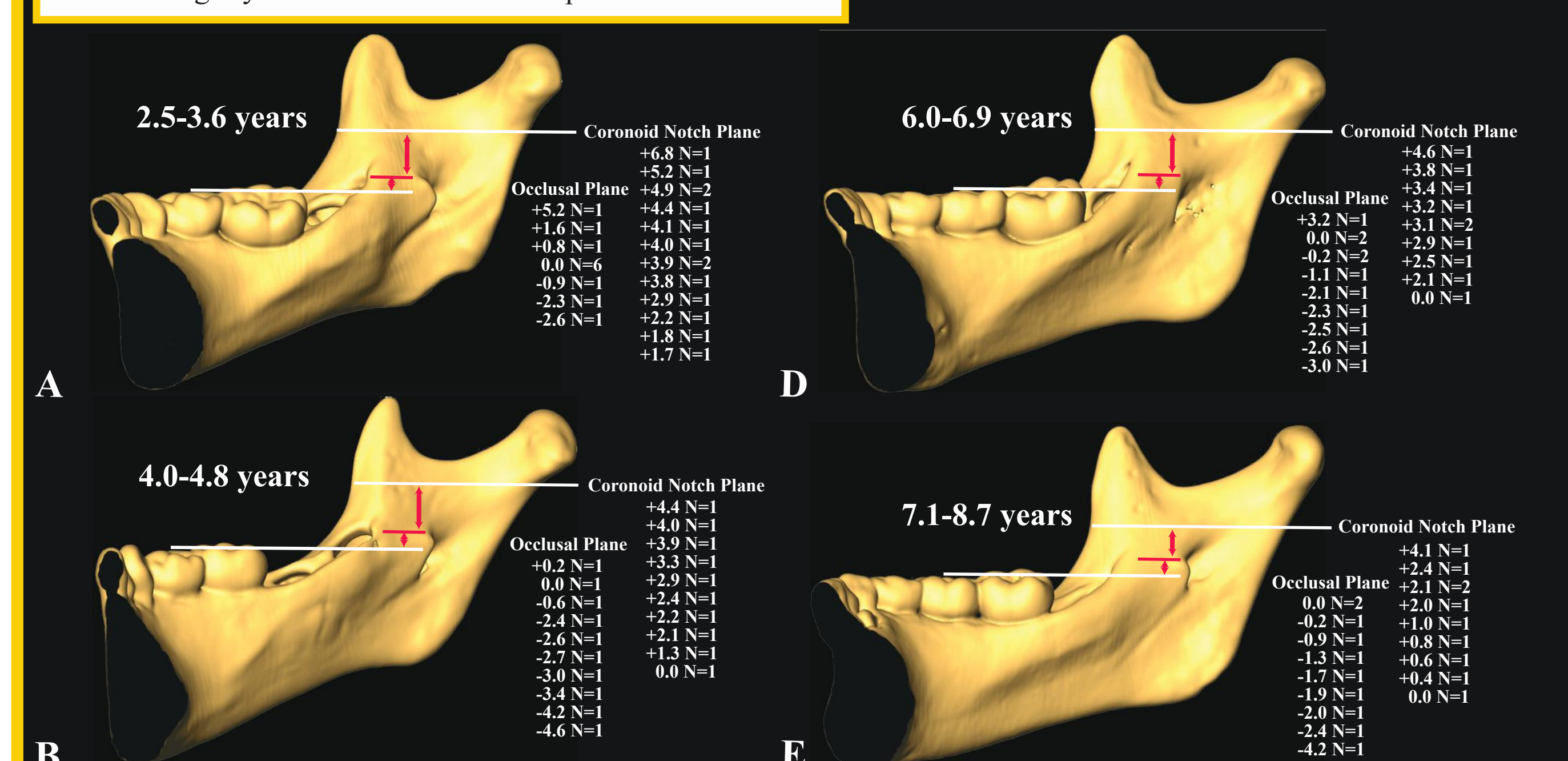


**Figure 3:** Three-quarters views of a child's mandible showing injection height and initial tooth positions. The horizontal orthoslice in (A-C) represents the occlusal plane, while in (D-F) it represents the coronoid notch plane. The vertical planes slice through the center of the deciduous canine (A and D), the deciduous first molar (B and E), and the interproximal region of the deciduous first and second molars (C and F). Observe how the intersection of the height and tooth position planes, representing the position of the needle tip, is generally low in (A-C). Also note that the point at which the tooth position plane intersects the ramus does not shift in equal increments with a change in tooth position (refer to Figure 4 below).

**Figure 4:** In (A-B) the needle tip position is depicted at the  $d_c$ ,  $dm_1$ , and  $dm_1-dm_2$  at the occlusal and coronoid notch planes. Note that the distance the needle tip translates anteriorly at the foramen is not incremental. Also, note the difference in landmark spacing between (A) and (B) even though the tooth positions are the same.



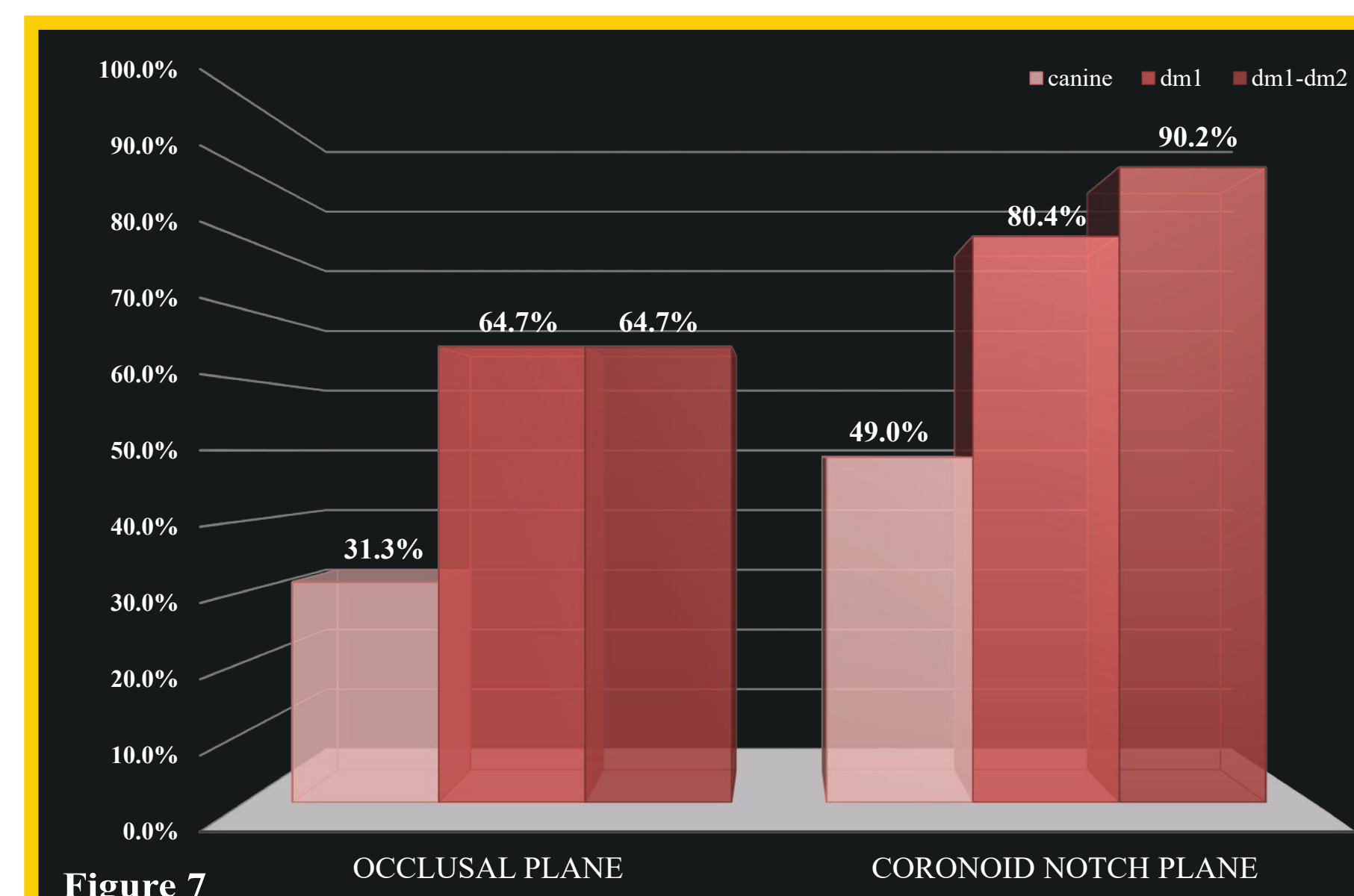
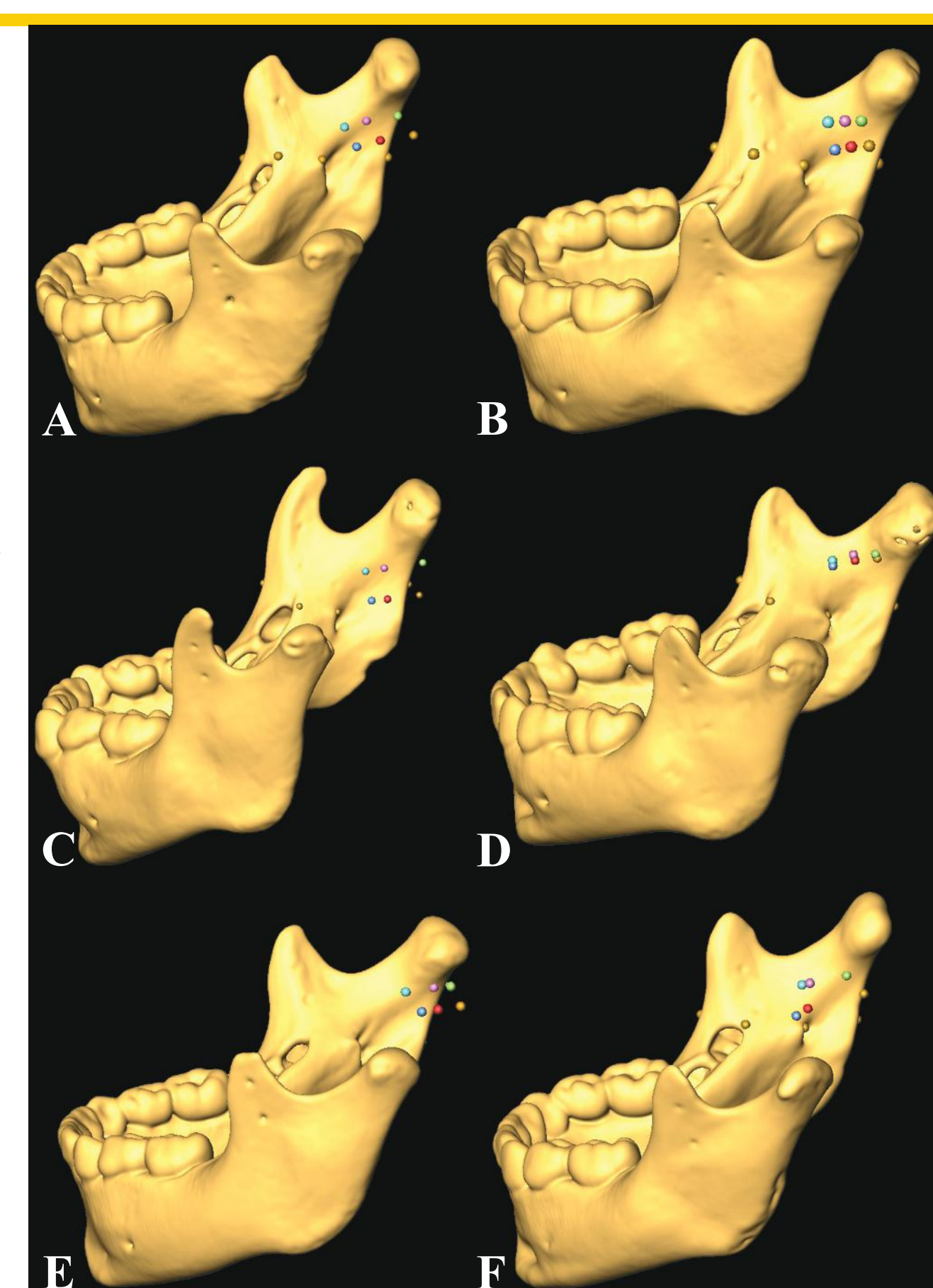
**Figure 5:** Half-mandibles for each of the five age groups. The height of the anterosuperior border of the mandibular foramen is listed for each individual in the sample for both the occlusal and the coronoid notch planes. Note that the foramen is equally divided into those above/below the occlusal plane or level with it in the youngest age group. Alternatively, in the second group the foramen is only at or above the occlusal plane in two individuals, in the remainder the foramen is below the occlusal plane. The latter pattern continues into the remaining age groups, with only 5/29 individuals having the foramen slightly above or at the occlusal plane.



**Figure 6 A-F:** Mandibles depicting variation in the positioning of landmarks with different initial tooth positions and height settings.

In each individual the canine is yellow/light green, the  $dm_1$  is red/lilac, and the  $dm_1-dm_2$  is blue/light blue.

Observe how the landmarks appear randomly spaced, even though they employ the same tooth positions. Note how an obtuse (A) or acute (F) gonial angle impacts the needle position, with the latter causing an unacceptable anteriorly positioned needle.



**Figure 7**

## Results

Consistency in mandibular positioning (glenoid cavity or articular eminence) is critical during inferior alveolar nerve blocks. Positioning on the eminence is preferable as the mandibular foramen more closely approximates the pterygomaxillary point.

The coronoid notch is the best height landmark. The occlusal plane is less desirable as it constantly results in a low injection (Fig. 5 and 7). The injector must be held level to the occlusal plane, not angled superiorly or inferiorly.

Appropriate needle positioning was achieved most often using either the center of the first deciduous molar or the interproximal region between the first/second deciduous molars (Fig. 7). When combined with a height set by the occlusal plane, proper needle positioning occurred in only 64.7% of cases. Alternatively, proper positioning was achieved in 87.2% of cases when using the coronoid notch plane to set injection height.

More specifically, combining the first deciduous molar or the interproximal region between the two deciduous molars and the occlusal plane, resulted in proper positioning in 64.7% of cases.

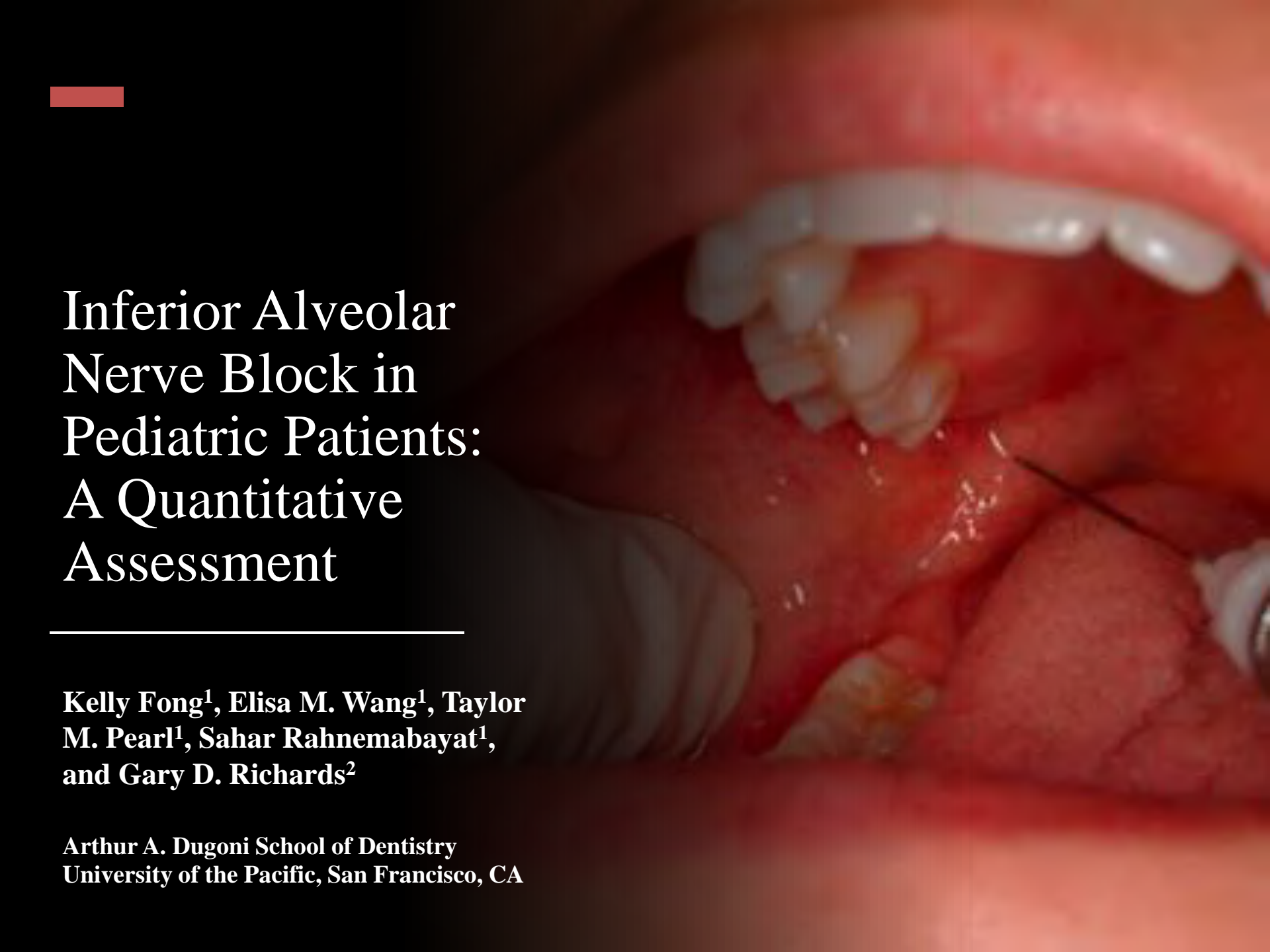
Starting the injection over the first deciduous molar and using the coronoid notch plane resulted in 80.4% of cases being properly positioned. Success rates increased by moving the injector to the interproximal region between the first/second deciduous molars, with 90.2% of the needle tips appropriately positioned.

Unacceptable needle tip placement (9.8%) appears to result more from idiosyncratic than general developmental differences (Fig. 6). We are currently expanding our analysis so as to provide pre-injection observations that should identify problematic patients and allow for corrections to be made prior to the procedure.

## Conclusions

A combination of appropriate tooth position ( $dm_1-dm_2$ ), a height set by the coronoid notch, and our pterygomaxillary landmark provides high accuracy in positioning the injection needle for inferior alveolar nerve block in children and juveniles.





Inferior Alveolar  
Nerve Block in  
Pediatric Patients:  
A Quantitative  
Assessment

---

**Kelly Fong<sup>1</sup>, Elisa M. Wang<sup>1</sup>, Taylor  
M. Pearl<sup>1</sup>, Sahar Rahnemabayat<sup>1</sup>,  
and Gary D. Richards<sup>2</sup>**

**Arthur A. Dugoni School of Dentistry  
University of the Pacific, San Francisco, CA**

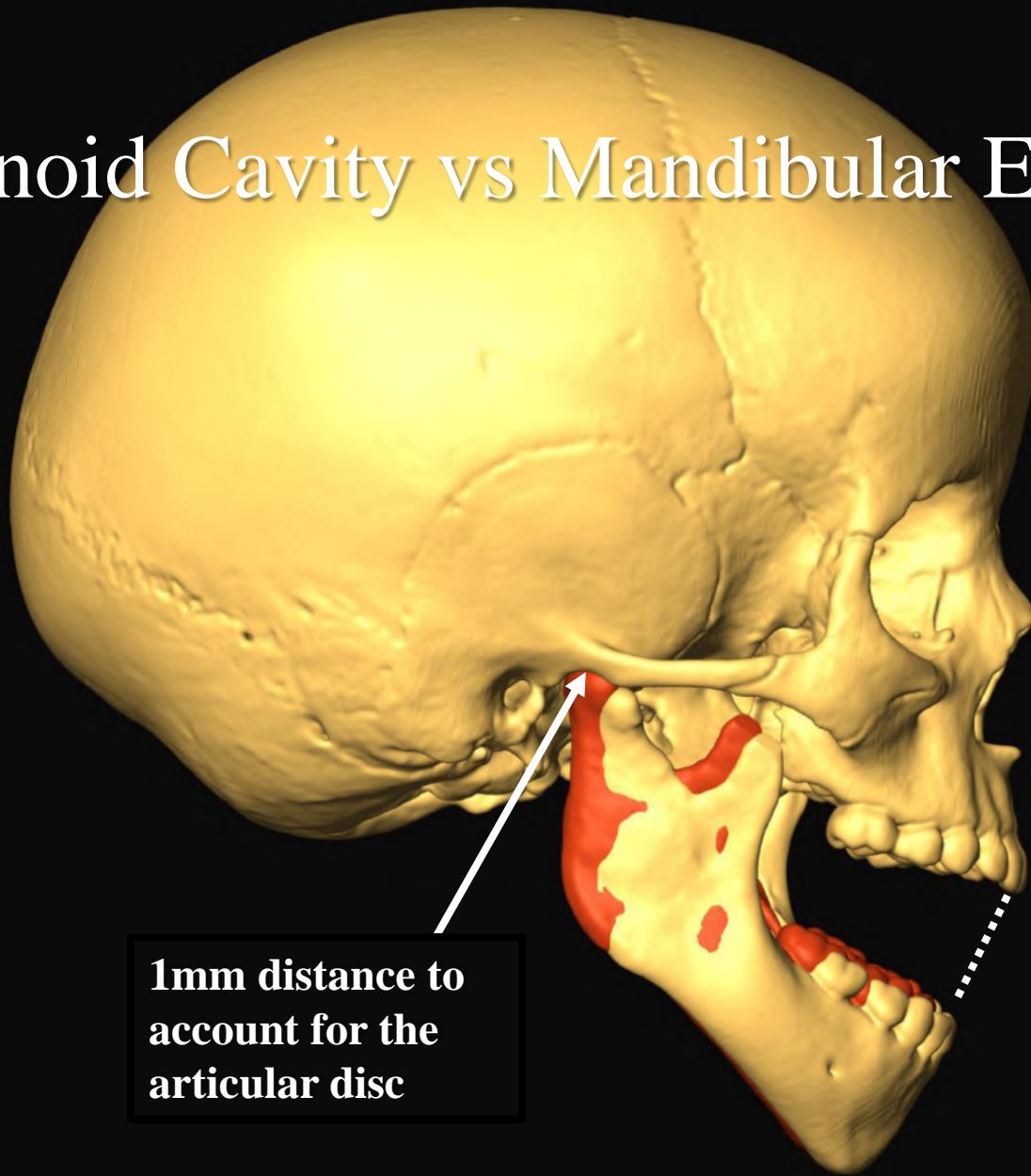
# Introduction

- Injection of anesthesia to block sensory information traveling along the inferior alveolar nerve is a topic of high interest to practicing dental professionals and dental students.
- Interest and discussion of this nerve block is driven by the wide range of reported success rates for blocking this nerve (13-98%: Goldberg et al., 2008).
- When pediatric patients are considered, there is a relatively high number of articles published that relate to blocking the inferior alveolar nerve. However, these articles generally do not focus on landmarks or the technique employed, with many providing only a brief mention of these factors. In their simplest form, a suggested technique refers only to inserting the needle above or below the occlusal plane. No injection starting points are included.
- In order to clarify inferior alveolar nerve block procedures in pediatric patients, we assessed available guide points and planes employed in this block and introduced a new landmark as well.

# Materials and Methods

- CT scanned 51 skulls and created isosurfaces using Amira
- Developmental ages were assigned by assessing the degree of crown and root calcification.
- Individual teeth were aged by comparison to the Schour and Massler (1948) dental aging chart and assigned a developmental age based on the mean of the total number of teeth available.
- Individuals were assigned to one of five age groups (2.5-3.6y, 4.0-4.8y, 5.0-5.9y, 6.0-6.9y, and 7.1-7.9y).

# Glenoid Cavity vs Mandibular Eminence



**1mm distance to  
account for the  
articular disc**

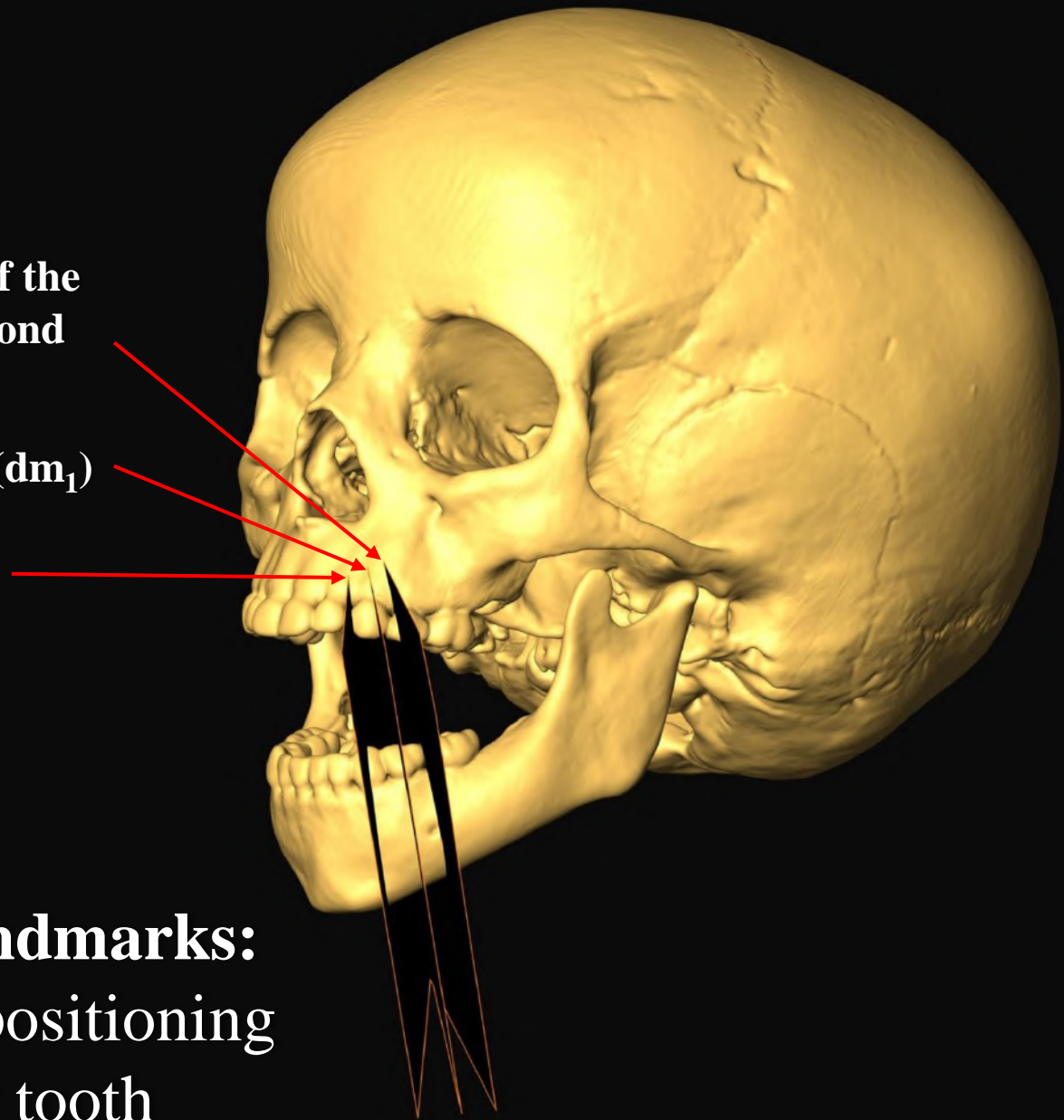
**21 mm opening**

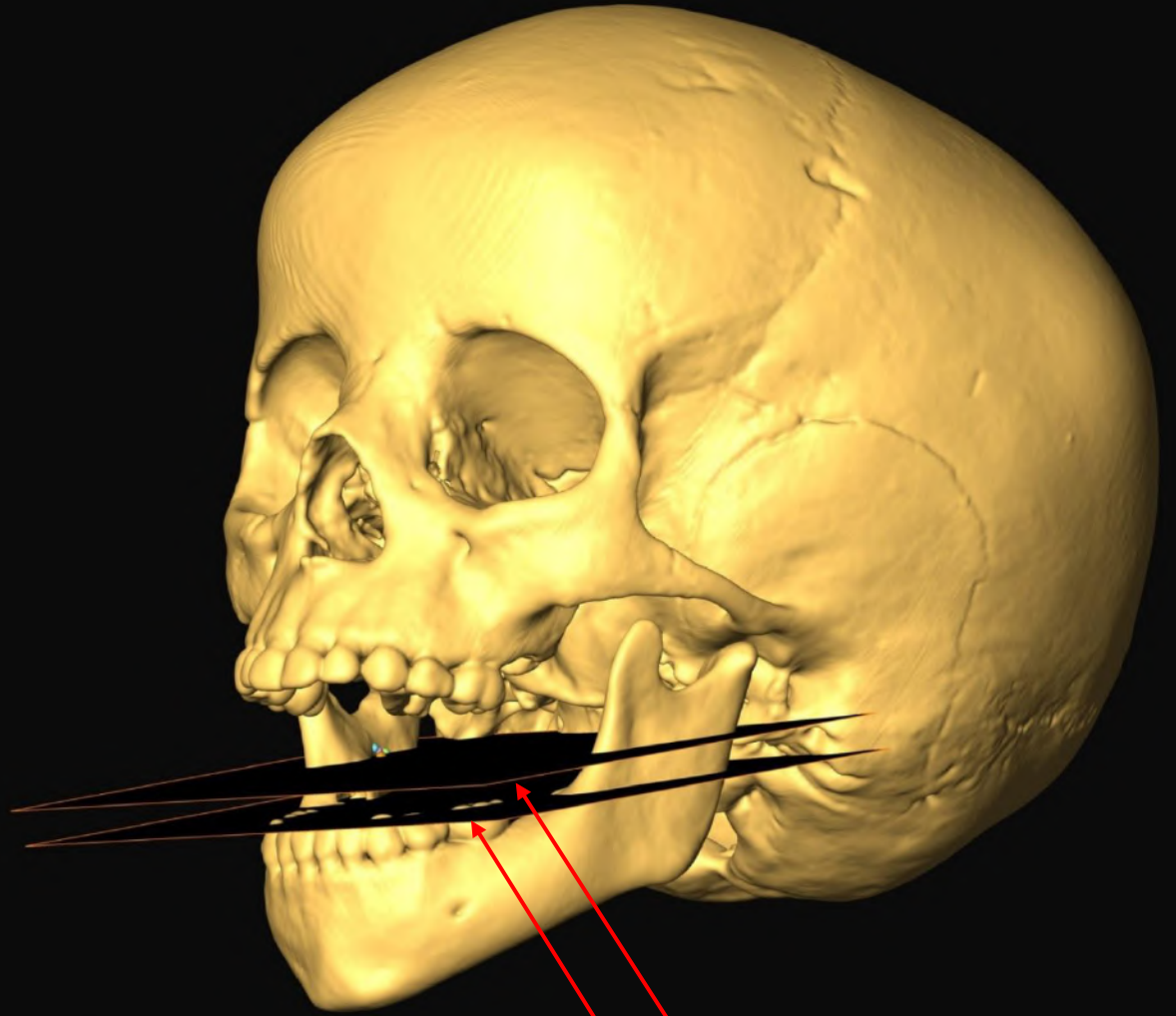
**Interproximal region of the deciduous first and second molars ( $dm_1-dm_2$ )**

**Deciduous first molar ( $dm_1$ )**

**Deciduous canine ( $d_c$ )**

**Horizontal Landmarks:  
Initial injector positioning  
over an anterior tooth**





**Coronoid Notch plane**

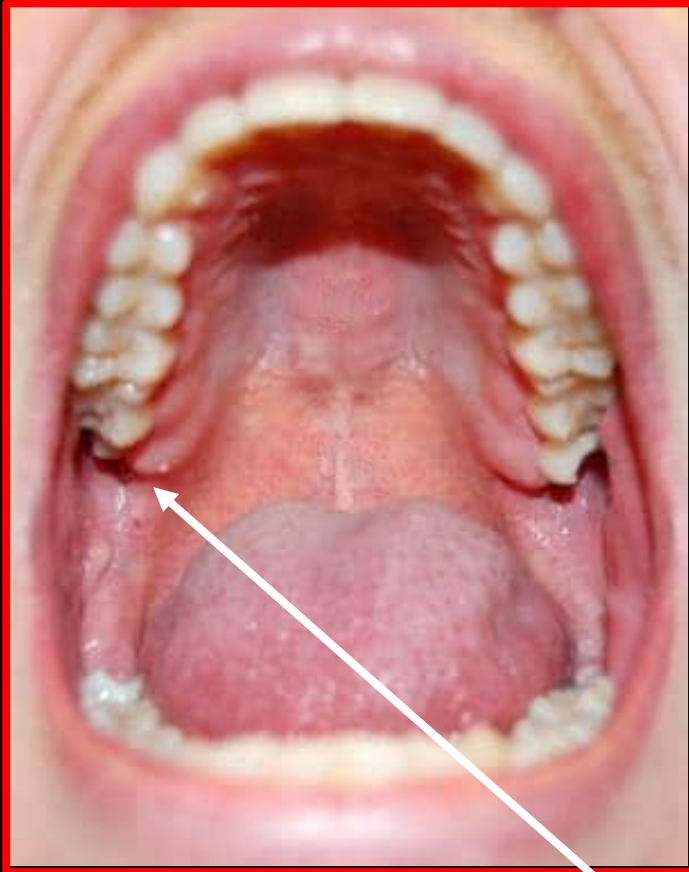
**Occlusal plane**

**Vertical Landmarks:**  
Two possible positions  
for the height of injection

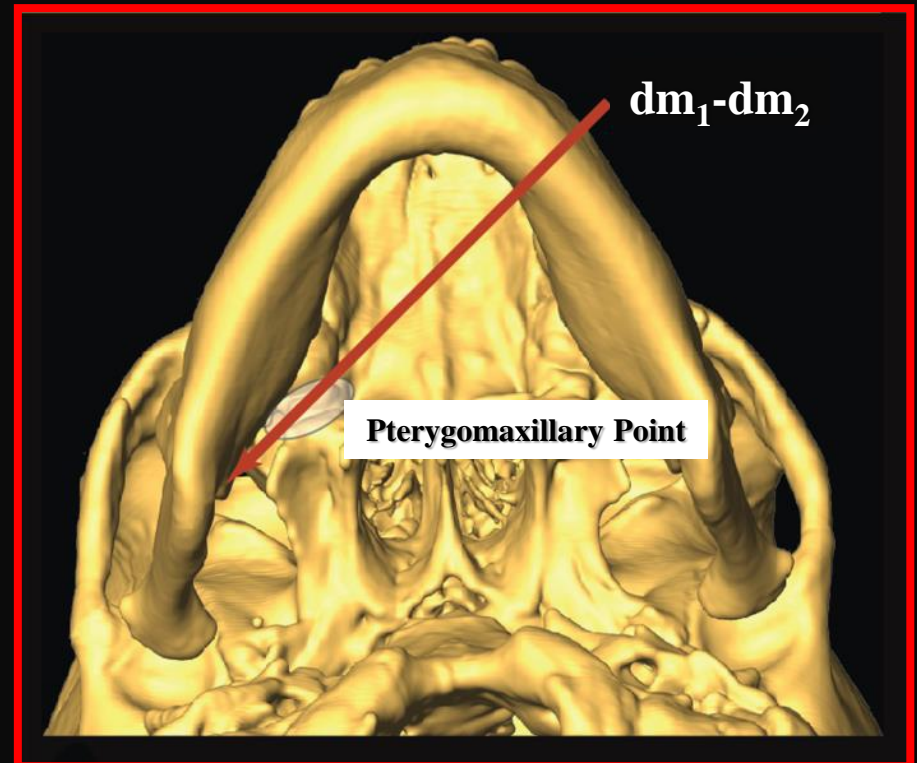


# New Pterygomaxillary Landmark

- It is visible intra-orally at the end of the maxillary alveolar ridge. (left)
- Needle trajectory from the interproximal region of the first and second deciduous molars to our new landmark. (right)

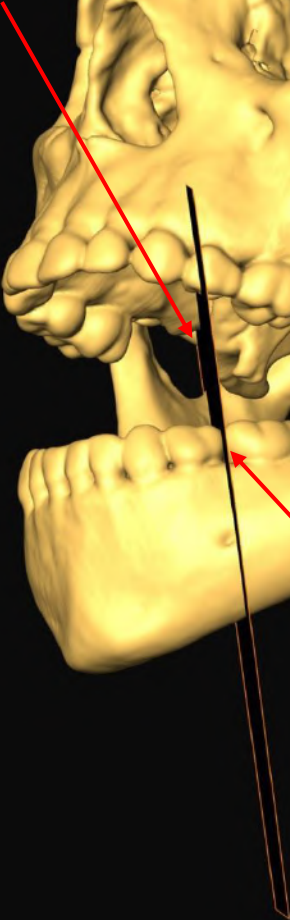


The pterygomaxillary point





**Pterygomaxillary  
point**



**dm<sub>1</sub>-dm<sub>2</sub>**

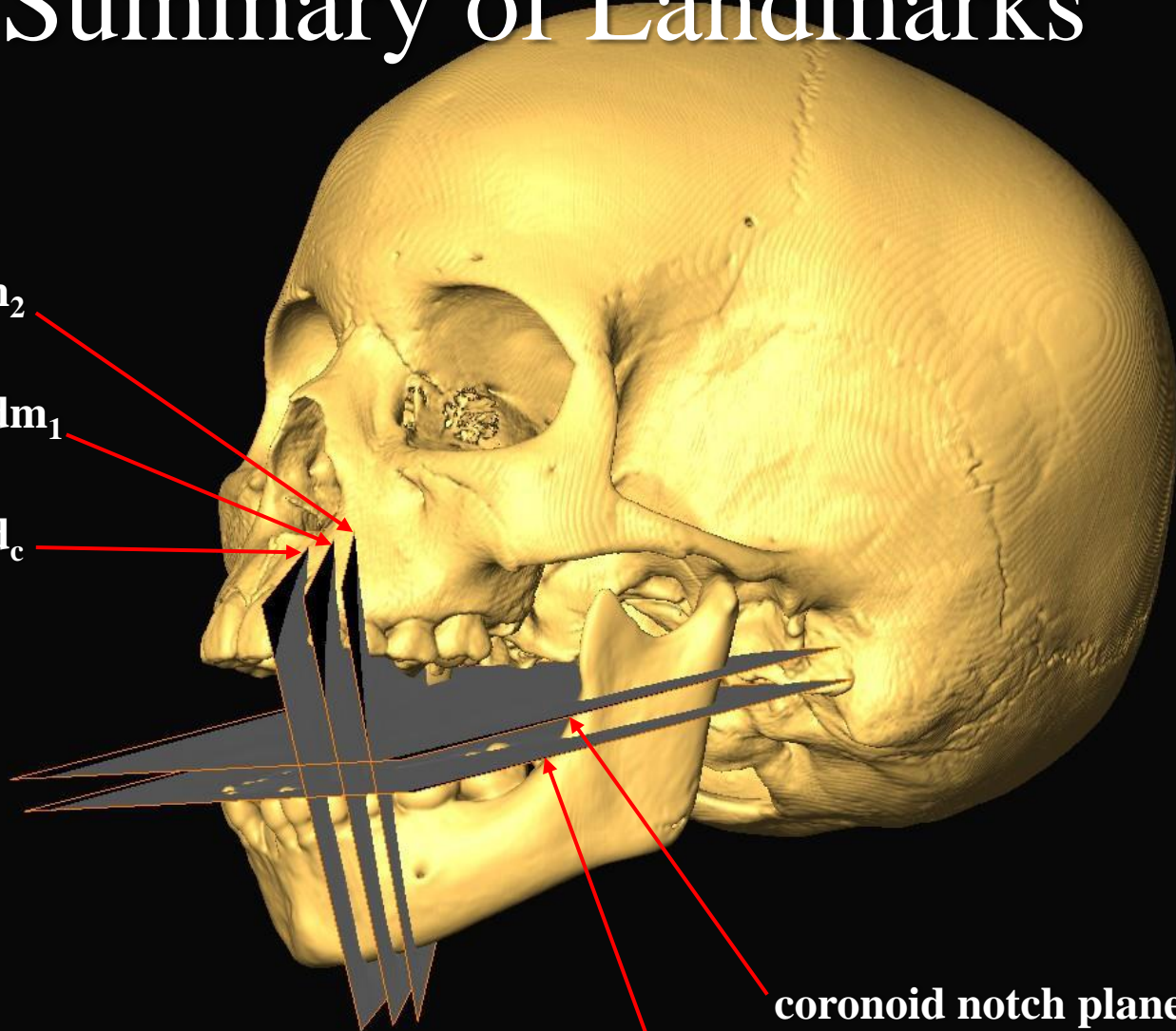


# Summary of Landmarks

$dm_1-dm_2$

center  $dm_1$

center  $d_c$

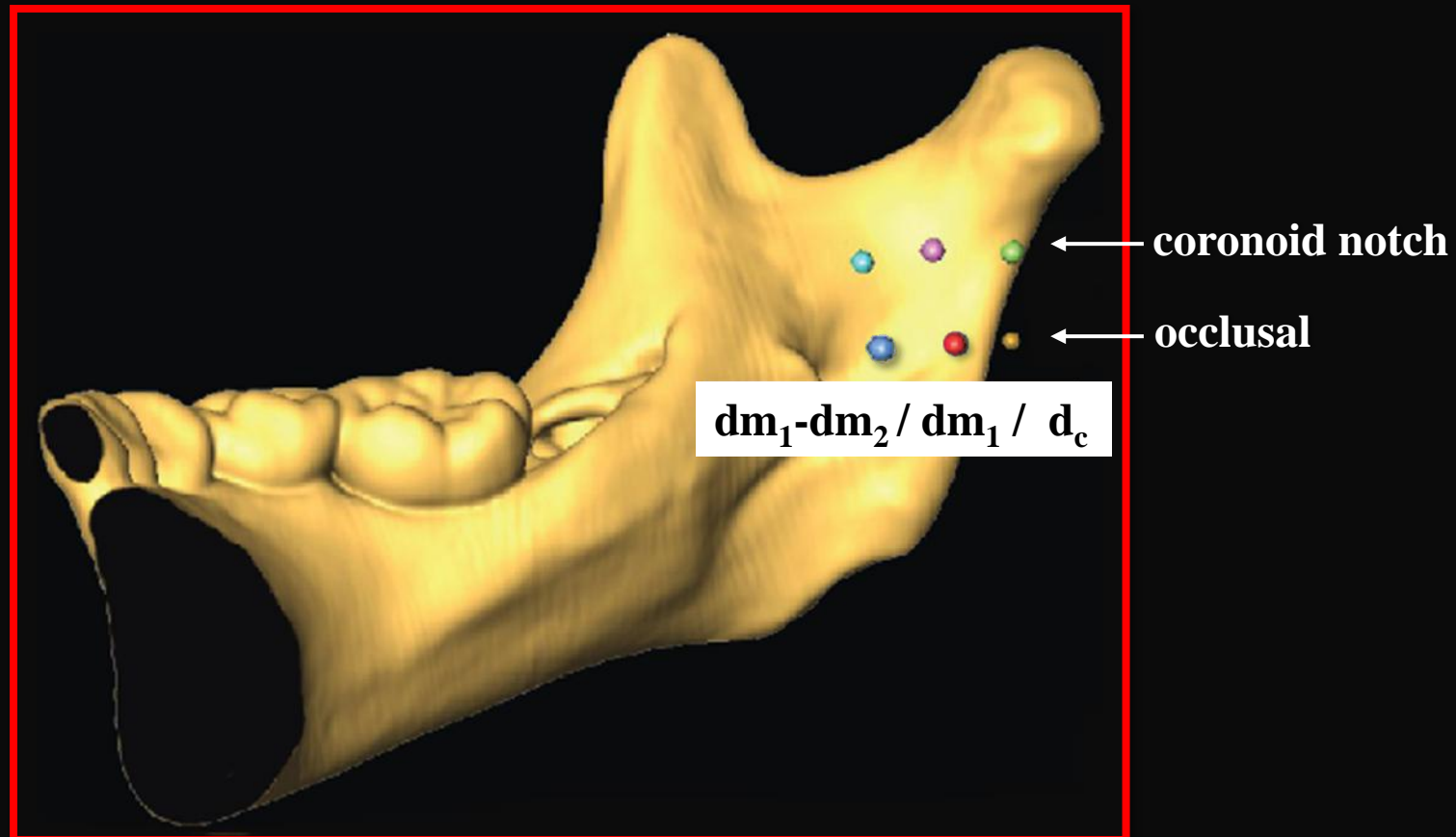


coronoid notch plane

occlusal plane



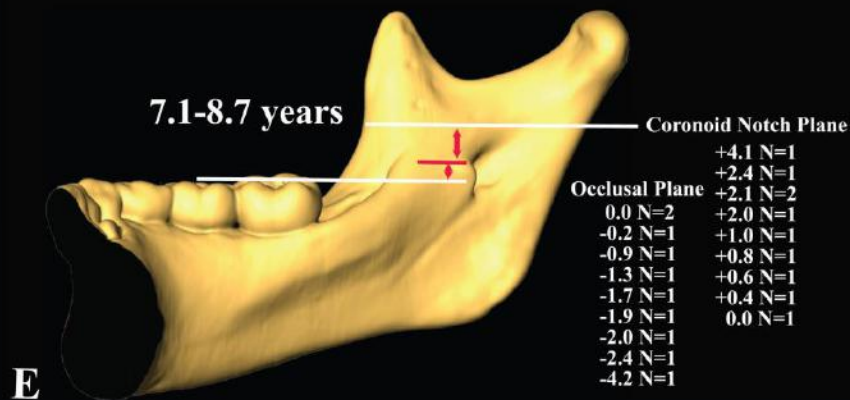
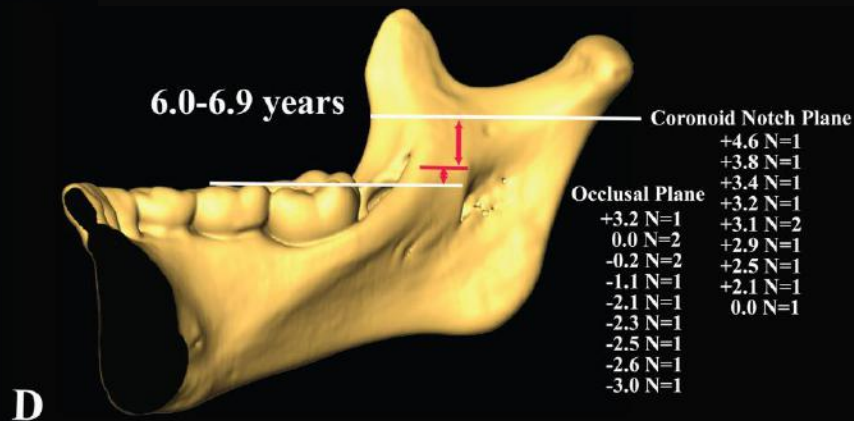
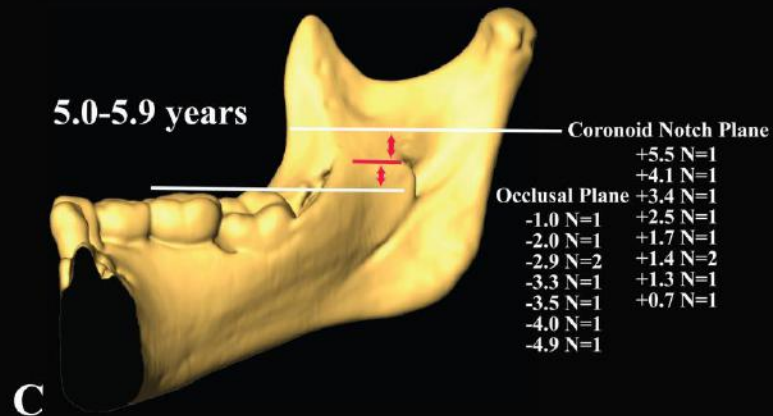
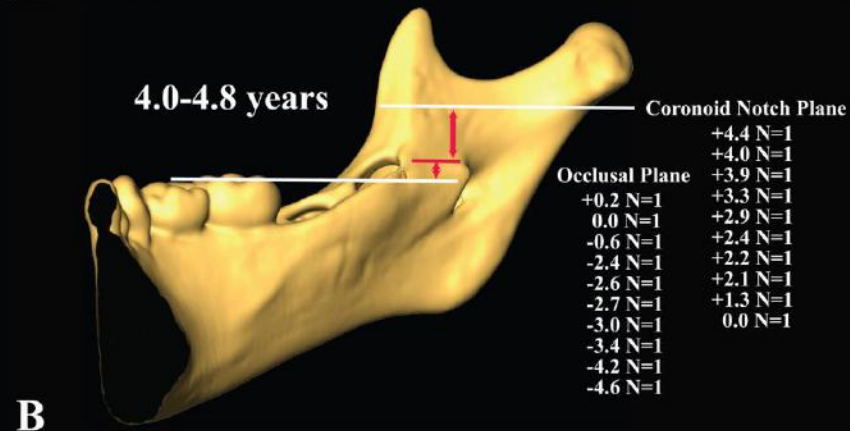
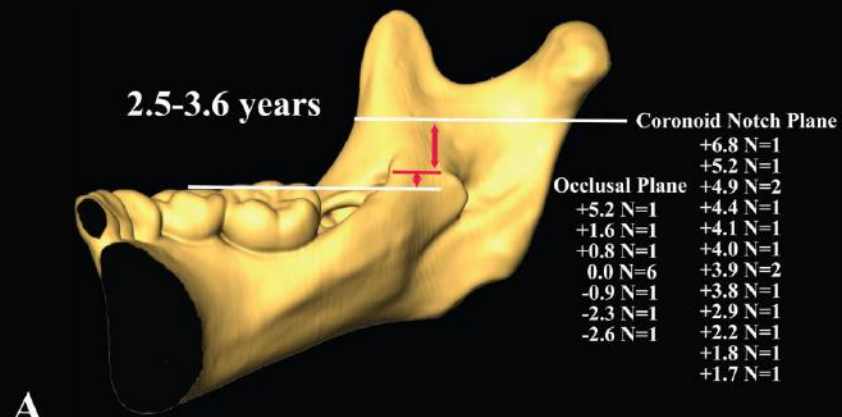
# Deposition Sites when the Coronoid Notch or Occlusal Planes are Employed with Different Starting Tooth Positions



Note the extreme posterior positioning of landmarks when employing the deciduous canine as the horizontal starting point and generally low positioning of landmarks along the occlusal plane.

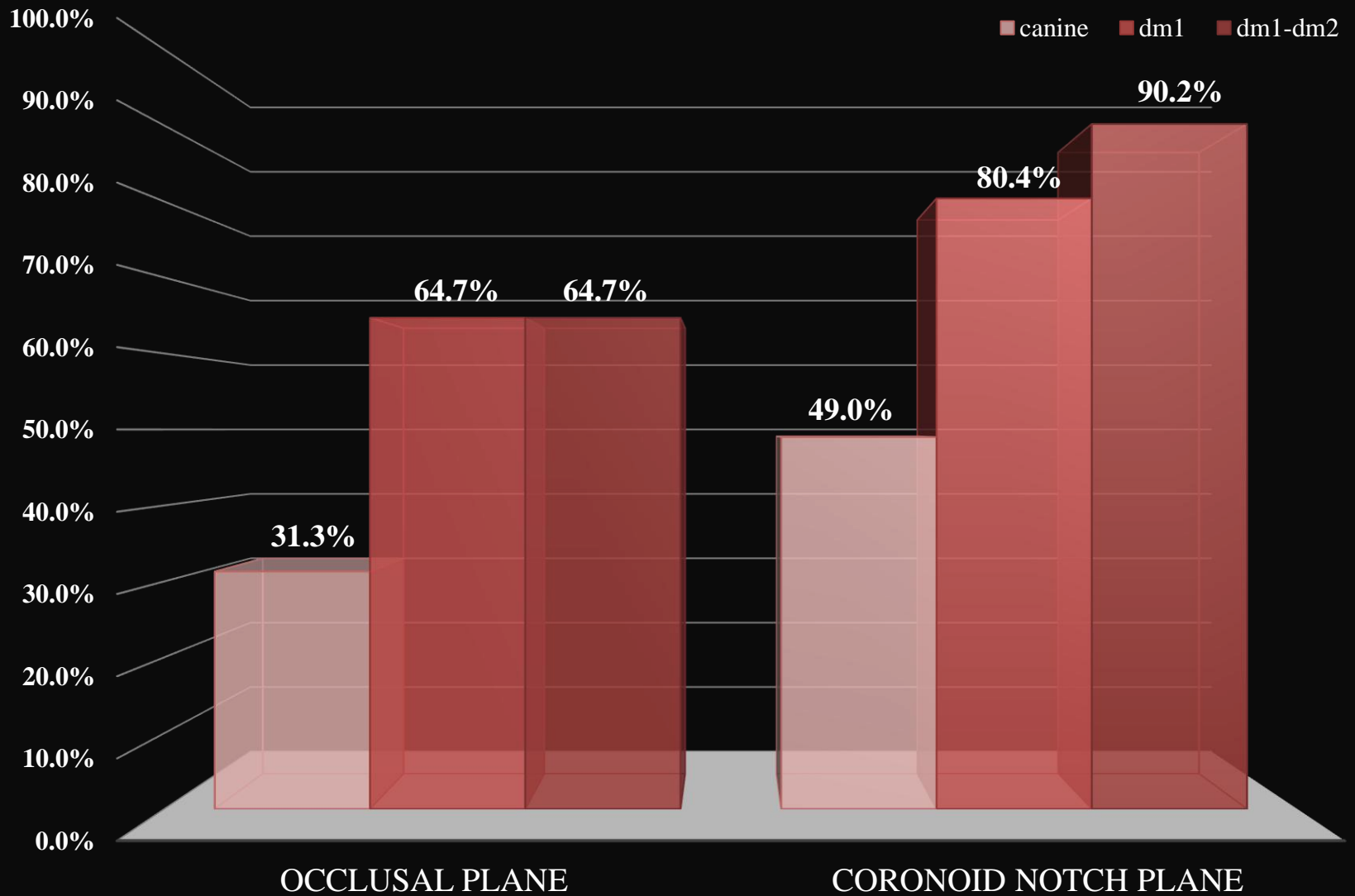


# Assessment of Proximity to Mandibular Canal



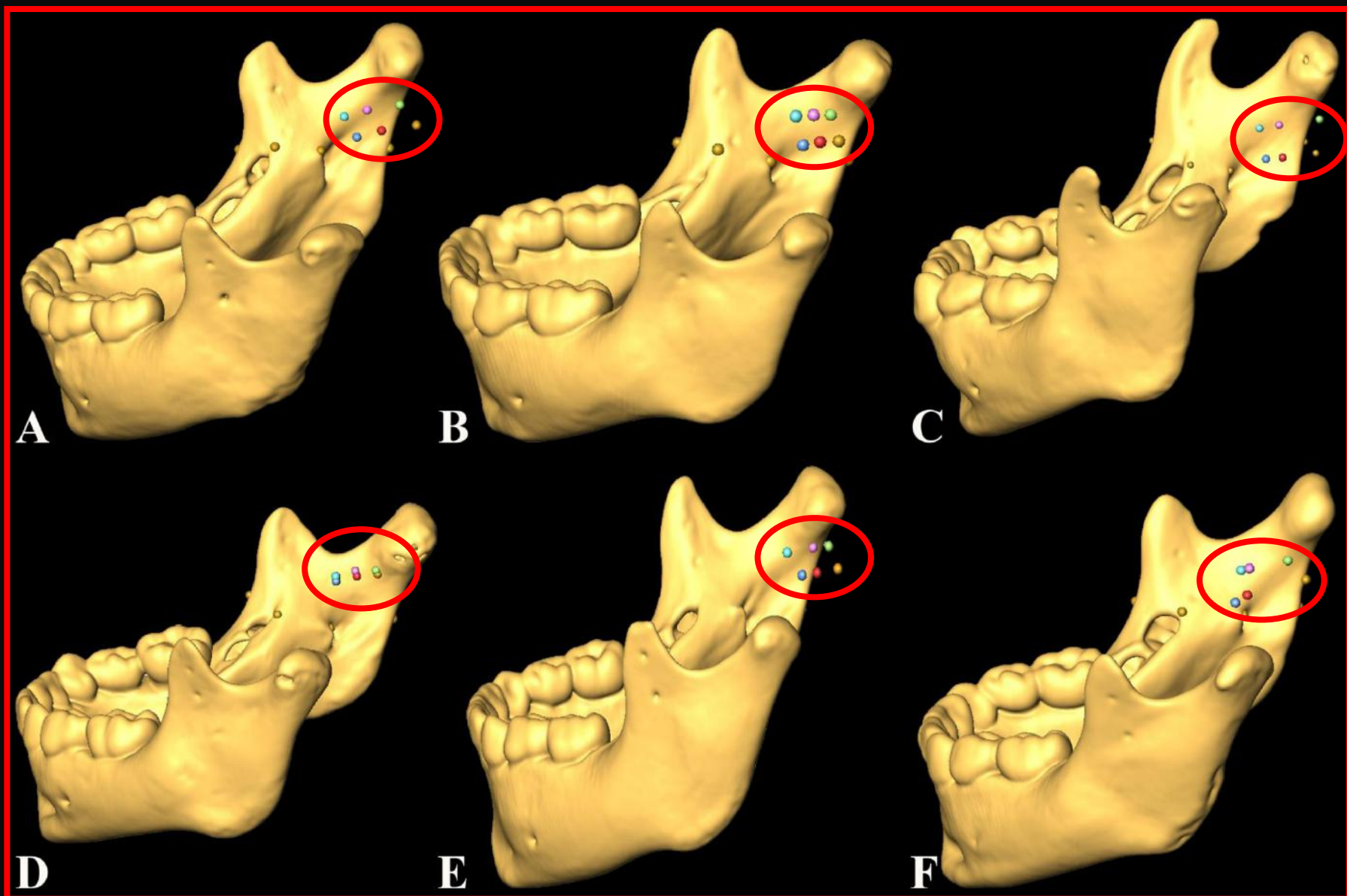


# Results





# Variation and Discussion





# Conclusion

- The **coronoid notch** is the **best height landmark**. Excluding our youngest age group, use of the occlusal plane consistently results in a **low** needle position.
- Employing the deciduous canine as a horizontal starting point nearly always results in an unfavorable **posterior** positioning of the needle tip.
- Across all age groups, the **best results** (90.2%) were obtained by starting the injection at the horizontal landmark of **the interproximal region between the first and second deciduous molars**.
- **Summary:** Combining an appropriate tooth position (**dm<sub>1</sub>-dm<sub>2</sub>**), with a height set at the **coronoid notch**, and our **new pterygomaxillary landmark** provides greater accuracy in positioning the injection needle for inferior alveolar nerve block in children and juveniles.

The Institute of  
**Dental History & Craniofacial Study**

UNIVERSITY OF THE  
**PACIFIC**

Arthur A. Dugoni  
School of Dentistry



*California Pacific  
Medical Center*

A Sutter Health Affiliate

**Acknowledgements**

Conflicts of interest: None