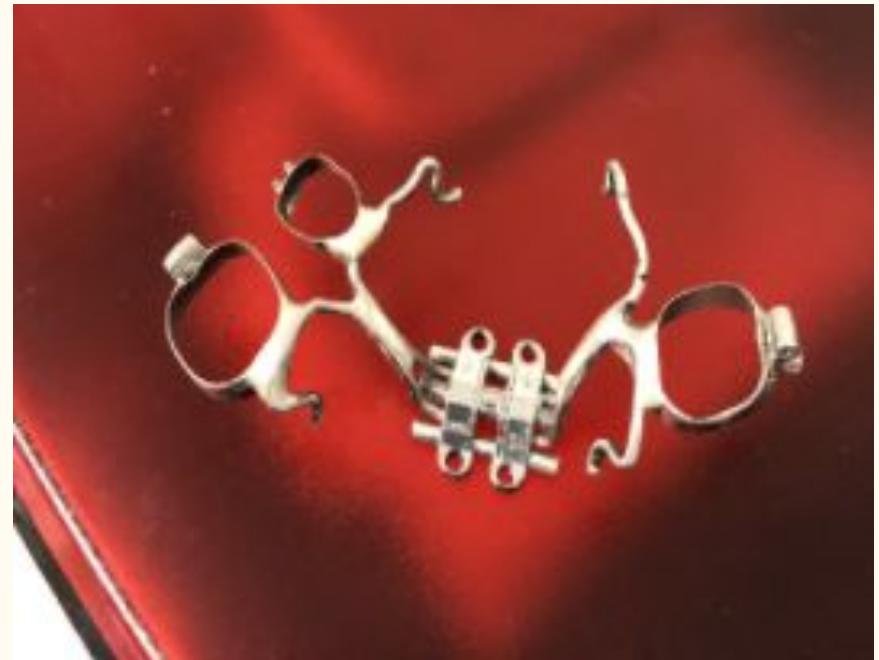

Assessment of Short and Long-term changes of the Hard and Soft Tissue of the Face with Miniscrew-Assisted Rapid Maxillary Palatal Expanders


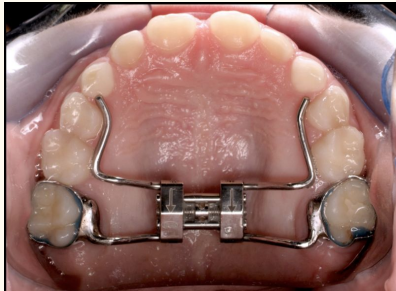
Laura Chew, DDS, Ortho Resident 2021
Naomi Low, DDS 2022
Steven Leung, DDS 2022

Miniscrew-assisted rapid palatal expander (MARPE)

- A palatal expansion appliance consisting of a conventional hyrax expander supported by orthodontic mini screws
- Intervention on the midpalatal suture by separating maxillary bones with rapid palatal expansion technique
- By activating the screws, forces are applied to separate the maxillary bone so that new bone can form
- Indications for the use of MARPE include a range of issues such as hindered facial development, crowded teeth, and nasal obstruction



MARPE vs Rapid Palate Expander

	MARPE	Rapid Palatal Expander
Purpose	Expansion through mid-palatine suture	
Population	Adult patient population	Ongoing skeletal growth
Expansion pattern	Parallel expansion Hard tissue expansion	Triangular expansion Hard and soft tissue expansion
Image		

Specific Aims

- Evaluate the amount of skeletal expansion, molar tipping, and overlying soft tissue change from using MARPEs at the end of orthodontic treatment in comparison to initial CBCT and post expansion CBCT in adult patients
 - Adult patient = patient with a Cervical Vertebral Maturation (CVM) score of 5 or 6 indicating no growth
- To evaluate the amount of dental, skeletal, and soft tissue relapse that occurs at the time of orthodontic treatment completion using CBCT
 - H_0 = no change dentally, skeletally, or in the soft tissue occurs between the time of finishing expansion and at the end of orthodontic treatment based on the patient's CBCT

Materials and Methods

- 17 patients who had received successful expansion with a microimplant-assisted rapid palatal expander (MARPE)
 - Mean age at treatment start: 15.8 yr
 - All patients were at cervical stage 5 or 6 and had passed the growth peak at least 1 year before starting treatment
- CBCT was taken at pre-treatment (T_1), after expansion was completed (T_2), and treatment completion (T_3)
- 3-D analysis configuration was created to trace hard and soft tissue landmarks of the midface and nasal cavity regions in InVivo
- Repeated measures ANOVA test was used for statistical comparison across three time points
- Pairwise paired t-tests with Bonferroni correction was used for pairwise comparison.

category		n	%
Sex	Male	6	35.29
	Female	11	64.71
CVM	CS 5	10	58.82
	CS 6	7	41.18
Age	mean		
	Age at T1	15.75	
	Age at T2	16.55	
	Age at T3	18	

Table 1. Sample Characteristics

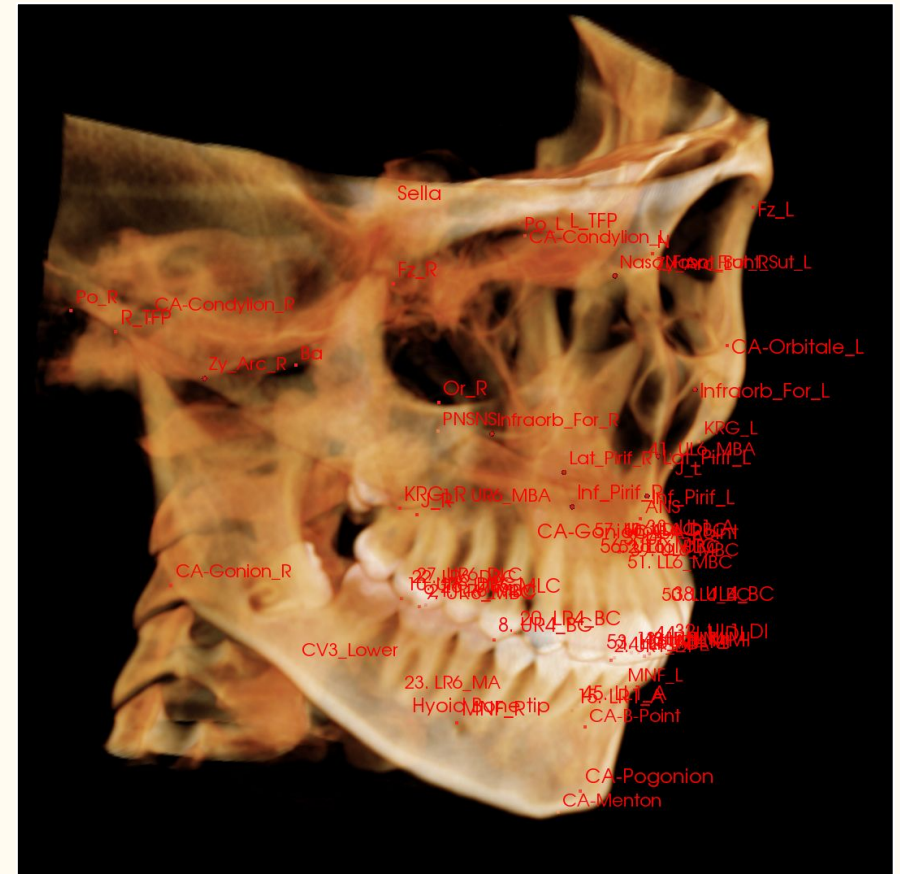
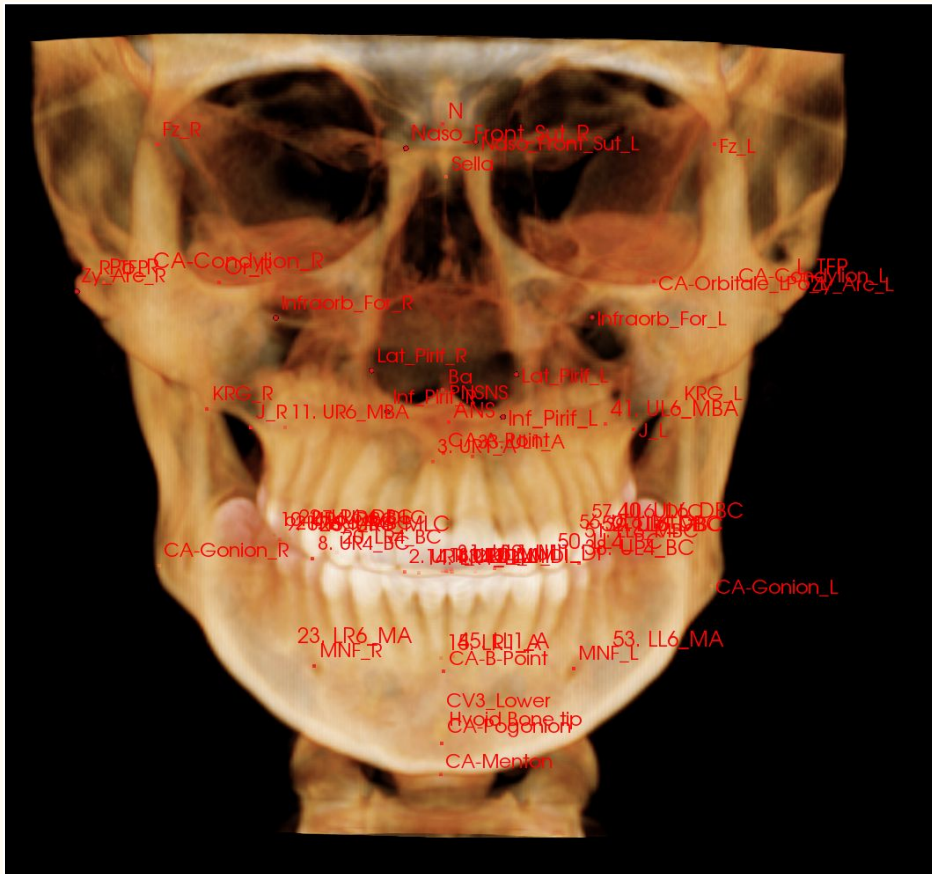
What was measured

18 hard and 10 soft tissue landmarks




- PORION
- FRONTOZYGOMATIC SUTURE
- NASOFRONTAL SUTURE
- KEY RIDGE
- ANC LATERAL PIRIFORM
- ANC INFERIOR TURBINATE
- ANC INFERIOR PIRIFORM
- PNC SUPERIOR TURBINATE
- PNC INFERIOR TURBINATE
- PNC NASAL FLOOR
- JUGUM
- ANS
- PNS
- A POINT
- U6 MB CUSP
- U6 APEX
- U1 MESIAL INCISAL
- U1 APEX
- ENDOCANTHION
- EXOCANTHION
- SOFT TISSUE NASION
- ALA
- ALA-CHEEK (AC)
- PRONASALE
- SUBNASALE
- SUBALARE
- CHELION
- PHILTRUM

Landmark identification



Tracing Realtime



Results

- Increases in skeletal width from the ANS down to the maxillary alveolar bone were statistically significant in short term (T1-T2) and long term (T1-T3)
- The nasal cavity width at inferior turbinate area increased significantly after expansion (T2) and remained increased at treatment completion (T3)
- Soft tissue changes showed that the increased width of the nose after expansion therapy reduced to the initial width at treatment completion

Table 2. Skeletal width at pre-treatment (T_1), after expansion (T_2), treatment completion (T_3)

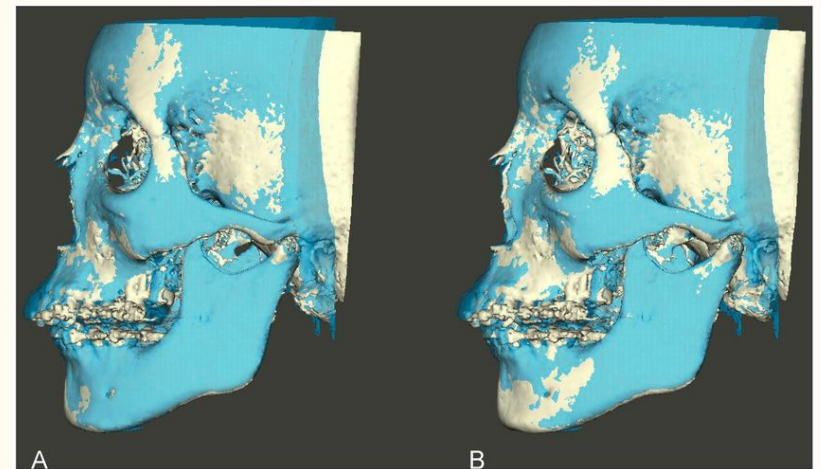
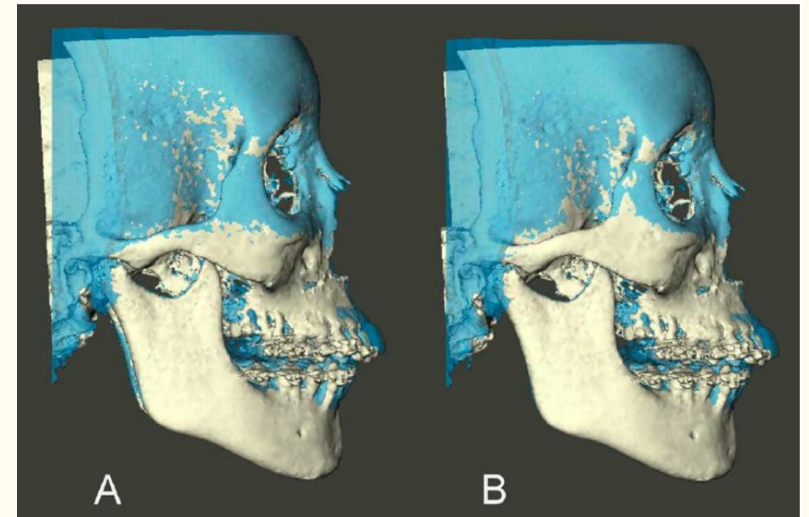
	T1	T2	T3	p-value
	93.95±4.3			
UOP_Fz-Fz	8	94.9±4.45	94.91±7.09	0.568
		10.92±3.3		
UOP_NaFrSu-NaFrSu	9.49±2.54	8	11.44±3.73	0.162
UOP_KRG-KRG	88.02±5.3	90.5±6.45	90.92±6.34	0.255
		70.05±5.1		
UOP_Ju-Ju	66±3.8	9	68.42±4.09	<.0001
UOP_ANS_Di	0.00	5.24±2.82	5.27±2.22	<.0001
UOP_PNS_Di	0.00	4.94±2.35	8.74±5.92	<.0001
UOP_A point	0.00	5.22±2.62	4.27±1.72	<.0001
	50.64±4.5	57.23±3.5	57.89±11.2	
UOP_U6 MB CUSP	4	9	6	0.008
	50.52±3.7	54.67±4.9		
UOP_U6 APEX	7	1	54.15±4	<.0001
UOP_U1 MI	1.93±0.86	2.21±1.12	2.22±1.5	0.71
UOP_U1 APEX	5.58±1.43	8.21±2.57	6.18±2.05	0.0004

Table 3. Nasal cavity width with soft tissue measurements at pre-treatment (T_1), after expansion (T_2), treatment completion (T_3)

	T1	T2	T3	p-value
UOP_Lat_Pirif-Lat_Pirif	19.5±1.95	22.24±2.93	21.72±2.95	0.002
UOP_Inf_Pirif-Inf_Pirif	11.74±3.89	13.51±3.73	14.35±4.44	0.184
en-Na'-en	127.7±20.49	121.84±17.76	122.09±31.53	0.612
al-al	35.7±3.32	36.19±3.82	36.07±3.19	0.602
ac-ac	31.15±4.16	31.96±3.89	30.87±7.9	0.778
al-PrN-al	97.21±10.25	102.32±20.71	99.27±11.56	0.346
ac-PrN-ac	74.2±11.8	77.36±10.42	74.22±19.18	0.567
al-Na'-al	45.29±5.91	44.45±6.48	44.1±6.09	0.698
Chelion width	46.01±4.47	47.48±6	48.46±4.37	0.103
Philtrum width	11.09±2.89	11.38±2.98	11.86±3.36	0.463
ANC IT-IT	20.28±1.92	23.11±3.43	24.14±2.65	<.0001
PNC IT-IT	25.31±1.35	27.02±2.13	26.86±1.08	0.001
PNC ST-ST	22.06±2.56	21.73±5.29	22.25±2.99	0.879
PNC NF-NF	25.42±3.9	28.06±3.79	26.93±3.9	0.087

Conclusion

- Maxillary expansion with MARPEs resulted in skeletal changes throughout the maxilla
- Long-term increase in nasal cavity width achieved
- Soft tissue changes were seen after T2 phase, however they were diminished after patients completed their orthodontic treatment
- Expanded soft tissue relapse can provide relief for patients in fear of facial deformation



Final Considerations and Future Interests

- Study design changes that can further improve our results
 - Bigger sample population
 - Standardization of orthodontic treatment provided and duration
 - Classification of adult skeletal maturation has inconsistencies when basing of cervical vertebral maturation score
- Further uses of MARPES in various dental treatments
 - Changes in airflow in upper airways
 - Decreasing nasal resistance
 - Treatment for obstructive sleep apnea syndrome

Acknowledgements

We would like to thank Dr. Park and Dr. Oh for their guidance during this project

We would also like to thank:

- Daniel Nguyen, DDS 2022
- Nicole Vega-Valbuena, DDS 2022
- Luke Wu, DDS 2022
- Hanisha Pasupulate

For their contributions for tracings